

You can run, but you can't hide

- A bitemark analysis

SADJ April 2021, Vol. 76 No. 3 p138 - p141

L Robinson¹, H Bernitz²

CASE REPORT

All names and places have been changed to protect innocent victims in this case report.

A young woman was returning home after work when she was accosted by a man wielding a knife. She was dragged into a nearby bush where the suspect attempted to rape her. She put up a substantial fight and was able to flee the scene. She went directly to the nearest police station to report the case. She was asked by the police to accompany them in the hope that she might recognise the suspect at the local taxi rank, which was near the scene of the crime. She did in fact recognise the suspect who was duly arrested. He denied any knowledge of the crime for which he was being apprehended.

The victim informed the police that she had remembered biting the suspect on his right shoulder during the attack and ensuing struggle. The suspect was asked to roll up his right sleeve where a possible bitemark wound was observed. The suspect was taken into custody for further investigations.

Fortunately, the police officer in charge of the case had attended a lecture on bitemarks given by the second author some weeks before the incident and was therefore well-versed in the protocol for the collection of evidence in a bitemark case. The officer arranged that photographs and impressions of the possible bitemark were taken for forensic analysis. Unfortunately, swabs of the bitemark were not conducted, therefore DNA and ABO blood group antigen analysis could not be performed. Impressions of the victim's dentition were also taken from which plaster models were constructed.

All dental materials used in this case were mixed according to the manufacturer's instructions and were within their expiry dates.

This evidence was submitted to the forensic odontology unit at the University of Pretoria for examination and comparative analysis.

ANALYSIS OF THE BITEMARK

The following evidence was received:

1. A CD containing photographs taken of the bitemark on the right upper arm of the suspect (Figure 1).
2. Two silicone impressions of the bitemark (plaster models were subsequently constructed) (Figures 2-3).
3. Two models of the victim's dentition, one of the maxillary teeth and one of the mandibular teeth (Figure 4).

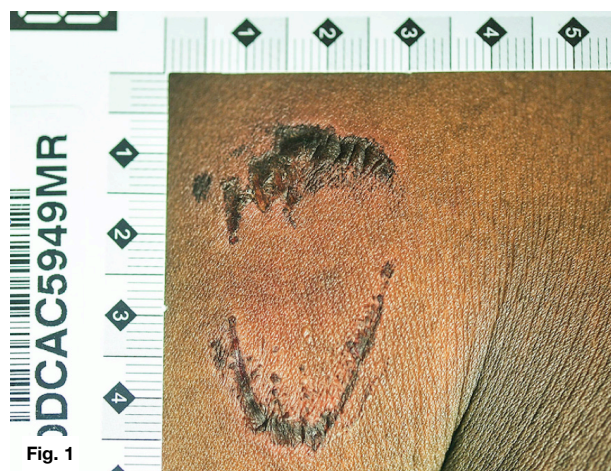

Fig. 1

Figure 1. Photograph of the bitemark on the right upper arm of the suspect.

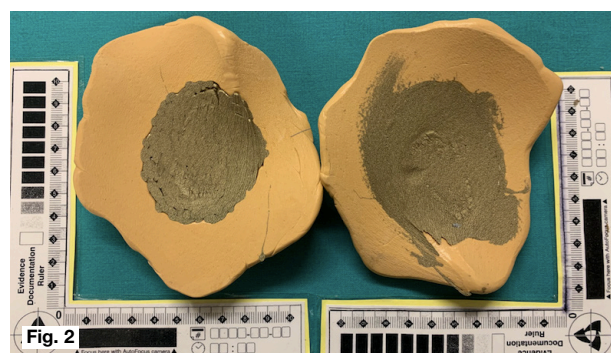


Fig. 2

Figure 2. Two silicone impressions of the bitemark.

Author affiliations:

1. **Liam Robinson:** BChD, PDD (Maxillofacial Radiology), PDD (Forensic Odontology), Department of Oral Pathology and Oral Biology, School of Dentistry, Faculty of Health Sciences, University of Pretoria.
ORCID Number: 0000-0002-0549-7824
2. **Herman Bernitz:** BChD, Dip (Odont), MSc, PhD, Department of Oral Pathology and Oral Biology, School of Dentistry, Faculty of Health Sciences, University of Pretoria.
ORCID Number: 0000-0003-1361-1225

Corresponding author: Herman Bernitz

Department of Oral Pathology and Oral Biology, University of Pretoria, South Africa.

Email: bernitz@iafrica.com

Author contributions:

1. **Liam Robinson:** Primary author - 50%
2. **Herman Bernitz:** Secondary author - 50%

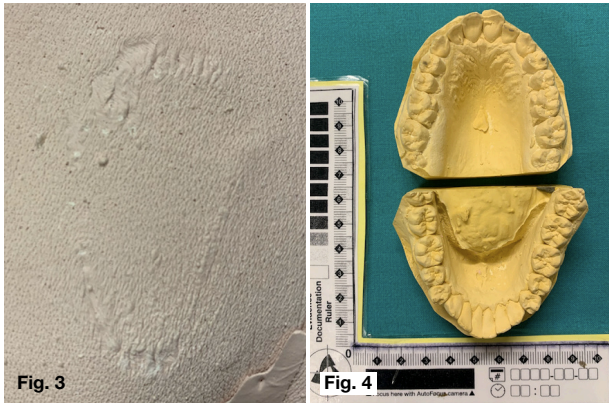


Figure 3. Cast model of the bitemark.

Figure 4. Maxillary and mandibular models of the victim's dentition.

The examination was performed by comparing the models of the victim's dentition with the clinical photographs and models of the bitemark present on the upper arm of the suspect. An additional pattern association comparison was performed by contrasting the bitemark on the upper arm of the suspect with simulated bitemarks obtained using the victim's dental models to bite into plasticine blocks (Figure 5). Both a macroscopic and microscopic analysis was performed in this case, according to international best practice.



Figure 5. Simulated bitemark using the victim's maxillary dental model.

The marks present on the upper arm of the suspect were consistent with those of a human bitemark.

- The approximate widths of the maxillary teeth were within the normal range (Mean width central incisor = 8.6 mm and lateral incisor = 6.6 mm).¹
- The shapes of the teeth within the arch were consistent with that of a human bitemark (central incisors wider than lateral incisors).
- The mandibular intercanine distance was within the normal range of a human bitemark.² The maxillary intercanine was not measured as both canines were not apparent in the bitemark.

It is important to emphasise the following points when analysing bitemarks:

1. Warping, shrinkage and distortion make exact measurements of teeth impossible, and that these measurements are used purely as a quality control measure.

2. Minimal amounts of warping and shrinkage will not affect the pattern association analysis of bitemarks.³
3. When comparing measurements/patterns of a suspect's dentition with bitemarks present on the skin of the victim, an exact match will never be found³

Macroscopic examination of the victim's dental models and the models and photographs of the bitemark on the upper arm of the suspect showed several points of concordance, but lacked any unique recognisable dental features:

- i. All mandibular anterior teeth, and teeth 11, 21, 22 and 23 were present in both the victim's dentition and in the bitemark observed on the upper arm of the suspect.
- ii. Tooth 21 was labially positioned in relation to tooth 11 in both the victim's dentition and in the bitemark observed on the upper arm of the suspect.
- iii. In the victim's dentition, tooth 21 was longer than tooth 22. This was also apparent in the bitemark observed on the upper arm of the suspect. This gave the impression of a step, rather than an even arch contour.
- iv. The third quadrant of the bitemark showed a labially positioned tooth, which was also present in the mandibular arch of the victim's dentition.
- v. The mandibular arch of both the bitemark observed on the upper arm of the suspect and the victim's dentition showed a similar arch shape.

Based on the macroscopic analysis alone, the following conclusions were made:

1. The victim cannot be excluded as the possible biter.
2. The pattern of the upper and lower bitemarks showed concordance with the pattern of the victim's dentition, but the lack of any unique recognisable dental feature makes any degree of individualisation unreliable.

All evidence was then transferred to the Silverton Forensic Laboratory (Pretoria, South Africa) where a microscopic analysis of the bitemark was performed. A Leica DMC comparison microscope (typically used for examination of fired bullets and other forensic evidence) was used to compare the models of the bitemark and the suspect's dentition. The microscopic comparison showed individualising features, and a conclusion of "high degree of certainty" was given.

In a court of law, the macroscopic and microscopic analysis of the bitemark is presented independently. As previously emphasised, international agreement stipulates that no skin bitemark conclusions are ever given with absolute certainty.

DISCUSSION

A bitemark represents a pattern of injury or marking produced by teeth during the biting process. Bitemarks can be present on inanimate objects found at the scene of the crime such as foodstuffs (for example cheese, chocolate or an apple), or on human skin. Bites can be inflicted by humans or animals, be self-inflicted, or inflicted by the victim on the perpetrator and/or vice versa.⁴ Bitemark collection and analysis is a dynamic field of forensic odontology in which techniques, protocols and quality control measures are continuously evolving. The analysis of bitemarks is fundamentally a macroscopic and microscopic pattern association science. This involves a comparison of the patterns of teeth in the dental arch of the biter with the substance bitten, and includes:

- Gross characteristics, which determine whether or not the bite was inflicted by a human.
- Individual characteristics, including the size of teeth, rotated teeth or diastemas.
- Accidental characteristics, such as chips and imperfections caused by attrition, abrasion and trauma.⁴

Bitemark analysis methods and techniques include direct macroscopic and microscopic comparative analysis, various overlay techniques, computer-generated comparisons and 3D computer-assisted programs.⁴ Individual cases in which highly scientific methods such as tissue micro-replication followed by scanning electron microscopy for determination of concordance between a suspect's dentition and a victim's bitemark have also been described.⁵ Currently, acetate overlays and computer-generated comparisons are regarded as the most objective methods of bitemark analysis.³ The author's belief that concurrent macroscopic and microscopic analysis is the most accurate and feasible technique for bitemark comparisons. Scratch or sledge marks created by the dentition in the bitten object can be accurately matched to chips and nicks present on the suspect's dentition using a DMC comparison microscope.⁵

It is important to emphasise that several parameters have a significant effect on bitemark analysis. These include the quality of patterns in the bitemark, the type and quantity of material available for analysis and the presence of recognisable dental features. The considerable variation of bitemark presentations on human skin brings its accuracy as a registration material into question. Skin is highly variable in terms of anatomical location, underlying musculature or fat, curvature and looseness or adherence to underlying structures. Also, skin is a highly visco-elastic substrate, which allows stretching and distortion to occur during the biting process or subsequently when evidence is collected.⁶ Irrespective of the techniques used, the degree of warping, shrinkage and distortion in bitemark patterns remains one of the biggest stumbling blocks during analysis.⁷⁻⁸ A study by Bernitz has shown that a small degree of warping or shrinkage will not affect the pattern-associated analysis of the bitemark.³ This finding was subsequently reinforced using affine transformations to mathematically prove that minor deformations do not affect the ability to show positive concordance between the suspect's dentition and the bitemark.⁷

It is the authors' opinion that a conclusion of "absolute certainty" should never be given in skin bitemark cases. This statement would be virtually indefensible on cross-examination. Pretty and Sweet use the term "highest level of forensic significance" which does not imply absolute certainty.^{6,9} In contrast, bitemarks present on inanimate objects can be matched with absolute certainty.³

The exact methodology when dealing with a skin bitemark is beyond the scope of this article. For a detailed synopsis, refer to the following article: Bernitz H, Owen JH, van Heerden WFP, Solheim T. An integrated technique for the analysis of skin bite marks. *J Forensic Sci.* 2008; 53(1): 194-8.

The debate regarding the uniqueness of human teeth is probably one of the fiercest in forensic odontology. Many scientists and lawyers have questioned the validity of dental uniqueness determination and its subsequent use in bitemark analysis.⁶ Several scientific papers have sought to prove the uniqueness of the human dentition, however, this debate may be moot, as the real issue centres around how much detail of the dentition is transferred, or not transferred, to the bitemark.¹⁰

In some cases failure of the procedural compliance has led to the bitemark analysis being wrongly branded as a "pseudoscience", a point emphasised in anti-bitemark literature and more recently by organisations such as the Innocence Project (IP). Reports of errors made by forensic odontologists in bitemark cases in the 1980s and 1990s have subjected this science to aggressive and disparaging criticisms.¹¹⁻¹² It is acknowledged that a wrongful conviction can have dreadful consequences, both for the convicted person and the justice system. As a result, the forensic odontologist must understand the limitations of bitemark analysis and adopt a conservative approach, including developing quality assurance procedures that limit biases and eliminate false or exaggerated conclusions.¹⁰

The Innocence Project reports that 351 persons have been exonerated using DNA evidence. However, only 27 of these cases included bitemark evidence (approximately 8% of the total). Not all of these cases were exonerations based on DNA analysis alone, as some were based on post-conviction work of forensic odontologists with extensive bitemark experience unrelated to IP.¹³ From this, the value of forensic odontologists in the field of bitemark analysis cannot be ignored. Certainly, some form of contradiction exists as IP attorneys may criticise the evidence of bitemark analysis in some situations, yet they choose to use forensic odontologists experienced in bitemark analysis in other situations.¹⁰

It cannot be overstressed that the comparison of bitemarks must be regarded as a scientific analysis in which a degree of concordance is demonstrated or rejected. Only individuals experienced in bitemark analysis should analyse the relevant evidence, give an impartial scientific appraisal to the court, and leave the final verdict to the judicial system. In this way, bitemark analysis should not be considered a procedure in which a suspect is found guilty or innocent.⁴

CONCLUSION

The analysis of bitemarks found on skin or inanimate objects should only be carried out by a competent, well-trained forensic odontologist experienced in this field. Many of the cited cases where bitemark analysis decisions have been overturned are not because of a failure of the science, but rather due to poor decision-making by forensic odontologists who are not adequately trained in this field.⁵

In summary, the current authors agree with some of the comments below adapted from the final paragraph of an article published by a critic of bitemark evidence:

- Respect the bounds of actual knowledge.
- Abandon claims of uniqueness and absoluteness.
- Abandon the use of misleading terminologies such as match, identification or absolute certainty.
- Offer descriptions and opinions with clarity and candour.
- Offer conclusions with modesty.
- Resist any form of exaggeration.
- Always utilise evidence-based forensic science.¹²

References

1. Scheid RC, Woelfel JB. *Woelfel's Dental Anatomy: its relevance to dentistry*. Philadelphia, Wolters Kluwer/Lippincott Williams & Wilkins. 2007.
2. Reinprecht S, van Staden PJ, Jordaan J, Bernitz H. An analysis of dental intercanine distance for use in court cases involving bite marks. *Int J Legal Med*. 2017; 131(2): 459-64.
3. Bernitz H, Owen JH, van Heerden WFP, Solheim T. An integrated technique for the analysis of skin bite marks. *J Forensic Sci*. 2008; 53(1):194-8.
4. Bernitz H, Kloppers BA. *Bite Mark Collection and Analysis*. In: *Forensic Odonto-Stomatology* by IOFOS. 1st ed: Naklada Slap. 2020.
5. Payne-James J, Byard RW. *Encyclopedia of forensic and legal medicine*. Amsterdam, Netherlands: Elsevier. 2015.
6. Pretty IA, Sweet D. The scientific basis for human bitemark analyses - a critical review. *Sci Justice*. 2001; 41(2): 85-92.
7. Stols G, Bernitz H. Reconstruction of deformed bite marks using affine transformations. *J Forensic Sci*. 2010; 55(3): 784-7.
8. Bernitz H. Concepts to elucidate the pattern-associated analysis of tooth marks in court. *SADJ*. 2005; 60(2): 62, 4-5.
9. Pretty IA, Sweet DJ. The judicial view of bitemarks within the United States Criminal Justice System. *J Forensic Odontostomatol*. 2006; 24(1): 1-11.
10. Barsley RE, Bernstein ML, Brumit PC, Dorion RBJ, Golden GS, Lewis JM, et al. Epidermis and Enamel: Insights Into Gnawing Criticisms of Human Bitemark Evidence. *Am J Forensic Med Pathol*. 2018; 39(2): 87-97.
11. Saks MJ, Albright T, Bohan TL, Bierer BE, Bowers CM, Bush MA, et al. Forensic bitemark identification: weak foundations, exaggerated claims. *J Law Biosci*. 2016; 3(3): 538-75.
12. Saks MJ. Forensic identification: From a faith-based "Science" to a scientific science. *Forensic Sci Int*. 2010; 201(1-3): 14-7.
13. Innocence Project. *DNA Exonerations in the United States*. The Innocence Project Website. 2017. Available from: <https://www.innocenceproject.org/dna-exonerations-in-the-united-states/>. Accessed October 20, 2020.

Do the CPD questionnaire on page 168

The Continuous Professional Development (CPD) section provides for twenty general questions and five ethics questions. The section provides members with a valuable source of CPD points whilst also achieving the objective of CPD, to assure continuing education. The importance of continuing professional development should not be underestimated, it is a career-long obligation for practicing professionals.



Online CPD in 6 Easy Steps

1. Go to the SADA website www.sada.co.za.
2. Log into the 'member only' section with your unique SADA username and password.
3. Select the CPD navigation tab.
4. Select the questionnaire that you wish to complete.
5. Enter your multiple choice answers. Please note that you have two attempts to obtain at least 70%.
6. View and print your CPD certificate.