

# Mandibular myiasis: A case report

SADJ March 2022, Vol. 77 No. 2 p92- p93

I Abdoola<sup>1</sup>, MMR Bouckaert<sup>2</sup>, M Ibrahim<sup>3</sup>

## ABSTRACT

Myiasis is a condition characterised by the infestation of live vertebrates with dipterous larvae. Myiasis is derived from the Greek word mya, meaning fly. Dipterans, (order Diptera), are two-winged insects known as true flies. Myiasis tends to occur in cutaneous, necrotic lesions of patients who have weak immune systems, who inhabit unhygienic environments. Maggot Debridement Therapy is an uncommon treatment of debriding necrotic tissue, with some utility. A case of mandibular myiasis involving a malignant mandibular lesion that was colonised by maggots is discussed.

## Key words

Myiasis, maggot, oral, facial, infection, wound

## INTRODUCTION

Myiasis is a condition characterised by the infestation of live vertebrates with dipterous larvae<sup>1</sup>. Myiasis is derived from the Greek word mya, meaning fly. Dipterans (order Diptera) are two-winged insects known as true flies<sup>2</sup>. The Old Testament was the first written account of human myiasis<sup>3</sup>. It is more common in the tropical and sub-tropical regions of Africa, Central America and South America.

## CASE REPORT

A 71-year-old male patient presented with a two-month history of ulceration on the dorsum of the tongue. Three weeks prior to presentation, infection developed, the patient lost the ability of speech and the lesion became infested by maggots. On examination, the patient was cachexic and an obvious lesion on the genium was noted with associated hyperpigmented skin and maggot infestation.

Dysmorphic, necrotic tissue was noted on the anterior aspect of the mandible extending posteriorly along the floor

of the mouth. Poor hygiene and mobile teeth were salient. The lesion was debrided, a biopsy was taken, dressings were placed and the patient was prepared for admission to the hospital. Prior to being transported to the ward, the patient developed cardiac arrest. Resuscitation was attempted unsuccessfully and the patient demised. The histology confirmed a squamous cell carcinoma.

## DISCUSSION

Human myiasis may be classified according to anatomical location. Cutaneous myiasis may be further classified into wound, furuncular and migratory myiasis<sup>4</sup>. Wound myiasis is the most common type encountered. The infestation of larvae in a necrotic lesion is considered to be wound, traumatic or opportunistic myiasis. Myiasis may be caused by a variety of fly species, with a particular species being either obligate, facultative or accidental parasites. Although different species may cause wound myiasis, generally only one species is found in a particular lesion<sup>1</sup>. Cutaneous lesions usually heal well, often with minimal or no scarring<sup>1</sup>. In a South African study by Kuria *et al*, 25 cases of wound myiasis were diagnosed over a four-year period in the Eastern Cape. The commonly encountered species leading to human myiasis are *Lucilia Sericata* and *Lucilia Cuprina*, with the latter

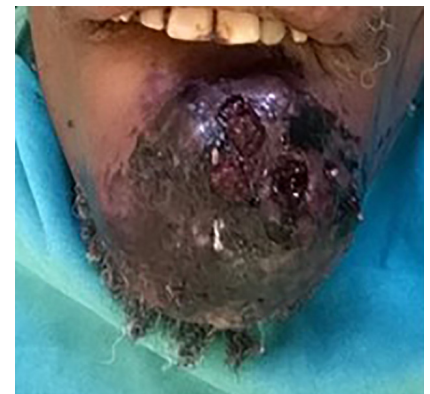

Figure 1: Patient presentation with a maggot-infested anterior mandible

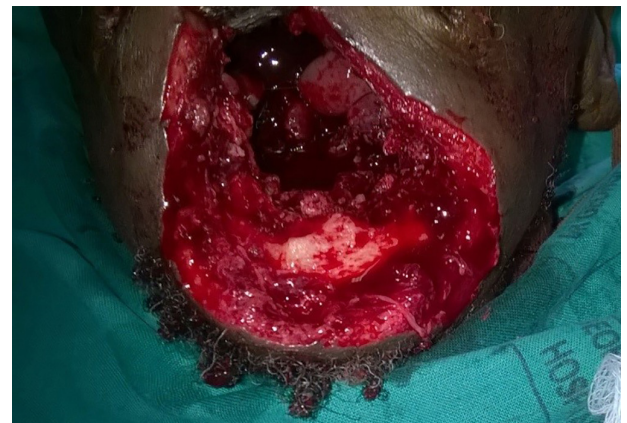


Figure 2: Following debridement of the lesion

## Author affiliations:

1. I Abdoola: *BChD, MChD (MFOS), FCMFOS*. Lenmed Royal Hospital and Heart Centre. Previously of Department of Maxillofacial and Oral Surgery, Medunsa Oral Health Centre, Sefako Makgatho Health Sciences University (SMU), Pretoria, South Africa. ORCID: 0000-0001-9361-5407
2. MMR Bouckaert: *MDent, FFD, FCMFOS*, Professor, senior consultant: Maxillofacial and Oral Surgery, Medunsa Oral Health Centre, Sefako Makgatho Health Sciences University (SMU), Pretoria, South Africa. ORCID number: 0000-0001-9337-3671
3. M Ibrahim : *BChD, PDD (Sedation and Pain Control)*. Lenmed Royal Hospital and Heart Centre. ORCID number: 0000-0003-2548-4630

## Corresponding author: I Abdoola

Suite 106, Lenmed Royal Hospital and Heart Centre, 6 Welgevonden Street, Royldene, Kimberley, 8301  
E-mail: maxfax@dr.com  
Tel: 053 045 0532/3

## The role played and the respective contribution:

1. I Abdoola: Writing article, data collection, data analysis – 50%
2. MMR Bouckaert: Corrections - 25%
3. M Ibrahim: Data analysis, researching relevant related articles – 25%

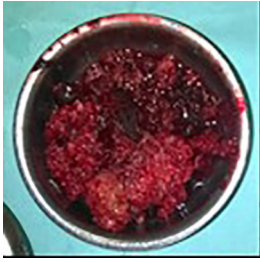


Figure 3: The debrided necrotic tissue and maggots



Figure 4: *Lucilia sericata*, a species used for maggot debridement therapy<sup>6</sup>



being the most prevalent noted<sup>4</sup>. Flies may deposit larvae on clothing, soil, wounds, or on mosquitos; these act as fomites and vectors in larval transmission. Incubation periods of obligate parasites vary according to species, lasting up to 12 weeks in *Dermatobia Hominis* (Human Botfly) (Figure 4).

### Diagnosis

Wound myiasis is usually easily diagnosed on inspection. A high clinical suspicion is warranted, especially with the history of travel to endemic areas within 12 weeks. Pain, malodorous suppuration and the sensation of movement beneath the skin may be clues to the presence of larvae. Ultrasound is a useful diagnostic tool. Identification of larvae is sufficient and biopsy may not be necessary if the underlying cause of necrosis is known<sup>1</sup>.

### Risk factors

The most common predisposing factors to developing human myiasis in a South African population<sup>4</sup> was found to be lower limb gangrene due to peripheral vascular disease, followed by burns, cancerous ulcers and diabetic ulcers. Multiple predisposing factors exist<sup>1,4</sup>, including poor hygiene, immunosuppression, old age, alcohol abuse, exposed wounds, suppurative lesions, necrotic tissue, malignant wounds, poor sanitation, poor garbage disposal and low socioeconomic status.

### TREATMENT

Mechanical debridement is generally the basis of management<sup>1</sup>. Removal of necrotic tissue and larvae may be supplemented by irrigation (especially for cavities) or medication (such as Ivermectin for migratory myiasis). Debridement should be followed by meticulous wound care. Wound care and hygiene, especially of debilitated patients, should be optimal to preclude cases secondary to medical neglect.

### Maggot debridement therapy (MDT)

MDT or artificially induced myiasis was commonly used in the past. MDT is the deliberate use of larvae to debride necrotic tissue, produce antimicrobial compounds and promote healing if used correctly. Use of MDT was noted in the past millennium by aborigines, Mayans and Burmese. Ambroise Pare noticed the benefit of maggots in the 1500s when a patient lost tissue equivalent to the volume of a hand through an infection involving the skull and recovered. Maggots were used during World War I to debride wounds and were noted to improve recovery.

The perceived distasteful nature of the treatment led to a period of disuse. Justified by contemporary research, a recent surge has been noted in the use of maggot debridement therapy in selected patients with long-stand-

ing wounds that persist despite attempts of conventional treatment. Contraindications include the presence of large vessels, vital structures or hollow organs near the wound. The larvae of the Green Bottle Housefly (*Lucilia Sericata*) are the most commonly used species in these cases<sup>3</sup>. Maggots effectively and selectively debride necrotic tissue and due to their photophobic nature, will debride regions where surgical access may otherwise be challenging<sup>1</sup>. Larvae used in MDT produce agents similar to antibiotics, alkalize wounds by secreted ammonia, ingest bacteria and produce substances that promote wound healing<sup>3</sup>. Larvae must be prepared in a sterile manner for MDT use and removed after a maximum of three days<sup>1,5</sup>.

### Declaration

No sources of funding or financial interests are applicable. This article has not been previously published.

### Acknowledgements

Many thanks are due to the Department of Maxillofacial and Oral Surgery, SMU and to Lenmed Royal Hospital and Heart Centre

### Conflict of interest

No conflicts of interest

### References

1. Francesconi F, Lupi O. Myiasis. *Clin Microbiol Rev.* 2012; 25 (1): 79-105
2. Oldroyd H. Dipteran [internet]. *Britannica* [cited 2020 December 30]. Available from: <https://www.britannica.com/animal/dipteran>
3. Whitaker IS, Twine C, Whitaker MJ, Welck M, Brown CS, Shandall A. Larval therapy from antiquity to the present day: mechanisms of action, clinical applications and future potential. *Postgrad Med J.* 2007; 83(980): 409-413.
4. Kuria SK, Kingu HJC, Villet MH, Dhaffala A. Human myiasis in rural South Africa is under-reported. *SAMJ.* 2015; 105(2): 129-133.
5. Donnelly J. Wound healing--from poultices to maggots. (A short synopsis of wound healing throughout the ages). *Ulster Med J.* 1998; 67(1): 47-51.
6. Derraik JGB, Heath A, Rademaker M. Human myiasis in New Zealand: imported and indigenously-acquired cases: the species of concern and clinical aspects. *NZ Med Jour.* 2010; 123: 21-38.