

# Radiology corner

SADJ February 2023, Vol. 78 No.1 p48

C Smit<sup>1</sup>, L Robinson<sup>2</sup>

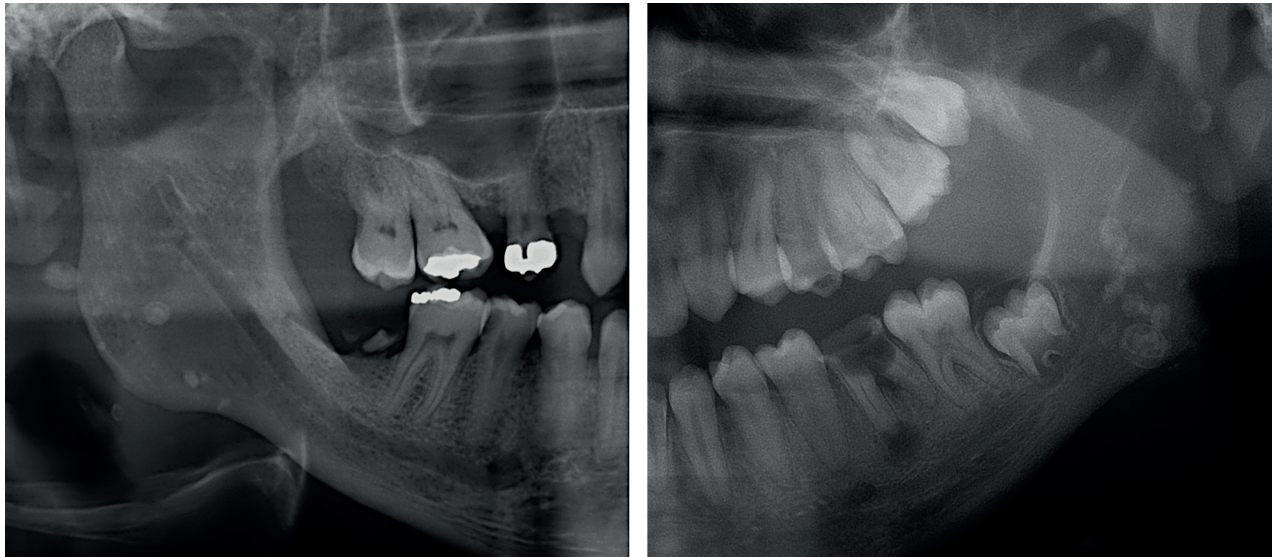


Figure 1: (A) Patient 1: Multiple concentric calcifications involving the right mandibular region. (B) Patient 2: Similar radiological presentation in a patient with a left facial swelling.

## CASES

Two patients presented with multiple concentric calcifications superimposed over the mandibular ramus region. The first patient was a 41-year-old male who presented to the dental clinic requesting a partial denture (Figure 1A). The calcifications were detected incidentally on panoramic radiography. The second patient was a 15-year-old female who presented with a left facial swelling that had been present for 7 years (Figure 1B). What is your diagnostic hypothesis for both patients?

## INTERPRETATION

Phleboliths are calcifications that arise from the organisation and mineralisation of intravascular thrombi, typically emanating from the stagnation of blood flow. They are

commonly seen in association with haemangiomas and vascular malformations, being detected in 27% of patients with venous malformations.<sup>1,2</sup> Phleboliths are slightly more common in females, however, their true incidence is largely unknown as asymptomatic cases are detected incidentally on routine imaging.<sup>1</sup> In the head and neck, phleboliths are commonly found in the cheek region.<sup>1</sup> They are usually asymptomatic, but may present with pain as an accompanying symptom in 30% of cases.<sup>1</sup> Radiologically, they present with a target-like appearance with a dense core surrounded by a hypodense rim and/or lamellated periphery.<sup>1-3</sup>

Phleboliths are often multiple and range in size from 2mm to 15 mm in diameter.<sup>1</sup> Due to their location their distinction from sialoliths may be challenging.<sup>2</sup> The target-like appearance and presence of multiple calcifications are more suggestive of phleboliths. Treatment is usually performed in symptomatic cases or patients with aesthetic concerns. This includes removal of the phleboliths, and/or laser and sclerotherapy for the accompanying vascular tumour.<sup>1</sup>

### Author Contributions:

1. Dr. C Smit: *BChD, MSc* (Maxillofacial and Oral Radiology). ORCID: 0000-0003-4047-6356
2. Dr. L Robinson: *BChD, PDD* (Maxillofacial Radiology), *PDD* (Forensic Odontology), *MChD* (Oral Path), *FC Path* (SA) Oral Path. ORCID: 0000-0002-0549-7824

Department of Oral and Maxillofacial Pathology, Faculty of Health Sciences, University of Pretoria.

### Authors declaration:

Funding: This research did not receive any specific grant from funding agencies in the public, commercial, or not-for-profit sectors.

Conflict of Interest: The authors declare that they have no conflict of interest.

### Ethics approval:

This study was approved by the University of Pretoria, Faculty of Health Sciences Research Ethics Committee (Reference no.: 585/2022). All procedures followed the ethical standards of the Helsinki Declaration of 1975, as revised in 2008.

### Authors contribution:

Dr. C Smit 50%  
Dr. L Robinson 50%

## REFERENCES

1. Eivazi B, Fasunla AJ, Güldner C, Masberg P, Werner JA, Teymoortash A. Phleboliths from venous malformations of the head and neck. *Phlebology*. 2013 Mar;28(2):86-92.
2. Su YX, Liao GQ, Wang L, Liang YJ, Chu M, Zheng GS. Sialoliths or phleboliths?. *The Laryngoscope*. 2009 Jul;119(7):1344-1347.
3. Zengin AZ, Celenk P, Sumer AP. Intramuscular hemangioma presenting with multiple phleboliths: a case report. *Oral Surgery, Oral Medicine, Oral Pathology and Oral Radiology*. 2013 Jan 1;115(1):32-36.