


THE SOUTH AFRICAN DENTAL JOURNAL

SADJ

MARCH 2024
Volume 79 Number 2

ISSN No. 2519-0105 – Online Edition
ISSN No. 1029-4864 – Print Edition



Marula (Sclerocarya birrea)

This fruitful tree is what many of us associate with the creamy liqueur, Amarula. Another fabled African tree, marula trees have eight times as much as Vitamin C as oranges (and more than the baobab contains), and their nut-like seeds are edible and can be used in cooking. Some sources even claim you can substitute coffee for the dried skin of marula fruits. The funniest story you may have heard about marula trees and their fruit is the one of elephants, whose long trunks help them reach high up into trees to pick the fruit, getting drunk off the fermented fruits still hanging from the tree.



SADA

THE SOUTH AFRICAN
DENTAL ASSOCIATION


 **straumann**

GALVOSURGE® DENTAL IMPLANT CLEANING SYSTEM

Biofilm removal and implant
surface decontamination
in 2 minutes.



For more information,
visit www.straumann.com
or contact Straumann Group
South Africa +27 21 850 0823



GEMS CYTOLOGY TEST SCREENING BENEFIT FOR 2024

GEMS would like to thank all the healthcare providers for rendering healthcare services to its beneficiaries.



If you have any queries or wish to participate in the GEMS Provider Network,

- ✓ Call us on 0860 436 777, weekdays between 08:00 and 17:00; or
- ✓ Send an email to enquiries@gems.gov.za.







The Scheme has carefully reviewed the recommendations made by **healthcare providers regarding the Cytology Screening tests** and is pleased to inform you of the **enhancements made with effect from 01 January 2024. An in-house code 99385** (Sterile tray and specimen handling fee) has been created for Practice types 14/15 and 16 only, across all benefit options. This is to be used in the place of the codes **0202 / 0210**, when claiming for the performance of the Cytology screening test. (taking pap smears).

DISCOVER THE
**BRILLIANCE
OF GEMS**

Contact details

086 043 6777
enquiries@gems.gov.za
www.gems.gov.za

-  **@GEMSMEDICALAID**
-  **@GEMSMEDICALAID**
-  **@GEMSMEDICALAID**
-  **Government Employees Medical Scheme**



Use the QR Code to
download the **GEMS
Provider App**



EDITORIAL OFFICE

Managing Editor

Prof NH Wood

Editorial Assistant

Mr Dumis Ngoepe

Email: Sadj@sada.co.za

Sub-editors

Prof N Mohamed

Prof P Owen

Prof L Sykes

Prof J Yengopal

Please direct all correspondence to:

South African Dental Association

Private Bag 1, Houghton 2041

Tel: +27 (0)11 484 5288

Fax: +27 (0)11 642 5718

Email: info@sada.co.za

Editorial Board

Prof V Yengopal University of the Western Cape

Prof T Madiba University of Pretoria

Prof S Singh University of KwaZulu-Natal

Prof P Owen University of Witwatersrand

Prof P Motloba Sefako Makgatho Health

Sciences University

Prof P Moipolai Sefako Makgatho Health

Sciences University

Prof NH Wood University of Witwatersrand

Prof MPS Sethusa Sefako Makgatho Health

Sciences University

Prof L Sykes University of Pretoria

Dr J Schaap University of Pretoria

Prof J Morkel University of the Western Cape

Prof E Rikhotso University of Witwatersrand

Dr R Mthetwa Sefako Makgatho Health

Sciences University

Dr E Patel University of Witwatersrand

Prof N Mohamed University of the Western Cape

Prof H Holmes University of the Western Cape

Prof H Gluckman Private Practice

Dr C Nel University of Pretoria

SADA OFFICE BEARERS

National Council

President:

Vice-President: Dr P Mathai

SADA Board of Directors

Chairperson Dr N Osman

Vice-chairperson Dr FC Meyer

Dr EK Naidoo

Dr F Mansoor

Dr SY Pieters

Dr T Buleni

Mr H Keshave

Mr KC Makhubele (CEO)

EDITORIAL

Redefining Dental Horizons: Embracing Technological and Biotechnological Innovations in Oral Health Care

– Prof NH Wood

65

COMMUNIQUE

35 critical points revealing potential pitfalls of the NHI Bill in its current form – Mr Makhubele

67

RESEARCH

Dental patients' knowledge, attitudes and experiences related to voluntary counselling and testing for HIV in the dental setting in eThekweni district, KwaZulu-Natal –

S Balwanth, S Singh

69

Root and canal morphology of the maxillary first molar: A micro-computed tomography-focused observation of literature with illustrative cases. Part 2: Internal root morphology – CH Jonker, PJ van der Vyver, AC Oettlé

75

In vitro comparative study of the ethanol and aqueous extracts of Spondias mombim leaves, stem bark and charcoal on Streptococcus mutans – Gertrude C Iwueke, W Braide, Stanley C Onwubu, Samuel C Iwuji, AS Joe-Izuegbu

86

REVIEW


A simplified and evidence-informed approach to designing removable partial dentures. Part 5. Design examples for Kennedy classifications – C Peter Owen

92

Our Front Cover for this Issue...

Marula
(*Sclerocarya birrea*)

This fruitful tree is what many of us associate with the creamy liqueur, Amarula. Another fabled African tree, marula trees have eight times as much as Vitamin C as oranges (and more than the baobab contains), and their nut-like seeds are edible and can be used in cooking. Some sources even claim you can substitute coffee for the dried skin of marula fruits. The funniest story you may have heard about marula trees and their fruit is the one of elephants, whose long trunks help them reach high up into trees to pick the fruit, getting drunk off the fermented fruits still hanging from the tree.



Published by:

CREATIVE
SPACE
MEDIA

On behalf of:

SADA
THE SOUTH AFRICAN
DENTAL ASSOCIATION

SADA OFFICE BEARERS

Chairpersons of Board Sub-Committees

Audit & Risk Committee Mr H Keshave
 Strategy, Ethics &
 Remuneration Committee Dr SY Pieters
 Dental Practice Committee Dr FC Meyer

Chairperson of DDF Board of Trustees

Dr B Beilinson

PRODUCTION OFFICE

Creative Space Media
 Tel: +27 (11) 467 3341
 Website: www.creativespacemedia.co.za

Publisher and Project manager

Yolandi Badenhorst – yolandi@creativespacemedia.co.za
 Leani Thomson – leani@creativespacemedia.co.za

GENERAL AND ADVERTISING ENQUIRIES

James Chademana
 Email: james@creativespacemedia.co.za
 Tel: +27 (11) 467 3341

Design and Layout

Leani Thomson
 Email: leani@creativespacemedia.co.za

Website smalls advertising / CPD Enquiries and

Member contact detail update

South African Dental Association
 Tel: +27 (0)11 484 5288
 Email: marketing@sada.co.za

Published by:

On behalf of:

NARRATIVE REVIEW

Oral health in children and adolescents with special healthcare needs in South Africa: A narrative review – *N Njoroge, A Magan, P Hlongwa* 102

EVIDENCE BASE DENTISTRY

What's new for the clinician – summaries of recently published papers (March 2024) – *Prof V Yengopal* 109

ETHICS

Terminating dentist-patient relationships: balancing ethics and practical considerations – *Mr Punkaj Govan* 113

RADIOLOGY CORNER

MAXILLOFACIAL RADIOLOGY - Double type III dens invaginatus – *J Simpson, L Janse van Rensburg* 118

CPD

CPD questionnaire 120

AUTHOR GUIDELINES

Instructions to authors and author's checklist 122

Editorial, Advertising and Copyright Policy

Opinions and statements, of whatever nature, are published under the authority of the submitting author, and the inclusion or exclusion of any medicine or procedure does not represent the official policy of the South African Dental Association or its associates, unless an express statement accompanies the item in question. All articles published as Original Research Papers are refereed, and articles published under Clinical Practice or Reviewed Notes are submitted for peer review.

The publication of advertisements of materials or services does not imply an endorsement by the Association or a submitting author, should such material feature as part of or appear in the vicinity of any contribution, unless an express statement accompanies the item in question. The Association or its associates do not guarantee any claims made for products by their manufacturers.

While every effort is made to ensure accurate reproduction, the authors, advisors, publishers and their employees or agents shall not be responsible, or in any way liable for errors, omissions or inaccuracies in the publication, whether arising from negligence or otherwise or for any consequences arising therefrom.

The South African Dental Journal is a peer reviewed, Open Access Journal, adhering to the Budapest Open Access Initiative: "By 'open access' to this literature, we mean its free availability on the public internet, permitting any users to read, download, copy, distribute, print, search, or link to the full texts of these articles, crawl them for indexing, pass them as data to software, or use them for any other lawful purpose, without financial, legal, or technical barriers other than those inseparable from gaining access to the internet itself. The only constraint on reproduction and distribution, and the only role for copyright in this domain, should be to give authors control over the integrity of their work and the right to be properly acknowledged and cited."

Accredited by the Department of Education SADJ is published 10 times a year by E-Doc, a Division of Pharmcom CC, on behalf of The South African Dental Association. © 2022 Pharmcom CC.

Galley proofs

No galley proofs will be provided please ensure that all submissions are correct after the review revision submission.

Crafting the Future of Dental Education: Navigating the Nuances of Speaker Selection

SADJ March 2024, Vol. 79 No.2 p65-66

Prof NH Wood - *BChD, DipOdont(MFP), MDent(OMP), FCD(SA), PhD*

A confluence of technological innovation and biotechnological discovery is setting the stage for an unprecedented evolution in dental care and education. Dentistry is witnessing a paradigm shift, driven by the relentless pursuit of excellence, precision, and patient-centric approaches. This transformative era is characterized by the integration of advanced technologies such as nanotechnology, digital workflows, and artificial intelligence, alongside groundbreaking biotechnological advancements in regenerative medicine and personalized care. These developments not only promise to enhance the efficacy and efficiency of dental treatments but also aim to elevate the patient experience to new heights, offering solutions that are not just remedial but also preventative and restorative in nature.

The advent of these innovations marks a pivotal moment in dentistry, challenging traditional practices and redefining the boundaries of what is possible. From the microscopic precision of nanomaterials in restorative dentistry to the bespoke tailoring of treatments through genomic insights, the field is undergoing a renaissance that places a premium on innovation, research, and adaptability. As dental professionals and academicians, we stand at the threshold of this exciting frontier, tasked with the responsibility of harnessing these advancements for the betterment of oral health care. Through a rigorous examination of the current and potential impacts of these trends, we can chart a course towards a future where dentistry not only repairs but also regenerates, personalizes, and transcends the conventional limitations of care, promising a brighter, healthier future for patients worldwide.

The realm of regenerative dentistry, particularly through the exploration and application of stem cells, stands at the cusp of a paradigm shift in how dental professionals approach the treatment of complex dental issues. Stem cells, with their unique ability to differentiate into various cell types, hold the promise of regenerating not just damaged dental tissues but potentially facilitating the growth of entire teeth. Among the most studied are dental pulp stem cells (DPSCs), which are derived from the dental pulp of permanent teeth, and stem cells from human exfoliated deciduous teeth (SHED), offering a glimpse into the future where biological solutions could supersede traditional prosthetics and restorative materials. This biotechnological advance not only heralds a new era in dental care that leans more towards natural regeneration but also aligns with the broader medical field's shift towards more personalized and biologically integrated treatments.

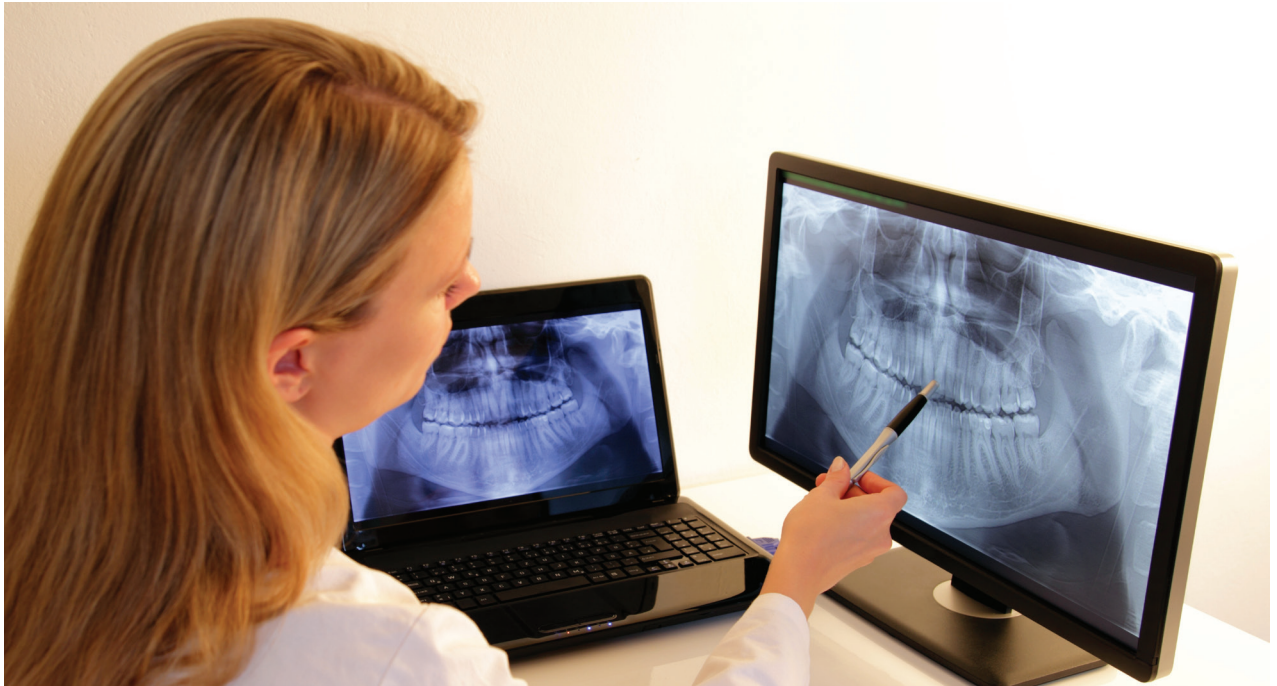A notable reference that encapsulates the breadth of this research and its implications for the future of dentistry is the work by Ayala Escandón CL and Cortes Ramírez JM. Their

review, "Dentistry facing the biotechnological advances of the 21st century," delves into how stem cell research is pioneering the regeneration of dental tissues, offering insights into the practical applications and future directions of these technologies in clinical settings. The authors underscore the potential of stem cells to revolutionize dental treatments, moving towards a more regenerative model that not only enhances the body's natural healing processes but also paves the way for groundbreaking advancements in dental care. The authors recommend a path forward, highlighting the critical role of biotechnology in shaping a future where dental care is as much about regeneration and restoration as it is about prevention and maintenance.

The dawn of personalized dental medicine marks a transformative era in the field of dentistry, where treatments are no longer a one-size-fits-all solution but are tailored to the unique genetic makeup of everyone. This bespoke approach to dental care leverages the vast advancements in molecular biology and genomics, enabling dental professionals to predict susceptibility to various oral diseases, customize preventative strategies, and optimize therapeutic interventions with unprecedented precision. Imagine a future where your dental care regimen is designed specifically for you, considering your genetic predispositions to conditions such as periodontal disease, dental caries, or even oral cancers. Personalized dental medicine not only promises enhanced efficacy of dental treatments but also heralds a new age of preventive care, where the focus shifts from managing oral health issues as they arise to preventing them before they can take hold.

A pioneering reference in this field is a piece by Guven titled "Scientific basis of dentistry" that delves into how the integration of genomic studies and proteomes into dental practice is setting the stage for this revolutionary shift towards personalized care. Guven's analysis outlines the potential of genotherapy, gene mutation studies, and stem cell research to redefine dental care, moving it from an art to a precise science. This transition to personalized dental medicine is not just a testament to the technological and scientific strides made in recent years but also a beacon of hope for patients worldwide. It promises a future where dental care is more effective, less invasive, and tailored to the individual needs of each patient, ensuring optimal oral health outcomes and transforming the patient experience in dental healthcare. This exploration of personalized dental medicine not only excites the imagination with possibilities for the future but also challenges the dental community to embrace these innovations and redefine what is possible in dental care.

Nanotechnology in dentistry has emerged as a frontier field, redefining the limits of diagnosis, treatment, and materials



used in dental care with its microscopic precision and potential for innovation. At the heart of this technological revolution is the development of nanomaterials that promise to significantly enhance the properties of dental biomaterials, making them more durable, aesthetically pleasing, and biocompatible. For instance, nanocomposites have been developed that offer superior strength and polishability compared to their traditional counterparts, alongside nanoparticles that are being employed in toothpastes and mouthwashes for their antimicrobial properties, offering a new dimension to oral hygiene and caries prevention. Moreover, the advent of nanotechnology has paved the way for the emergence of nanorobots, microscopic entities that could perform intricate procedures such as targeted drug delivery to cancerous cells or precise removal of plaque from hard-to-reach areas. The studies by Alam MK et al. and Khurshid Z et al. highlight the groundbreaking advancements nanotechnology brings to the dental field, from improving the mechanical and physical properties of restorative materials to introducing novel diagnostic and therapeutic approaches that promise to elevate patient care to unprecedented levels of efficacy and safety. Through these pioneering research efforts, nanotechnology is not just enhancing dental materials and practices but is setting a new standard for the future of dental care, making it a critical area of focus for ongoing and future dental research.

Emerging industrial trends in dentistry encapsulate a transformative shift towards digitalization and automation, heralding a new era where precision, efficiency, and patient-centred care become the cornerstone of dental practice. Beyond the advancements in regenerative dentistry, personalized medicine, and nanotechnology, the dental field is witnessing a revolution in the adoption of digital workflows, such as 3D printing for prosthetics and orthodontic devices, digital impressions for enhanced accuracy, and computer-aided design/computer-aided manufacturing (CAD/CAM) systems that streamline the creation of dental restorations. Artificial Intelligence (AI) and machine learning algorithms are being integrated into diagnostic tools, offering predictive insights into patient outcomes and personalized treatment plans. Moreover, the rise of teledentistry and mobile dental

services since the COVID-19 pandemic has expanded access to dental care, breaking down geographical barriers and making dental services more accessible to underserved populations. These emerging trends not only reflect the dental industry's rapid evolution but also its commitment to adopting technologies that improve patient outcomes, optimize treatment processes, and enhance the overall patient experience. As the dental field continues to evolve, these industrial trends will play a pivotal role in shaping the future landscape of dental care, making it more adaptive, innovative, and inclusive.

The fusion of technological and biotechnological innovations offers a beacon of hope and a roadmap for transformative care. The advancements we've explored, from the precision of nanotechnology to the promise of personalized dental medicine, and the efficiency of emerging industrial trends, are not merely incremental improvements but are pivotal shifts that redefine the essence of dental practice. These innovations herald a future where dental care is more accessible, less invasive, and significantly more effective, underpinned by a commitment to scientific excellence and patient-centric approaches. Embracing these changes requires not only adaptation but also a reinvigoration of our educational frameworks, research priorities, and clinical practices. As we chart this unexplored territory, our collective endeavor should be to harness these advancements to improve oral health outcomes, enhance patient experiences, and ultimately, elevate the dental profession to new heights of relevance and impact in the 21st century. This editorial serves as a call to action for the global dental community to engage with, contribute to, and lead the next revolution in dental care, ensuring a legacy of innovation and excellence for generations to come.

Further reading:

1. Alam MK, Srivastava K, Khamis M, Husein A. Editorial: Recent advancements in the dental biomaterials applied in various diagnostic, restorative, regenerative, and therapeutic procedures. *Front Bioeng Biotechnol.* 2023;10:1116208.
2. Ayala Escandón CL, Cortes Ramirez JM. Dentistry facing the biotechnological advances of the 21st century. *J Oral Res.* 2018; 7(7):276-278.
3. Guven Y. Scientific basis of dentistry. *J Ist Faculty Dent.* 2017; 51(3 Suppl 1):S10-S18.
4. Khurshid Z, Zafar M, Qasim S, Shahab S, Naseem M, AbuReqaiba A. Advances in Nanotechnology for Restorative Dentistry. *Materials (Basel).* 2015; 8(2):717-731.

35 critical points revealing potential pitfalls of the NHI Bill in its current form

SADJ March 2024, Vol. 79 No.2 p67-68

Mr KC Makhubele – CEO, South African Dental Association

President Cyril Ramaphosa in his state of the nation address indicated that he was looking for the pen – a strong signal that he will sign the NHI Bill into an Act of Parliament.

The National Council of Provinces (NCOP) voted in favour of the NHI Bill on November 29 2023. As the NCOP Select Committee on Health and Social Services moves forward with the NHI Bill, its recent decision to adopt the bill without amendments signals a setback for the private healthcare sector. Despite the sector's hopes for MPs to reconsider certain provisions, the bill is now one step closer to final approval by the NCOP.

The impending vote, scheduled for next week, raises concerns, particularly as the bill proposes substantial reforms to South Africa's healthcare system, emphasising a single NHI fund to procure services on behalf of eligible patients while diminishing the role of medical schemes. However, this development has not been without criticism, with the South African Dental Association (SADA) expressing disappointment that its submissions have seemingly gone unheard. In the face of the bill's progression, it becomes crucial to examine 35 key points highlighting why the current form of the NHI Bill may face challenges and potential shortcomings which are organised into five groups.

Group 1: Financial and Operational Challenges

South Africa lacks the physical and financial capacity to sustain the current NHI model.

Increased taxes on a shrinking tax base will likely trigger mass emigration of taxpayers, reducing funding.

NHI implementation may lead to a significant exodus of healthcare professionals, exacerbating challenges. The OHSC struggles to inspect and accredit facilities promptly, hindering the accreditation of healthcare providers. Only Western Cape and Gauteng have scored sufficiently for accreditation under the NHI, leaving other areas underserved.

Group 2: Governance and Powers

The NHI grants the health minister extensive powers, risking an overreach into day-to-day fund operations.

Unvetted powers in the bill allow the health minister to make impactful health regulations without proper oversight.

Provisionally declared unconstitutional Certificates of Need (CONs), relied upon by the NHI, complicate the placement of service providers.

Lack of transparency in addressing skills shortages, particularly in remote areas, poses a significant challenge. NHI registration online overlooks millions without access to electricity, water and the internet, creating inequities.



Group 3: Operational Inefficiencies and Impact on Healthcare

Insufficient feasibility studies post-Covid-19 regarding the financial impact of the NHI are a notable concern.

Centralisation under the NHI leads to a disconnect between government spheres, and worsening shortages in supplies. The bill removes day-to-day hospital administration from provinces, violating the constitutional framework.

District Health Management offices strip provincial powers unconstitutionally, lacking feasibility studies.

Centralisation impedes OHSC targets, necessitating a move towards decentralisation for improved efficiency.

Underfunded hospitals face shortages exacerbated by the NHI, affecting infrastructure, equipment and staffing.

Group 4: Patient Access and Rights

NHI does not address critical skills shortages or the chaotic placement of community service personnel. Fixed NHI Bill timeline dates are inaccurate and defunct, hindering effective implementation.

Referral pathways strain the system and may impede quick access to specific healthcare interventions.

Treatment protocols under the NHI may hinder the effective treatment of certain conditions and patients.

Maladministration of the NHI Fund could lead to a surge in medico-legal claims, impacting the health industry.

Group 5: Social and Ethical Considerations

NHI assumes the ability of poor individuals to travel for registration, dissuading people from seeking medical attention.

Lack of consideration for EMS equipment shortages in rural areas jeopardises timely access to medical services.

Public healthcare standards are already low, and the NHI may further abuse patients' rights to quality healthcare. No separation of powers within the fund can result in denied services and impact the success of appeals.

The bill aims to eventually remove medical aids, limiting individuals' right to choose healthcare and associations.

Group 6: Systemic Risks and Lack of Clarity

Erosion of the private health sector and well-functioning public facilities may strain the current system.

NHI violations of constitutional rights to employment for health practitioners and doctors raise concerns.

The exclusion of asylum seekers despite constitutional provisions in the NHI Bill is a notable ethical lapse.

Poor definition of emergencies and lack of clarity on medical necessity in the NHI pose risks to patient care.

The lack of information on covered procedures and healthcare products raises uncertainties about NHI coverage.

Group 7: Organisational and Financial Integrity

The fund's alleged autonomy is questionable, and its functions may be unachievable from the start.

Pooling funds makes the NHI vulnerable to theft and corruption, amplifying current supply chain mismanagement. Lack of external audit and risk procedures increases the risk of corruption and looting.

Uncertainty about the NHI's sharing of information and potential breaches of the Popi Act add to concerns.

NOTICE OF POSTPONEMENT OF THE SOUTH AFRICAN DENTAL ASSOCIATION (SADA) 2022 ANNUAL GENERAL MEETING

The SADA FYE 2022 Annual General Meeting (AGM), previously set for 25 April 2024, is postponed due to finalisation of the auditing procedures. The majority of the work has been finalised, but the last parts are only being finalised in early April 2024. A new date will be communicated soon. We apologize for any inconvenience.

Dr N Osman

SADA Board of Directors

2 April 2024



SADA
THE SOUTH AFRICAN
DENTAL ASSOCIATION

Dental patients' knowledge, attitudes and experiences related to voluntary counselling and testing for HIV in the dental setting in eThekweni district, KwaZulu-Natal

SADJ March 2024, Vol. 79 No.2 p69-74

S Balwanth,¹ S Singh²

ABSTRACT

Introduction

Globally, the number of people unaware of their HIV status, and the rate of transmission of the disease, remains high. Scaling up of HIV testing opportunities and settings, particularly in the dental clinical setting, is needed to address this major public health concern.

Aim and objectives

This study assessed dental patients' knowledge, attitudes and practices in voluntary counselling and rapid HIV testing (VCT) in the dental workplace in the eThekweni district, KwaZulu-Natal to determine their understanding and support for these services.

Methods

This was a cross-sectional, descriptive study. A total of 250 questionnaires were distributed to dental patients located in private and public dental settings in the eThekweni district. Two hundred and fifty (n=250) completed questionnaires were retrieved, yielding a response rate of 100%.

Results

More than half of the participants (n=134; 53.6%) indicated not to have heard of rapid HIV testing or were "unsure" of their knowledge regarding rapid HIV testing. The majority of participants (n=209; 83.6%) reported wanting the option to test for HIV at the dental workplace and 76.8% (n=192) indicated that rapid HIV testing should be routinely conducted by the oral healthcare worker. Participants (n=189; 75.6%) indicated to be less willing to partake in HIV testing should there be a cost implication. Some participants (n=104;

41.6%) indicated that they did not want the oral healthcare worker to perform the test due to perceived incompetency in rapid HIV counselling and testing. More participants from urban (n=214; 85.6%) and rural (n=217; 86.8%) areas of living were keen on the option to test for HIV at the dental workplace, with only 46.8% (n=117) of the informal dwellers sharing the same sentiment.

Conclusion

Participants reported inadequate knowledge and practice of VCT at the dental workplace. Participants had positive attitudes towards VCT implementation in the dental setting, provided that the cost of conducting of the test was free.

Keywords

HIV/AIDS, rapid HIV testing, dental workplace, oral healthcare workers

INTRODUCTION

South Africa is synonymous with the Human Immunodeficiency virus, as the country continues to inhabit the single largest population of 7.5 million people living with HIV. Almost 27% of the affected population is located in KwaZulu-Natal.¹⁻⁴ Despite progress being made towards the UNAIDS-endorsed 90-90-90 targets, South Africa had attained below targets of 85-71-86, emphasising the dire need to get more individuals tested, for ARV treatment and virally suppressed.⁴⁻⁵ Alarming, studies have shown that individuals presenting with an acute stage of HIV infection are more likely to transmit the virus than in advanced stages of infection.⁶⁻⁷ Therefore, scaling up of HIV testing sites is pertinent in ensuring more individuals are aware of their HIV status and do not spread the disease unknowingly. Early intervention strategies such as VCT allow oral healthcare workers an opportunity to provide patients with a comprehensive package of care that includes: HIV oral manifestation recognition, prompt HIV detection, proper linkages to care, education and support.⁸ The dental workplace, however, remains an untapped yet universal access point for HIV service delivery.

Multiple international studies have showed great support and optimism regarding implementation of VCT at the dental workplace.⁹⁻¹² Oral healthcare workers indicated a keenness to assist in the reduction of the disease transmission through

Authors' information

1. S Balwanth, *BChD (UWD), PG Dip Int Ortho (UWC), MMedSc (UKZN)*, Discipline of Dentistry, School of Health Sciences, University of KwaZulu-Natal, South Africa
ORCID: 0000-0003-2991-399X
2. S Singh, *PhD, BOH, M.Sc (Dent), PhD (UWC), PG Dip Heal Res Ethics (Stellenbosch)*, PhD Clin and Res Ethics (Stellenbosch), Professor, Discipline of Dentistry, School of Health Sciences, University of KwaZulu-Natal, South Africa
ORCID: 0000-0003-4842-602X

Corresponding author

Name: Prof S Singh
Email: singhshen@ukzn.ac.za

awareness campaigns as well as offering services such as VCT and supportive care.¹¹⁻¹² Locally, oral healthcare workers in eThekweni demonstrated positive attitudes towards VCT implementation in the dental setting, provided that adequate training and support was available from the KwaZulu-Natal Department of Health.¹³

The public and private dental sectors in eThekweni offer a range of basic and specialised dental services to the vast public who visit the dental workplace to attend to their oral needs and ailments. Despite the high prevalence of oral disease and manifestations related to HIV/AIDS, there is limited evidence to suggest that HIV testing forms part of routine oral healthcare. The oral cavity serves as a gateway to ensuring overall health and therefore the incorporation of VCT into the spectrum of dental services could prove beneficial to the wellbeing of the public and provide a safe healthcare environment for conduction of VCT. Rapid HIV testing has not yet been implemented to the dental workplace in KwaZulu-Natal, thereby creating a significant prospect to be investigated further. To our knowledge, this is the first study conducted in KwaZulu-Natal to determine dental patients' knowledge, attitudes and practices regarding VCT at the dental workplace and their readiness or disposition in partaking in this valuable service.

METHODS

This was a cross-sectional, descriptive study that assessed dental patients' knowledge, attitudes and practices regarding VCT services as part of HIV management in the dental setting. The study sample was drawn from the private and public sectors in eThekweni district. The study sites included private dental practices (n=60) and public health institutions (n=8) in eThekweni district. Purposive sampling technique was used to select dental patients. A total of 250 questionnaires were distributed to the identified study sites.

The research instrument comprised a self-administered questionnaire which was validated by means of a pilot study which included (n=5) dental patients from eThekweni to clarify any ambiguity in the questions posed. The questionnaire included 22 items. The first part of the questionnaire focused on information such as gender, age group, level of education, employment status, monthly income and place of living. The second part included questions pertaining to practices such as frequency of dental visits, type of dental treatment undergone, referral for HIV testing, HIV testing undergone in lifetime, location of HIV testing and reason for preferred choice, HIV testing and counselling satisfaction, cost factor regarding HIV testing at the dental workplace and knowledge of rapid HIV testing. The third part of the questionnaire included questions related to dental patients' attitudes and perceptions regarding extension of routine rapid HIV testing at the dental workplace. A Likert 5-scale format of responses was used: strongly agree (=1), agree (=2), not sure (=3), disagree (=4) and strongly disagree (=5) to elicit respondents' attitudes related to fear and stigmatisation, costing, skills and training of oral health care workers conducting the HIV testing, convenience factor, seeking prompt medical assistance and confidentiality of results. The questionnaire consisted of closed-ended questions.

Ethical clearance was obtained from the [information redacted to maintain the integrity of the review process]. Participation was voluntary and written informed consent was obtained from all participants. The questionnaire was administered in English and isiZulu. Confidentiality and anonymity were maintained. For data collection, the researcher first contacted the research sites and gatekeeper permission was obtained. A meeting was then set up with interested people and the informed consent document and the questionnaire were handed out to those who expressed interest in participating in the study.

Table 1. Relationship between biographical data and option to test for HIV at the dentist

Biographical data		Number of participants (n)	Would you like to have the option to test for HIV at the dentist?		P-value
			Yes	No	
Gender	Male	117	96 (82.1%)	21 (17.9%)	0.535
	Female	133	113 (85.0%)	20 (15.0%)	
Age group	18-28 years	87	73 (83.9%)	14 (16.1%)	0.745
	29-34 years	49	39 (79.6%)	10 (20.4%)	
	35-40 years	58	48 (82.8%)	10 (17.2%)	
	41 > years	56	49 (87.5%)	7 (12.5%)	
Level of education	Below grade 9	24	21 (87.5%)	3 (12.5%)	0.922
	Grade 9	38	32 (84.2%)	6 (15.8%)	
	Matric	94	79 (84.0%)	15 (16.0%)	
	Tertiary qualification	94	77 (81.9%)	17 (18.1%)	
Employment status	Employed	150	122 (81.3%)	28 (18.7%)	0.038*
	Unemployed	68	57 (83.8%)	11 (16.2%)	
	Student	20	19 (95.0%)	1 (5.0%)	
	Pensioner	12	11 (91.7%)	1 (8.3%)	
Area of residence	Urban	190	163 (85.8%)	27 (14.2%)	0.000*
	Rural	45	39 (86.7%)	6 (14.6%)	
	Informal dwelling	15	7 (46.7%)	8 (53.3%)	

*statistically significant $p < 0.05$

The researcher also left the informed consent document and questionnaire with the practice manager (in the case of private dental practices) or with the dental manager (in the public dental clinics) to hand over to interested patients presenting for dental management. The researcher reiterated the voluntary nature of the study to these identified people. The researcher then made arrangements to collect the completed questionnaires. A follow-up visit was conducted after one month to retrieve any outstanding completed questionnaires.

Data was analysed using SPSS version 24.0 (IBM Corp, USA). Univariate descriptive statistics such as frequency and mean distribution were conducted for all variables. The responses to the open-ended questions were grouped and emergent themes were examined and compared for possible associations. Inferential techniques included Pearsons chi-squared test to assess a possible relationship between the independent variables (gender, age) and the dependent variables (perspectives on rapid HIV testing services in the dental workplace). A p-value <0.05 was considered to be statistically significant.

Results

Two hundred and fifty (n=250) completed questionnaires were retrieved from dental patients, yielding a response rate of 100%. Dental patients' biographical data and the option to test for HIV in the dental workplace are tabulated in Table 1. Overall, the majority of the participants (n=87; 34.8%) were within the age group 18-28 years old with the lowest age representative within the age distribution of 29-34 years old (n=49; 19.6%). An equal number of participants (n=94; 37.6%) indicated to have obtained matric and tertiary education qualifications. Thirty eight (15.2%) participants reported to have grade 9 level of education, while the minority of participants (n=24; 9.6%) indicated to have below grade 9 education qualification.

Statistical significance was observed with respect to participants' employment status (p<0.05). More than half of the participants indicated to be employed (n=150; 60%), while 27.2% (n= 68) reported to be unemployed. It was found that 8% (n=20) of the participants were students while 4.8% (n=12) were pensioners. The majority of the

participants (n=80; 32%) earn less than R2000 a month, while (n=36; 14.4%) of the participants declined disclosing their monthly income. Among the group of participants who declined to disclose their monthly income, more than half (n=146; 58.4%) were unemployed, 11.2% (n=28) pensioners and 30.8% (n=77) students. The majority of the participants live in urban areas (n=190; 76%), 18% (n=45) live in rural areas, while very few of the participants (n=15; 6%) live in informal dwelling areas.

Relationship between biographical data and option to test for HIV at the dentist

There were no statistical significant differences with respect to gender, age group and level of education of the participants and the option to test for HIV at the dental workplace (p>0.05). Statistical significance was noted with regard to employment status and the area of residence of the participants (p<0.001). More participants from urban (n=165; 85.6%) and rural (n=39; 86.7%) areas were keen on the option to test for HIV at the dental workplace; however, only (n=7; 46.7%) of the informal dwellers shared the same sentiment.

Knowledge of rapid HIV testing

More than half of the participants (n=134; 53.6%) indicated to not have heard of rapid HIV testing and the majority were "unsure" of their knowledge regarding rapid HIV testing (Table 2).

Previous HIV test done

The majority of participants (n=180; 72%) reported to have previously tested for HIV and participants (n=157; 62.8%) have indicated to have received counselling and support from healthcare workers. Of these participants, the majority (n=220; 88%) were satisfied with the counselling they had received.

HIV testing location

The general hospital (n=95; 38%) was reported to be the highest frequented testing location, followed by public dental department in hospital (n=68; 27.2%), public dental department in clinic (n=40; 16%) and general medical practitioner (n=26; 10.4%) (Figure 1). Private dental

Table 2. Knowledge of rapid HIV testing

Questions	Total number of participants (n)	Knowledge (n/%)			P-value
		Yes	No	Unsure	
Cheaper than the conventional testing?	250	84/33.6	20/8	146/58.4	0.000*
Quicker than the conventional testing?	250	107/42.8	17/6.8	126/50.4	0.000*
Less invasive?	250	46/18.4	18/7.2	186/74.4	0.000*
Useful in areas with minimal infrastructure?	250	45/18	19/7.6	186/74.4	0.000*
As accurate as ELISA and Western blot?	250	22/8.8	21/8.4	207/82.8	0.000*

*statistically significant p<0.05

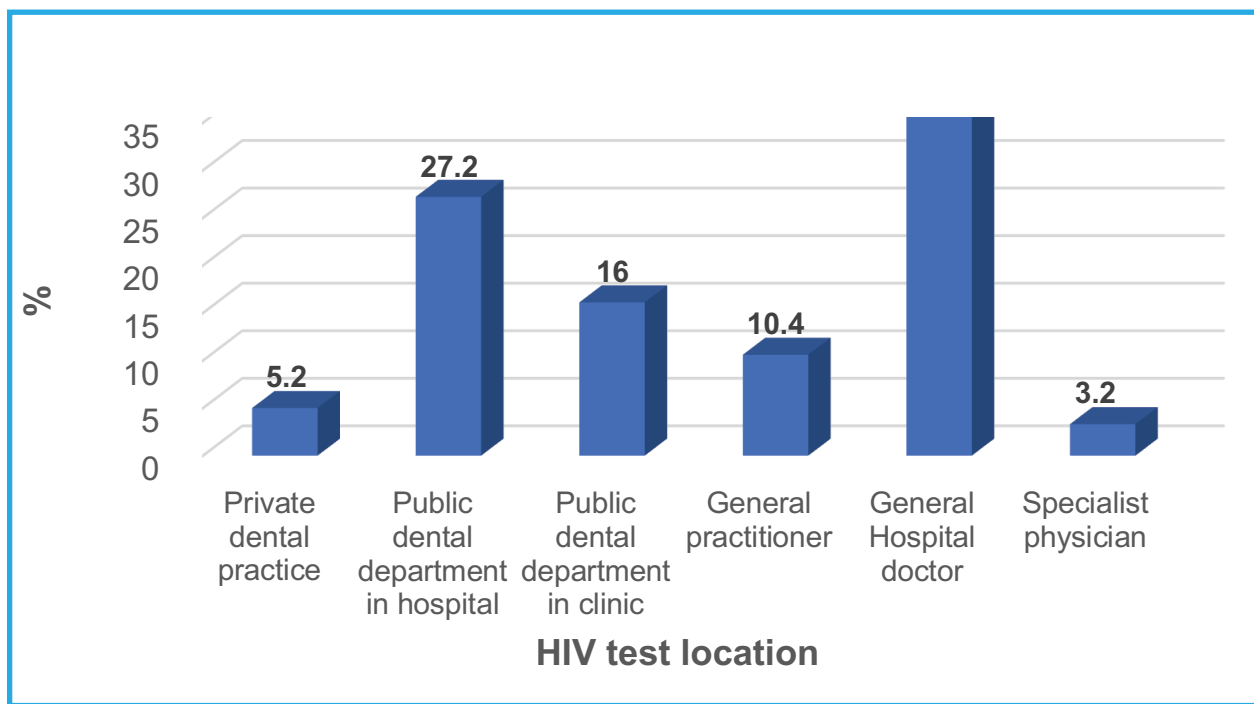


Figure 1. HIV testing locations

practices (n=13; 5.2%) as well as specialist physician (n=8; 3.2%) recorded the lowest frequented HIV testing centres.

Reasons for preferred HIV testing location

The majority of participants (n=126; 50.4%) indicated that the choice of HIV testing location was primarily influenced by proximity to their place of living (Table 3). Reasons for participants' preferred choice of HIV testing location included: accuracy of conduction of HIV test (n=70; 28%), trust staff to conduct the test effectively and efficiently (n=66; 26.4%), negligible cost of HIV test (n=60; 24%) and familiar HIV testing location (n=58; 23.2%).

Option to test at the dental workplace

The majority of participants (n=209; 83.6%) indicated to want the option to test for HIV at the dental workplace. Furthermore, the majority of participants (n=204; 81.6%) reported that extending HIV testing to the dental workplace is a good idea.

Potential dental HIV testing location

The majority of participants (n=205; 82%) indicated to be willing to undergo a rapid HIV test at the dental workplace.

The minority of participants (n=45; 18.0%) were not keen to be tested at the dental workplace and indicated that the general hospital (n=133; 53.2%) was their preferred HIV testing location.

Cost factor

It was reported that the majority of participants (n=205; 82%) were willing to undergo a rapid HIV test at the dental workplace, provided HIV testing was fully subsidised by the government or medical aid schemes.

Participant response regarding rapid HIV testing in the dental workplace

The majority of participants (n=192; 76.8%) indicated that routine testing for HIV should be conducted by the dentist, as the dental workplace is a convenient location. The majority of the participants (n=206; 82.4%) reported to support the idea of HIV testing at the dental workplace, as a means of seeking medical treatment sooner, if necessary. The majority of participants (n=152; 60.8%) indicated that the fear and perceived rejection by the dentist following a positive HIV test result would not discourage them from testing at the dental workplace. Furthermore, 62.4%

Table 3. Reasons for preferred HIV testing location

Reason for having HIV test done at chosen location	Total number of participants (n)	Value (n/%)	
		Agree	Disagree
It is close to my house so I do not have to travel far	250	126/50.4%	124/24.6%
I do not mind where I get tested, as long as it is done accurately	250	70/28%	180/72%
I trust the staff to carry out the test effectively and efficiently	250	66/26.4%	184/73.6%
It is free or inexpensive to do the test at this place	250	60/24%	190/76%
I have always tested at this place	250	58/23.2%	192/76.8%

(n=156) of participants reported to not feel ashamed or stigmatised against following a positive HIV test result at the dental workplace. More than half of the participants (n=142; 56.8%), indicated to trust the oral healthcare worker to keep the results of the HIV test confidential.

Conversely, many participants (n=189; 75.6%) were not willing to participate in HIV testing at the dental workplace should they be financially liable. Nearly half of the participants (n= 104; 41.6%) reported to feel that oral healthcare workers are not trained to test and counsel and therefore would not partake in HIV testing at the dental workplace.

Frequency of visits to the dental workplace

More than half of the participants (n=130; 52%) had visited the dental workplace less than 2 times within the past year, while n=99 participants (39.6%) visited between 2 to 5 times and few participants (n=21; 8.4%) visited more than 5 times. Overall, less than half of the participants (n=120; 48%) have visited the dental workplace more than twice within the past year.

Type of dental treatment undergone

The majority of participants (n=169; 67.6%) reported having an extraction within the past year (Table 4).

Referral for HIV test

The majority of the participants (n=212; 84.8%) indicated that they have never been referred for an HIV test by an oral healthcare worker.

DISCUSSION

The study findings indicated that half of the study population (n=136; 54.4%) were within the age group 18-34 years. Only a third of the study population (n=94; 37.6%) reported having matric and tertiary education qualifications while 60% (n=150) of respondents were employed. The relationship between employment status and area of residence was seen as being statistically significant in terms of testing for HIV at the dental workplace. The study findings also indicated that about 54% (n=134) of the study population were unaware of rapid HIV testing, while more than two-thirds of the study population reported having being tested previously for HIV (n=180; 72%). This finding is consistent with a previous study which reported a relationship between participants' monthly income and HIV/AIDS knowledge scores.¹⁴ The authors reported that a higher monthly income was associated with higher HIV/AIDS knowledge and that this collectively resulted in higher testing rates.¹⁴ Similarly, Lopez-Quintero et al. reported that patients' HIV knowledge was linked to previous exposure to HIV testing.¹⁵ This reiterates the importance of HIV/AIDS-related dental education especially in areas of high infection rates. The

study findings are consistent with Joshi et al. who reported no difference between study participants' educational status and "their willingness to undergo HIV test as a part of [the] dental visit".¹⁶

The majority of study participants (n=126; 50.4%) reported using the public health facility and that this selection of HIV testing location was mainly due to easy access. Given the dependency on public health services in eThekweni district, as with the rest of the country, it is not surprising that participants also opted to access health services that are closest to them. This finding is consistent with other studies that highlight the need to increase access to improve uptake of HIV testing.¹⁷⁻¹⁸ Such strategies could include increased availability of HIV self-testing (HIVST) and community HIV testing (home-based testing).¹⁷ This further reiterates the importance of ensuring not only the availability and access of HIV testing services, but also ensuring the optimal utilisation of such services.

The majority of participants in this study (n=209; 83.6%) indicated that HIV testing should be made available in the dental setting. This finding is supported by other studies which also reported a high patient acceptance of HIV testing in the dental environment.¹⁹⁻²¹ Parish et al. further reported that patients who accessed other medical screenings in the dental environment were more likely to accept HIV testing in these settings.¹⁹ Similarly, Rosso et. al. reported that patient acceptability of HIV testing in the dental setting was influenced by a "positive patient-provider relationship".²² This suggests that the trust that exists between the practitioner and patient is an important consideration for HIV testing services. This highlights the need for a paradigm shift in oral healthcare, where dental practitioners become more involved in the provision of other health screenings in addition to oral health services. This, however, will require a review of the undergraduate curriculum and to ensure that interprofessional education is adequately covered so that the dental graduate is better prepared to work in interdisciplinary and multidisciplinary health settings.

It is equally important to explore dental practitioners' attitudes and beliefs regarding HIV testing services as part of dental clinical management. It is noteworthy that [information redacted to maintain the integrity of the review process] reported in an earlier study that oral health practitioners in their study had inadequate knowledge related to VCT but that they had positive attitudes towards the implementation of such services provided that there was adequate support and training available.¹³ Some participants in this study also expressed concern with the financial burden of such tests as well as the dentists' competence to conduct the tests. A point worth highlighting is that nearly half (43.3%) of the participants who had previously tested for HIV, were

Table 4. Type of treatment undergone at dental workplace

Type of treatment	Total number of participants (n)	Value (n/%)	
		Yes (n)	%
Extraction of tooth	250	169	67.6
Check up and clean	250	80	32
Fillings	250	53	21.2
Other	250	19	7.6

tested in a public dental department (clinic and hospital). This suggested that the costs of HIV testing in private dental settings could be a barrier if patients are expected to bear such a financial burden.

The cost of HIV testing in the dental settings is an important consideration and more research is needed in this area to ascertain the responsible parties to bear the associated financial costs. This also requires ongoing advocacy and collaborative partnerships between the Department of Health, medical aid schemes, patients and oral health practitioners (in the public and private health sectors) to ensure that the offering of such services are not thwarted by a lack of clear roles and responsibilities of each player or stakeholder. It is thus important that memoranda of agreements are set up to clearly define the roles and responsibilities of each player as well as the responsible persons for bearing the financial costs of such services.

Strengths and limitations of the study

The study provided valuable insights into patients' knowledge, attitudes and experiences related to HIV testing. However, several limitations were noted. The study was only conducted in one district in KwaZulu-Natal, hence its generalisability is limited to the eThekweni district. The majority of study participants were located in the urban areas. Given the inconsistent availability of oral health services in the rural areas of KwaZulu-Natal, it is possible that participants from such areas could have a different perspective with regard to HIV testing in the dental setting.

CONCLUSION

The study findings indicated that study participants had inadequate knowledge but positive attitudes towards VCT implementation in the dental setting, provided that the cost of conducting of the test was free. More research needs to be conducted in other parts of the province and in South Africa to ascertain public opinion on HIV testing and VCT implementation in the dental settings. Such information could add value to policy review related to increasing access to HIV testing services in the country.

REFERENCES

1. Allinder SM, Fleischman J. The world's largest HIV epidemic crisis: HIV in South Africa. 2019. Available from: <https://www.csis.org/analysis/worlds-largest-hiv-epidemic-crisis-hiv-south-africa>

2. Ramjee G, Sartorius B, Morris N et al. A decade of sustained geographic spread of HIV infections among women in Durban, South Africa. *BMC Infect Dis* 19, 500 (2019). <https://doi.org/10.1186/s12879-019-4080-6>
3. Cichocki M. History of HIV in South Africa. Available from: <https://www.verywellhealth.com/hiv-around-the-world-south-africa-48673>
4. UNAIDS. 90-90-90: Treatment for all. 2020. Available from: <https://www.unaids.org/en/resources/909090>
5. HSRC. Annual Report 2017/2018. Available from: <chrome-extension://efaidnbmnnnibpcajpcglclefindmkaj/https://hsrc.ac.za/wp-content/uploads/2022/07/HSRC-AR-2018.pdf>
6. Cornett JK, Kirm TJ. Laboratory diagnosis of HIV in adults: a review of current methods. *Clin Infect Dis*. 2013 Sep;57(5):712-8. doi: 10.1093/cid/cit281. Epub 2013 May 10
7. van Wyk BE, Davids LC. Challenges to HIV treatment adherence amongst adolescents in a low socio-economic setting in Cape Town. *South Afr J HIV Med*. 2019 Oct 28;20(1):1002. doi: 10.4102/sajhivmed.v20i1.1002
8. National Department of Health of South Africa. National HIV Testing Services Policy: 2016. 2015:23. Available at: <https://knowledgehub.health.gov.za/elibrary/national-hiv-testing-services-policy>
9. Hutchinson MK, Van Devanter N, Phelan J, Malamud D, Verrillo A, Combellick J, Shelley D. Feasibility of implementing rapid oral fluid HIV testing in an urban University Dental Clinic: a qualitative study. *BMC Oral Health*. 2012 May 9;12:11. doi: 10.1186/1472-6831-12-11
10. Abe E, Kolude B, Adeyemi B. HIV testing in dental practice: perception and attitude of dentists in Southwestern Nigeria. *African Journal of Medicine and Medical Sciences*, 2014; 43(Suppl 1), pp. 201-208. doi: 10.1016/j.coviro.2015.09.001
11. Pollack HA, Pereyra M, Parish CL, Abel S, Messinger S, Singer R, Kunzel C, Greenberg B, Gerbert B, Glick M, Metsch LR. Dentists' willingness to provide expanded HIV screening in oral health care settings: results from a nationally representative survey. *Am J Public Health*. 2014 May;104(5):872-80. doi: 10.2105/AJPH.2013.301700
12. Santella AJ, Conway DI, Watt RG. The potential role of dentists in HIV screening. *Br Dent J*. 2016 Mar 11;220(5):229-33. doi: 10.1038/sj.bdj.2016.172. PMID: 26964593
13. [Information redacted to maintain the integrity of the review process].
14. Gao B, Wang L, Santella AJ, Zhuang G, Huang R, Xu B, et al. (2021) HIV testing behaviors and willingness to receive oral rapid HIV testing among dental patients in Xi'an, China. *PLoS ONE* 16(3): e0248585. <https://doi.org/10.1371/journal.pone.0248585>
15. Lopez-Quintero C, Rojas P, Dillon FR, Varga LM, De La Rosa M. HIV testing practices among Latina women at risk of getting infected: a five-year follow-up of a community sample in South Florida. *AIDS care*. 2016; 28(2):137-46. <https://doi.org/10.1080/09540121.2015.1071769>
16. Joshi V, Joshi NK, Bajaj K. Patient's knowledge about HIV and willingness toward rapid HIV oral testing in dental settings, Jodhpur, Rajasthan. *Int J Community Med Public Health*. 2018 Dec;5(12):5349-5354
17. Jooste S, Mabaso M, Taylor M, North A, Shean Y, Simbayi LC, Reddy T, Mwandangi L, Schmidt T, Nevhungoni P, Manda S, Zuma K. Geographical variation in HIV testing in South Africa: Evidence from the 2017 national household HIV survey. *South Afr J HIV Med*. 2021 Aug 31;22(1):1273. <https://doi.org/10.4102%2Fsajhivmed.v22i1.1273>
18. Brondani M, Chang S, Donnelly L. Assessing patients' attitudes to opt-out HIV rapid screening in community dental clinics: a cross-sectional Canadian experience. *BMC Res Notes*. 2016 May 10;9:264. doi: 10.1186/s13104-016-2067-6
19. Parish CL, Pereyra MR, Yanez IG, Vidot DC, Metsch LR. Patient acceptance of HIV rapid testing in the dental care setting. *AIDS Care*, 2023, 35(5):745-752. <https://doi.org/10.1080/09540121.2022.2073326>
20. Van Devanter N, Combellick J, Hutchinson MK, Phelan J, Malamud D, Shelley D. A Qualitative Study of Patients' Attitudes toward HIV Testing in the Dental Setting. *Nurs Res Pract*. 2012;2012:803169. <https://doi.org/10.1155/2012/803169>
21. Bradley ELP, Vidot DC, Gaul Z, Sutton MY, Pereyra M. (2018). Acceptability of oral rapid HIV testing at dental clinics in communities with high HIV prevalence in South Florida. *PLoS ONE* 13 (4): e0196323. <https://doi.org/10.1371/journal.pone.0196323>
22. Rosso MT, Sharma A. Willingness of Adults in the United States to Receive HIV Testing in Dental Care Settings: Cross-Sectional Web-Based Study. *JMIR Public Health Surveill*. 2020 Jul 21;6(3):e17677. doi: 10.2196/17677

CPD questionnaire on page 120

The Continuing Professional Development (CPD) section provides for twenty general questions and five ethics questions. The section provides members with a valuable source of CPD points whilst also achieving the objective of CPD, to assure continuing education. The importance of continuing professional development should not be underestimated, it is a career-long obligation for practicing professionals.



Root and canal morphology of the maxillary first molar: A micro-computed tomography-focused observation of literature with illustrative cases.

Part 2: Internal root morphology

SADJ March 2024, Vol. 79 No.2 p75-85

CH Jonker,¹ PJ van der Vyver,² AC Oettlé³

ABSTRACT

The complexity of root canal morphology can influence cleaning and shaping of the root canal system and, ultimately, treatment outcomes. Undiscovered root canal morphology can greatly reduce the prognosis of endodontic treatment due to the preservation of offending organisms and their by-products. The maxillary first molar has been identified as one of the most challenging teeth to treat endodontically due to its complex internal anatomy, the presence of additional and accessory canals and intricate root canal configurations. This paper is the second of two that provide a micro-computed tomography (micro-CT)-focused overview of available literature on various aspects of the root and canal morphology of the maxillary first permanent molar. The aim of this paper is to provide an overview of relevant aspects of the internal root morphology in different populations. The content is supported by illustrative micro-CT images and clinical cases or images.

Keywords

Accessory canals, apical deltas, chamber canals, MB2, MB3, micro-CT, root canals, root canal configurations

Introduction

Root canal treatment implies the removal of irreversibly inflamed or infected tissues from the root canal system using mechanical and chemical disinfection techniques.^{1,2} Cleaning and shaping the root canal are profoundly affected by the complexity of root canal morphology. Unsuspected root canal morphology may lead to the preservation of offending organisms and their by-products, which can cause treatment to fail.² The morphological complexity of the human molar, in particular, often leads to root canal anatomy being missed in the diagnostic phase, perforations and fractured instruments in the preparation phase and incomplete disinfection and removal of necrotic or inflamed tissues in the chemical phase.^{3,4} Root canals per tooth, root canal configurations, and frequency of isthmi and apical deltas in mandibular first permanent molars in an Indian population. Hundred and fifty mandibular first permanent molars were collected and subjected to clearing technique. The cleared teeth were examined in a stereomicroscope under 7.5x magnifications. The canal configurations were categorized using Vertucci's classification. Overall 94.6% of the mandibular first molars had two roots, and 5.3% had extradistal roots (distolingual root). Maxillary molars can have a number of canals which are often challenging to locate without specialised equipment and proper magnification.^{2,5-9}

The maxillary first molar has been identified as one of the most arduous teeth to treat endodontically because of its complex internal anatomy and the presence of additional canals.^{5,7} One of these additional canals is a second mesiobuccal canal (MB2) located in the mesiobuccal root (MB).^{6,8-11} and evaluate if there were any significant differences between initial treatments and retreatments. The teeth examined were 3578 first molars and 2038 second molars treated consecutively over a 5-yr period by six endodontists. Overall the MB2 canal was found in 2133 (60%). The second mesiobuccal canal is often hidden by dentine ledges and sclerotic tooth structure, which makes it difficult to discover and treat and, unfortunately, it is often missed.^{12,13} Figures 1-3 show the suggested clinical procedure to remove the covering dentine ledge to discover the MB2 canal system on maxillary molars.

Authors' information

1. Dr Casper H Jonker, BChD, Dip Odont (Endo), MSc (Endo), PG Cert (ClinEd), AFHEA, PhD student in Anatomy (University of Pretoria), Faculty of Health, Peninsula Dental School, University of Plymouth Ground, Truro Dental Education Facility, Knowledge Spa, Royal Cornwall Hospital, Truro, UK.
ORCID: 0000-0002-9110-5208
2. Prof Peet J van der Vyver, BChD, PG Dip Dent (Endo), PG Dip Dent (Aesthet Dent), MSc, PhD, Department of Odontology, School of Dentistry, School of Health Sciences, University of Pretoria, Pretoria 0031, South Africa
ORCID: 0000-0003-1951-6042
3. Prof Anna C Oettlé, MBBCh, DTE, MSc, PhD, Department of Anatomy and Histology, School of Medicine, Sefako Makgatho Health Sciences University, Pretoria, South Africa
ORCID: 0000-0002-9389-057X

Corresponding author

Name: Dr CH Jonker
Email: casper.jonker@plymouth.ac.uk
Tel: +44 1872 258104

Author's contribution

1. Casper H Jonker: Principal author, manuscript layout and write-up – 60%
2. Peet J van der Vyver: Treated patients and clinical images, manuscript layout and proofreading – 25%
3. Anna C Oettlé: Proofreading and layout – 15%

Acknowledgements

The corresponding author would like to extend his gratitude towards Dr Charlotte Theye for the technical support in the preparation of the manuscript.

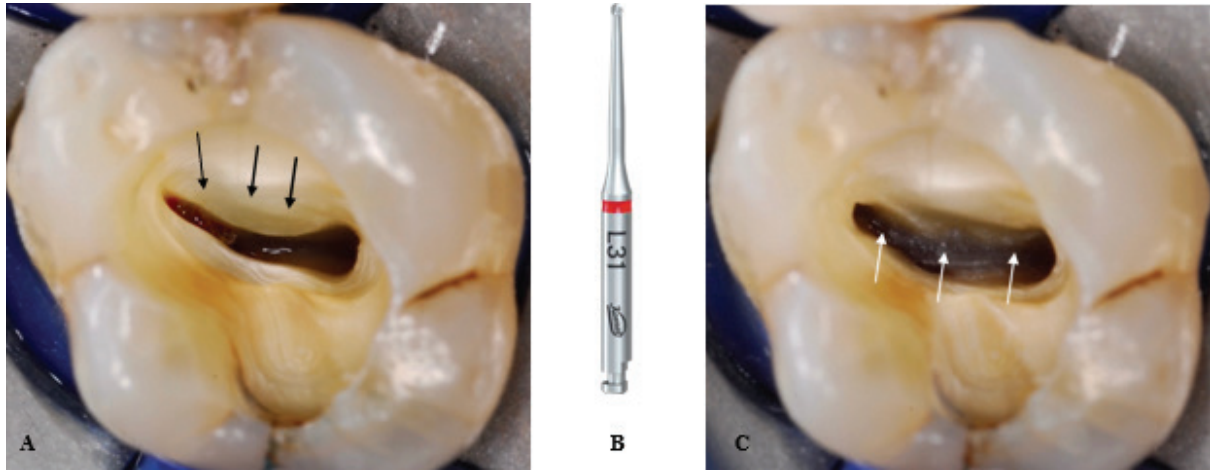


Figure 1: Access preparation and suggested instrumentation for dentine removal on a maxillary first molar; **(A)** Access cavity preparation on a left maxillary first molar after removal of a leaking amalgam restoration that resulted in secondary decay. Note the dentine ledge (black arrows) restricting the access into the MB canal and obscuring the canal orifice of the possible MB2 canal; **(B)** A size 010 EndoTracer bur (Komet) was used at a speed of 1500rpm under microscope magnification to remove the coronal aspect of the dentine ledge; **(C)** Dentine ledge removed until a smooth transition from pulp floor to root canal walls is visible.

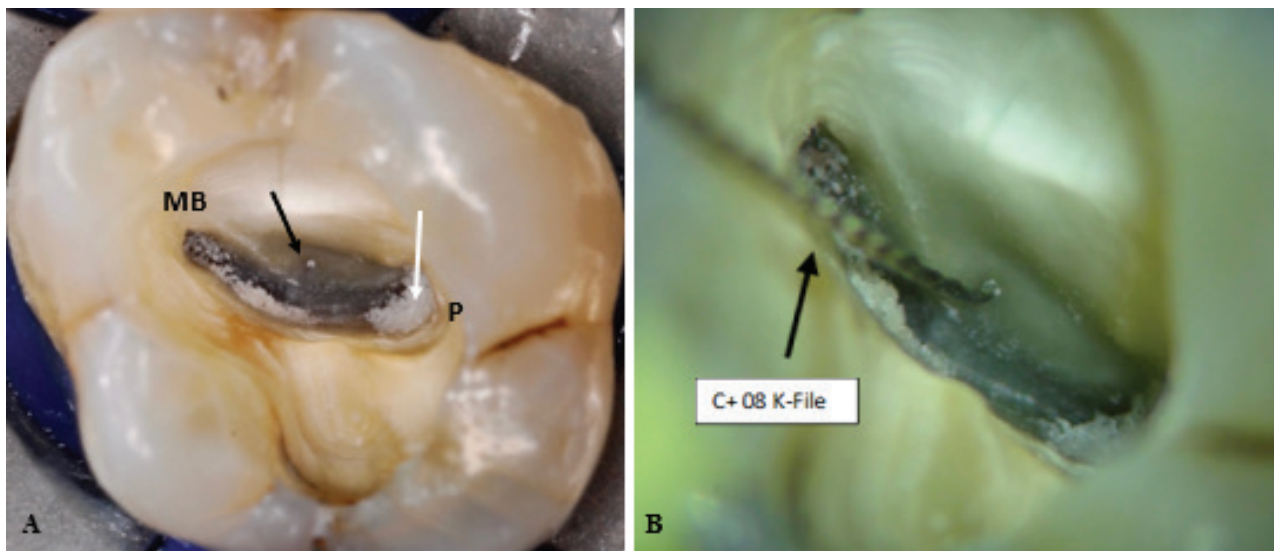


Figure 2: Identification and negotiation of the MB2 canal; **(A)** Improved access was obtained to the pulp floor revealing a groove (black arrow) running from the MB canal towards the palatal (P) canal orifice. A smaller size 008 EndoTracer bur (Komet) was used to through approximately 1.5mm deeper on the groove resulting in the appearance of the debris accumulation (white arrow) in the in MB2 canal orifice; **(B)** Size 08 C+ file (Dentsply Sirona) was used to start negotiation of the MB2 canal.

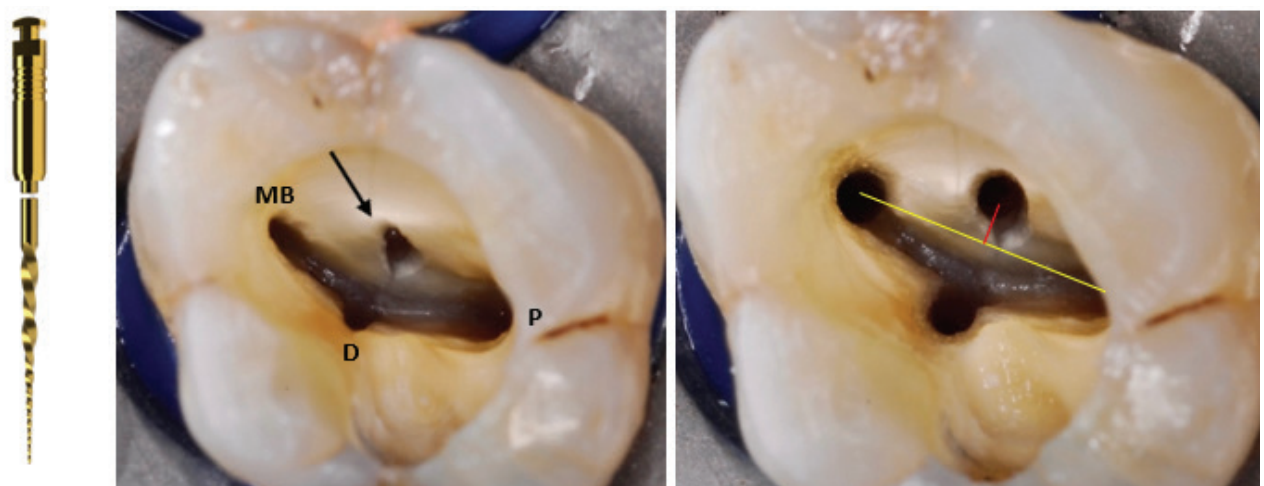


Figure 3: Cleaning and shaping the root canal system; **(A)** ProTaper Ultimate Orifice Opener (Dentsply Sirona) was used in a backstroke brushing motion to relocate the canal orifice in a more mesial direction to allow for easier canal negotiation; **(B)** Pulp chamber view after all the canal orifices were opened with the ProTaper Ultimate Orifice Modifier (Dentsply Sirona). Note the mesial relocation of the position of the MB2 canal orifice (arrow); **(C)** Pulp chamber view after all the canals were prepared up to size F2 ProTaper Ultimate (25/07) (Dentsply Sirona). Note the final position of the MB2 canal orifice is approximately 1.5mm-2mm more mesial from a line drawn from the MB and the P canal orifices.

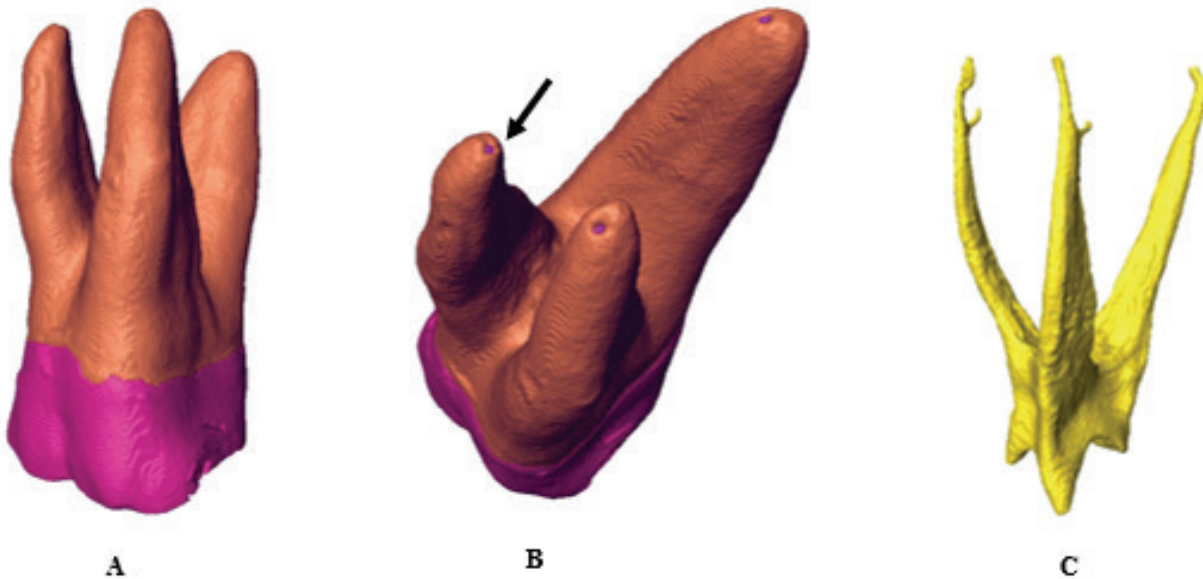


Figure 4: Micro-CT illustration of a typical maxillary first molar with three separate roots using Avizo software; (A) View from MB; (B) Rotation with a view from apical illustrating apical root canal exits and their apical foramen(s) (black arrow); (C) Virtually extracted pulp.

Additional canals can also be present in the other roots and if any of these remain untreated it can greatly influence the long-term survival of a tooth.^{2,5} In addition, root canal configurations in maxillary first molars can be some of the most complex ones in the human dentition.¹⁴ Apart from the main canals, a complex network of accessory canals can be located anywhere along each root canal.^{15,16} Main canals can also terminate in apical deltas and the pulp floor can contain chamber canals with the potential to connect the pulpal space with the furcation region of a tooth.^{2,17}

Many of the complexities and anatomical variations of the roots and canals of molar teeth could not be seen using conventional two-dimensional radiographs.¹⁸ The introduction of micro-computed tomography (micro-CT) provided a non-invasive way to explore the morphology of roots and canal systems with accuracy and confidence.¹⁹ Interestingly, the original use of micro-CT was not for dentistry but for industry.²⁰ Nielsen et al¹⁹ were the first authors to use this technology to describe the internal and external root and canal anatomy of a maxillary first molar. It has since

become the gold standard for morphological investigations and the most suitable method to study complex root canal morphologies to visualise fine detail.^{21,22} In addition, modern software (for example Avizo²³) can allocate different colours to enamel, dentine and the pulp for differentiation and each component can be virtually extracted (by labelling and segmentation), magnified and rotated (Figure 4).²³⁻²⁵

The aim of this paper is to provide an overview of available literature on clinically relevant aspects of the internal morphology of the maxillary first molars supported by illustrative clinical cases and micro-CT images. Authors have used different investigative techniques when studying root and canal morphology in different populations. The findings on various techniques are discussed in this paper, but special consideration is given to studies where micro-CT was used.

The second mesiobuccal canal (MB2)

Versiani, Sousa-Neto and Basrani¹⁴ conclude that the presence of a second canal in the MB root is on average

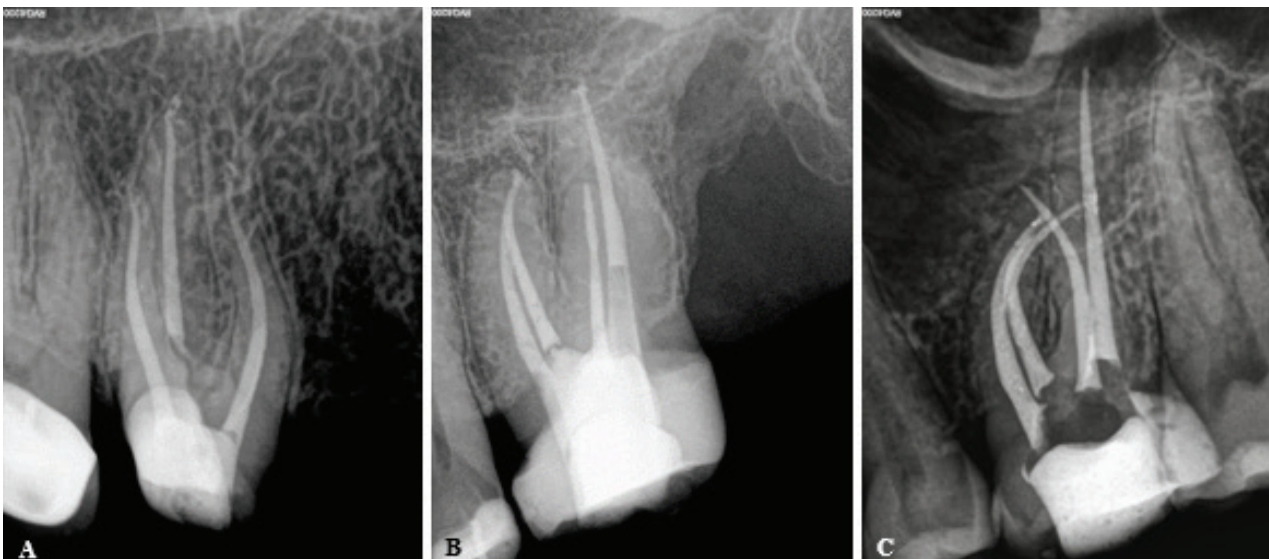


Figure 5: Different root canal configurations that may be present in maxillary first molars; (A) Right maxillary first molar that presented with only one MB canal; (B) Left maxillary first molar that presented with an MB and MB2 canal system that joined in the apical third of the root; (C) Left maxillary first molar that presented with an MB and MB2 canal system that had separate apical foramina in a severely curved MB root.

Table I: Micro-CT studies reporting on MB2.

Author(s)	Year	Population	Number of teeth investigated	Prevalence of MB2 (%)
Park et al. ²⁸	2009	South Korea	46	80.0
Somma et al. ²⁹	2009	Italy	30	80.0
Gu et al. ³⁰	2011	South Korea	110	68.0
Verma and Love ³¹	2011	New Zealand	20	90.0
Yamada et al. ³²	2011	Japan	90	55.5
Hosoya et al. ³³	2012	Japan	86	60.5
Domark et al. ³⁴	2013	USA	13	100
Kim et al. ³⁵	2013	South Korea	154	61.0
Lee et al. ³⁶	2014	South Korea	18	100
Tomaszewska et al. ¹³	2018	Poland	110	64.2
Zurawski et al. ³⁷	2018	Brazil	6	95.8
Alfouzan et al. ³⁸	2019	Saudi Arabia	35	80.0
Camargo Dos Santos et al. ³⁹	2020	Brazil	96	87.5
Tonelli et al. ⁴⁰	2021	Brazil	90	69.4

60.4%. Prevalence, however, can vary between populations. In a recent worldwide cone-beam computed tomography (CBCT) observation involving 21 regions, the average prevalence was 73.8% – ranging between 48% (Venezuela) and 97.6% (Belgium).¹⁰ In a Nigerian study, a group of authors used laboratory sectioning and direct observation on extracted first molars of unspecified individuals and an in vivo clinical investigation using radiographs of symptomatic patients. More MB2 canals were identified using the laboratory and direct observational technique (23%) than with the in vivo clinical observation (3%) in this study.²⁶ In a worldwide investigation, a prevalence of 62% was reported in Egypt using CBCT.¹⁰ In South Africa, three CBCT studies reported a prevalence of 60.5%, 92% and 95.6% respectively,^{10,11,27} age, side, and root configuration using in vivo cone-beam computed tomographic (CBCT) but the population groups or backgrounds of the individuals were not specified in either study. In micro-CT-focused studies, authors have reported a prevalence of MB2 ranging from 60.5% to 100% (Table I). Figure 5 depicts three different clinical scenarios that were observed during clinical treatment of South African individuals.

The third mesiobuccal canal (MB3)

The MB root can contain an additional canal located between the MB1 and MB2.⁴¹ Versiani et al.¹⁴ reported an incidence of 0.1%, in all available literature reviewed. However, in the same year (2018) a global incidence of 5% for this type of morphology was reported from 12,200 maxillary first molars.¹³ Focused research on this canal is limited with most findings discussed as case reports or incidental findings. Investigative methodologies also differ: for example, using a clearing and stereomicroscopic technique on extracted teeth, a high incidence of 11.3% was noted in Iranian individuals⁴² while in Africa, using a combination of clearing, dyes and visual observation under magnification on extracted teeth of individuals from African descent, Rwenyoni et al.⁴³ determined that 0.5% of an Ugandan population had an MB3. No studies reporting on the presence of the MB3 in South African individuals were identified but Figures 6 and 7 show the clinical procedure that was followed to locate and treat the MB3 in a maxillary first molar in a South African individual.

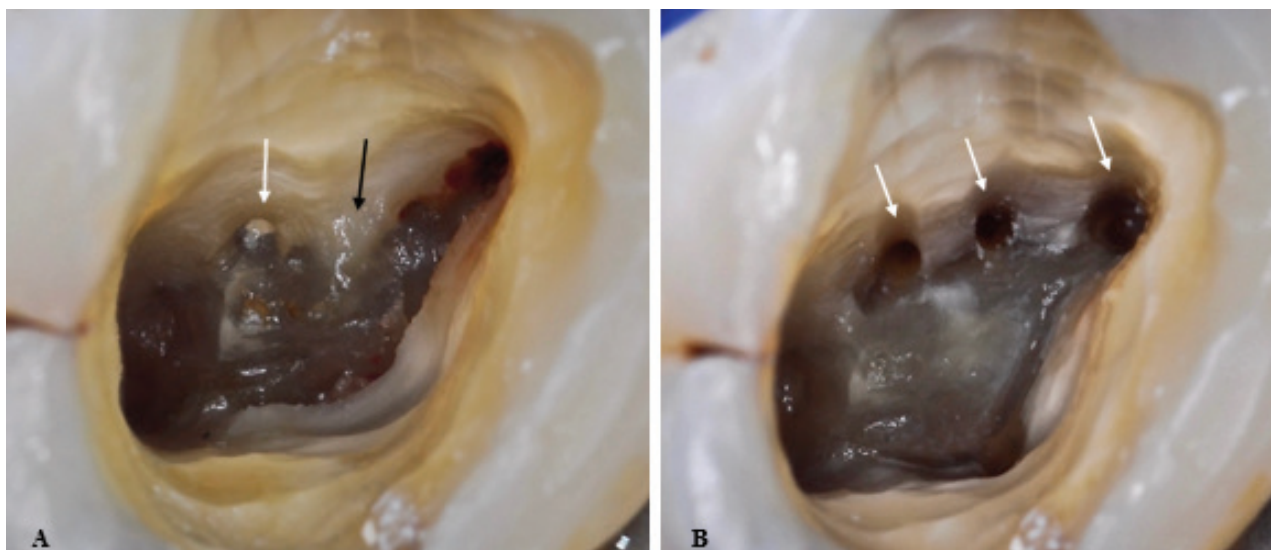


Figure 6: A right maxillary first molar that presented with an MB3 canal; (A) High-magnification view of the pulp chamber floor. Note the evidence of a dentine ledge (black arrow) and necrotic pulp tissue in a canal orifice visible close to the P canal orifice (white arrow); (B) After removal of the dentine ledge with EndoTracer burs (Komet), three MB root canal systems (arrows) were discovered in the MB root.

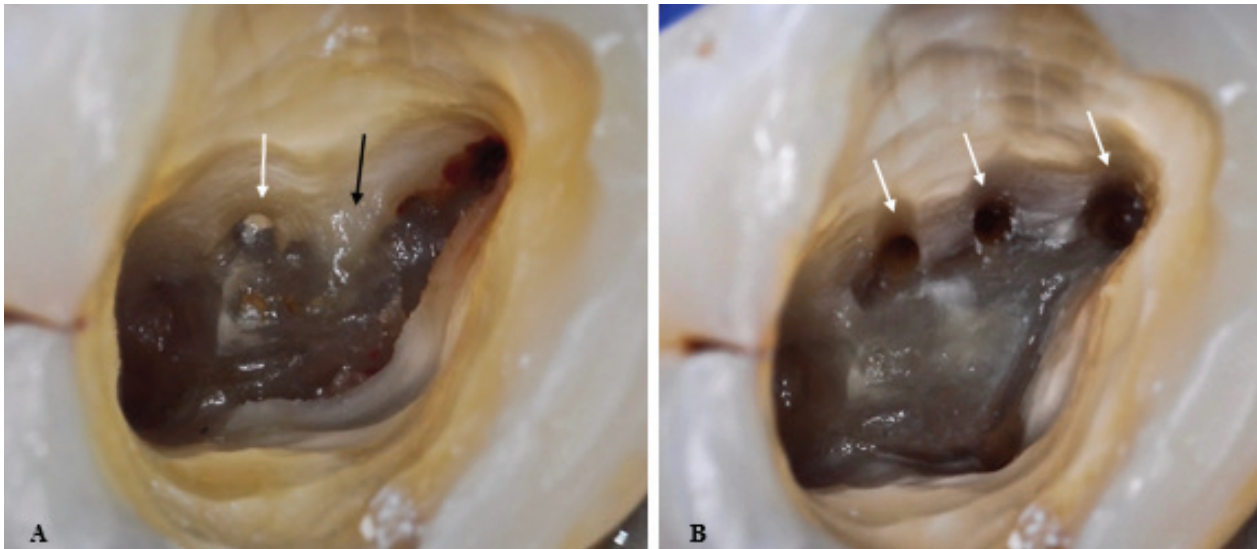


Figure 7: Clinical procedure for cleaning, shaping and obturation of a maxillary first molar with three MB canals; **(A)** Pre-operative periapical radiograph of a non-vital, right maxillary first molar that required root canal treatment; **(B)** High-magnification view of the pulp chamber floor showing the location of three mesiobuccal canal systems in the mesial root after canal preparation with the F2 ProTaper Universal System (Dentsply Sirona); **(C)** Postoperative periapical radiograph after obturation of the five root canal systems. Note that the MB2 and MB3 canals joined in the midroot area to exit in a combined apical foramen next to the MB1 canal, which was a separate system.

Table II. Micro-CT studies identified reporting on MB3.

Author	Year	Population	Sample size	Prevalence (%)
Park et al. ²⁸	2009	Canada (Koreans)	46	6.5
Gu et al. ³⁰	2011	South Korea	110	8.2
Verma and Love ³¹	2011	New Zealand	20	10.0
Kim et al. ³⁵	2013	South Korea	154	12.3
Briseño-Marroquín et al. ²¹	2015	Germany	179	5.0
Alfouzan et al. ³⁸	2019	Saudi Arabia	35	17.1
Camargo et al. ³⁹	2020	Brazil	96	3.1

Micro-CT studies on the MB3 are limited but some have been identified. Ordinola-Zapata et al.⁴¹ report a figure of 10% in a Brazilian subpopulation using micro-CT. Other identified micro-CT studies reporting on this type of morphology in different populations are summarised in Table II.

Additional canals in the DB and P roots

Most of the reports available mentioning additional canals in the DB and P roots used techniques which included clearing and staining, traditional radiographs with clinical investigation and CBCT,⁴⁴⁻⁴⁷ and findings ranged between 0 and 9.5% for the DB root and 0 and 4.5% for the P root. A global study reported an incidence of 1.4% and 0.7% of additional canals in the DB and P roots respectively.¹⁴ In a CBCT study, Tian and co-workers⁴⁸ found figures in agreement with the suggested global range; approximately 0.2% of Chinese maxillary first molars had an additional P canal and 0.4% had additional distal (D) canals. In Africa, specifically in Uganda, the researchers did not find any additional canals in the P root but 2.3% of the D roots contained an additional canal.⁴³ Similarly in Nigeria, Abiodun-Solanke et al.²⁶ found an additional P canal in 1% of their sample using visual observation and surgical loupes. No studies could be identified reporting additional canals in the DB or P root in South African individuals. Although South African studies are not available, clinicians have probably treated these challenging root canal morphologies on occasions. Figure 8 shows a clinical case with an additional canal in the P root in a South African individual.

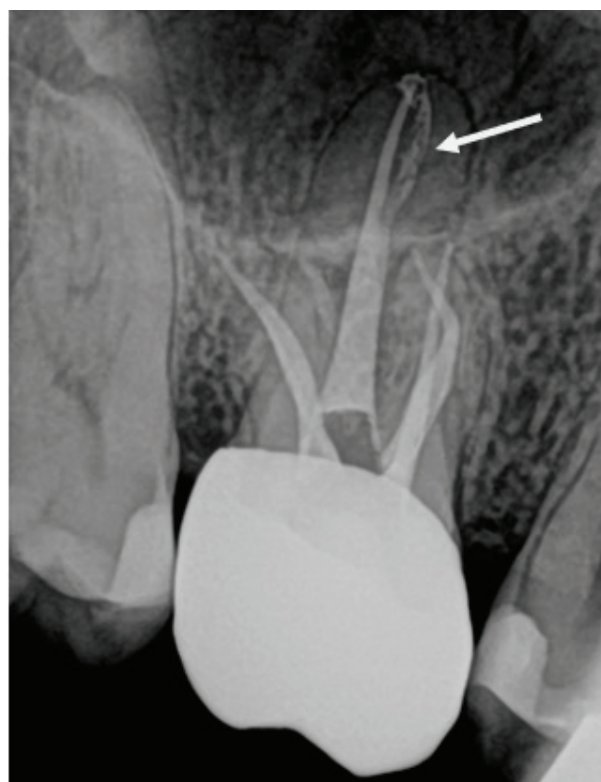


Figure 8: Right maxillary first molar that presented with an additional canal in the P root (white arrow) that bifurcated from the main canal at the midroot level. Note the two separate MB root canal systems in the MB root.

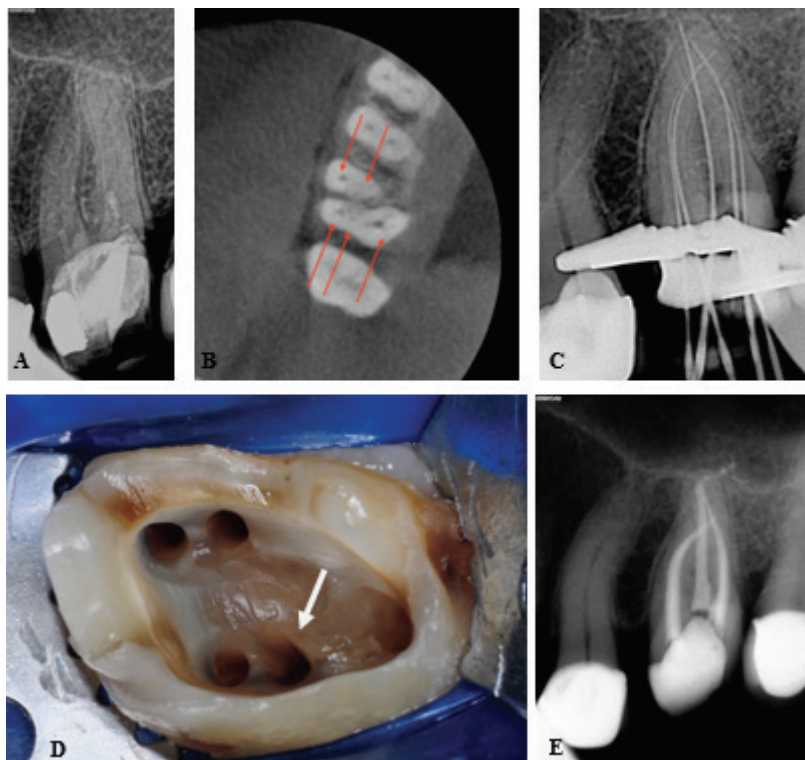


Figure 9: Clinical management of a maxillary first molar with an additional DB canal; (A) Pre-operative periapical radiograph of a left first maxillary molar that presented with an emergency root canal treatment; (B) Axial slice on a CBCT scan revealed the presence of an MB, MB2, P, D and an additional distobuccal (DB) canal system; (C) Periapical radiograph to confirm the working length of the five-root canal systems; (D) High-magnification view of the pulp chamber showing the additional canal in the DB root (white arrow) after canal preparation; (E) Postoperative periapical radiograph after obturation with temporary restoration.

Figure 9 depicts a clinical case where an additional canal was present in the DB root of a South African individual.

Global studies that reported on results on additional D or P canals using micro-CT exclusively are limited and there are none in African populations. Briseno-Marroquin et al.²¹ found an incidence of 1.2% for an additional D canal in a German sample. In a Burmese (Myanmar) study no additional P canals were found, but of the DB root 13.86% contained multiple canals in their sample of 101 first molars.⁴⁹ Matsunaga et al.⁵⁰ also found no additional canals in the P root of a Japanese sample. A later study in Japan focusing on the DB root found that 2% of DB roots had additional canals.

Variants of canal numbers

Apart from the MB2, MB3 or an additional DB or P canal, maxillary first molars may contain more than five canals in total. Variants that deviate from the expected three or four canals in these teeth where investigators used micro-CT exclusively are limited and none was identified in African populations. Teeth with a single canal were reported in 0.06% of a Chinese population using CBCT and a large sample (n=1,558).⁴⁸ Two-canal configurations were found by the same author in 0.8% of the sample. These authors also found 0.5% of teeth with six canals in total, made up of different combinations of MB, DB or P canals. A few reports are available on first molars with six canals. By using radiographic observation and clinical treatment under magnification, Albuquerque and co-workers⁵¹ treated a tooth with complex root canal morphology. Zheng et al.^{46,4,22}}}, "issued": {"date-parts": [{"2010", 9}]}}}, "schema": "https://github.com/citation-style-language/schema/raw/master/csl-citation.json"} used CBCT during their investigation and found 0.3% of teeth with six canals in a Chinese population. There are other reports on six canals available.^{52,53} Teeth with seven canals were clinically treated under magnification assisted by using radiographs and CBCT technology.^{54,55} A report is also available of treating

an eight-canal tooth.⁵⁶ No micro-CT specific reports giving an account of first molars with one, two or more than five canals could be identified in Africa or South Africa.

Accessory canals

According to Ahmed et al.⁵⁷ an accessory canal is a small patent, blind or looped canal leaving the main canal that usually (but not always) communicates with the external root surface or furcation area and encompasses what were previously known as lateral canals. The presence of accessory canals has been investigated for several years in different populations using a variety of techniques. In an Irish population, Shalabi et al.⁵⁸ determined that the P root had the most accessory canals and these canals ranged between one to five per root. Most were in the apical third. These authors used a clearing technique during their investigation. Sert and Bayirli⁴⁴ used staining with dyes on extracted teeth in a Turkish population and found that all roots of all teeth in both males and females contained lateral canals. They were present in either the cervical, middle or apical third of the root. In Uganda it was determined that the MB root had the most accessory canals after using a similar staining technique on their extracted teeth.⁴³

In micro-CT studies, Yamada et al.³² confirm findings from the Ugandan study: the MB roots of their Japanese population sample contained the highest number and the most diverse root canal morphology. A similar finding was by Briseño Marroquin et al.²¹ in a German population. In a Myanmar study the authors found 240 total lateral canals in 101 maxillary first molars, with 56.67% of these in the MB root, 23.75% in the DB root and 19.58% in the P root.⁴⁹ These authors determined that the MB1 canal contained one accessory canal in 26.3% of cases, one accessory canal was present in 12.3% of cases in the DB canal and 9.5% in the P canal. The same authors found that the MB2 canal rarely had a single accessory canal.²¹ In one Brazilian study several accessory canals, isthmuses and foramina were noted in the apical region in particular of the MB root.⁴¹

In a study on a Brazilian subpopulation also focusing on the MB root, it was noted that 47.9% of the sampled teeth contained accessory canals and the majority of these were also in the apical region (76%).⁵⁹ A South Korean population had similar accessory root canal morphology in the apical region of the same root.²⁸

In another micro-CT study on Brazilian individuals, it was found that the P root contained several accessory canals (25%).⁵⁹ A Minnesota study investigating maxillary first and second molars found that at least 40.4% of the P roots contained at least one accessory canal and most of these (74.1%) were in the apical 3mm. Unfortunately, the study did not make a clear distinction between first and second molars.⁶⁰ Similar findings were reported in a Chinese subpopulation.⁶¹ A Japanese study focused on the DB root and found that 27% of the sample contained accessory canals and the vast majority were located apically (88.9%).⁶² Other authors in Brazil, Taiwan and Japan reported similar findings by investigating either the P, MB or all roots.^{59,63,64}

Micro-CT studies reporting accessory canals in African and South Africa populations could not be found. However, Figure 10 illustrates clinical cases of treatment of South African individuals with accessory canals in various roots.

Chamber canals

Accessory canals can also be present in the pulp chamber in the form of furcation canals in the furcation region, which can create a potential pathway between the pulp and the periodontal ligament space (PDL).¹⁷ In a Turkish study using a stereoscopic technique, the pulp floors of 50 maxillary first molars were investigated and it was found that patent furcal accessory canals were present in 12 teeth (24%).⁶⁵ Although investigations focusing on the presence of furcation canals using micro-CT are rare a more recent micro-CT study using extracted teeth from Egypt and Germany, furcation canals were identified in 2.8% of the sample teeth (n=179). The authors distinguished between inter-radicular canals where the pulp chamber communicated with the PDL space and those with blind endings (diverticula). Inter-radicular communications were found in 0.6% of the 2.8%

and diverticula made up the rest (2.2%).¹⁷ To the best of the authors' knowledge, the prevalence of chamber canals has not been reported in African populations.

Apical deltas

According to Ahmed et al.,⁵⁷ an apical delta or an apical ramification is a root canal network at or near the root apex where the main root canal divides into more than two accessory canals. The presence of apical deltas has been reported in various populations, Sample size and the use of newer modalities such as micro-CT did not seem to affect the prevalence of apical deltas in a predictable way. In a large sample comprising 2,800 teeth conducted in Turkey, deltas were observed in all the roots of both males and females using a staining technique, but a higher number were reported in females. In this study, it was determined that the P root contained the most, followed by the DB and MB roots.⁴⁴ However, when also using a clearing and staining technique, in the Ugandan study already mentioned, an incidence of 5% was reported and 25% in an Indian subpopulation.⁶⁶ The use of micro-CT, for instance in the study in Brazil, could not demonstrate apical deltas in all roots as only up to 12% apical deltas were observed in first molars.⁶⁷ In a Chinese micro-CT study, 15% of teeth had apical deltas and most were located in the MB root, compared to 11.2% of the DB (1.7%) and P (1.1%) roots.⁶⁸ Unfortunately, in the Chinese study no distinction was made between first and second molars, so one can only speculate on the incidences of each molar group. The prevalence of apical deltas in South African populations is not known and no investigations were found.

Root canal configurations

Root canals can follow distinct paths within a root and calculating root canal configurations provides valuable information on the internal root and canal morphology of teeth.⁶⁹ Although a number of classifications have been suggested, the Vertucci system is considered by many to be the most appropriate and several authors have used it to determine root canal configurations in the maxillary first molar.^{27,43,7-72} Similar findings as initially described by Vertucci using a clearing and staining technique on molars

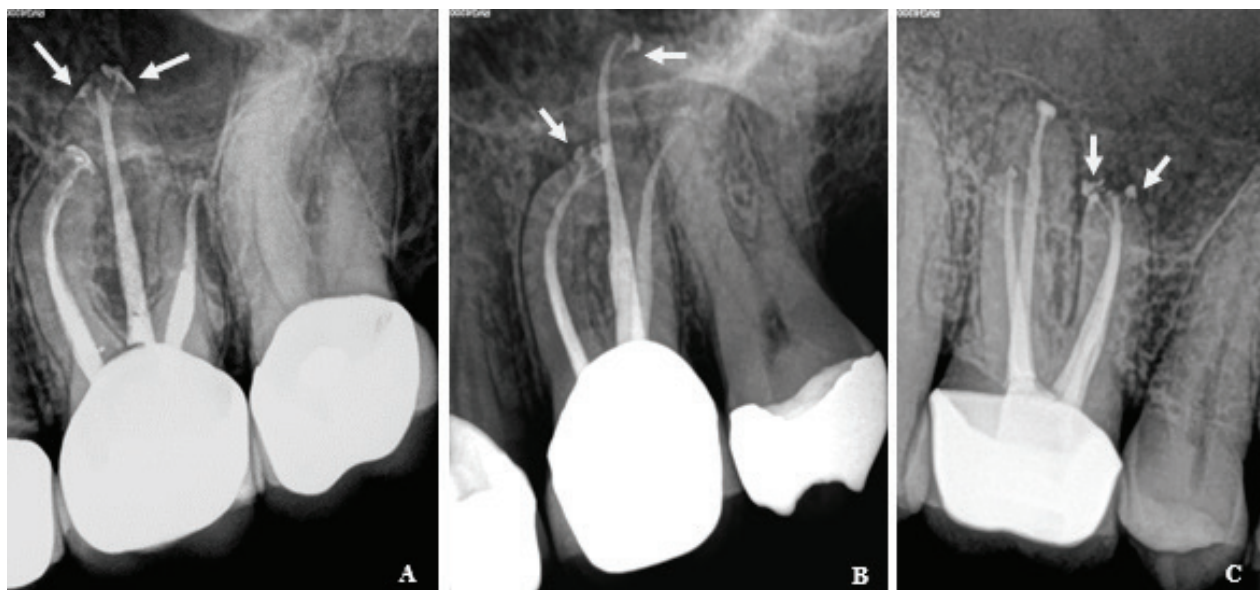


Figure 10: Accessory root canals in maxillary first molars; (A) Left maxillary first molar that presented with two patent accessory canals (white arrows) in the P root branching off from the main root canal system in the apical third; (B) Left maxillary first molar that presented with one patent accessory canal in both the MB and P root (white arrows), branching off from the main root canal system in the apical third; (C) Right maxillary first molar that presented with two patent accessory canals in the MB root (white arrows), branching off from the main root canal system in the apical third.

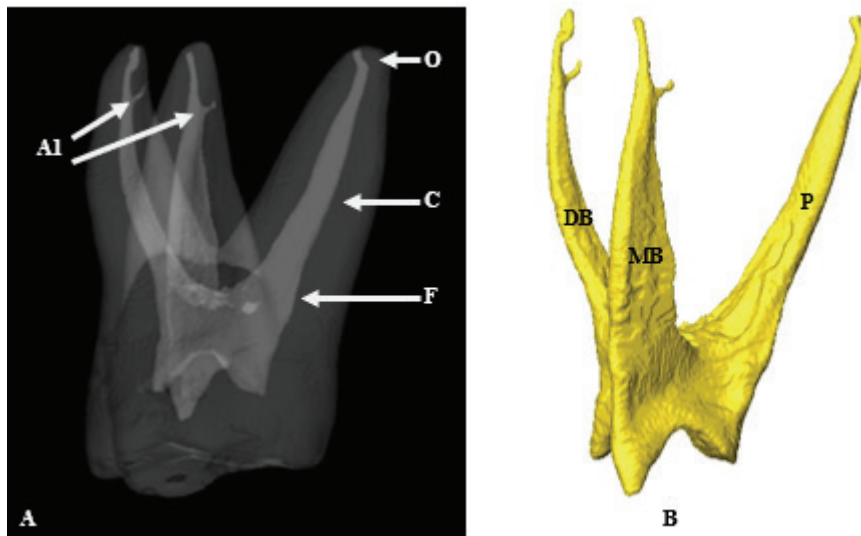


Figure 11: Root canal configuration calculation according to Ahmed et al.^{16,58}; **(A)** Root canal configuration of a right maxillary first molar. In the illustrated images, all root canal systems have a single canal with a single orifice (O). All main canals also follow a singular pathway (C) on their way to the apex with a single apical foramen (F). In both the MB and DB systems, a single patent accessory canal is present in the apical third (A1). The configuration for this tooth is ${}^3\text{MFM M}^{1(\text{A1})} \text{D}^{1(\text{A1})} \text{P}^1$, indicating a three-rooted maxillary first molar with its internal root canal morphology; **(B)** Virtually extracted pulp from the same tooth displaying the root canal system including main and accessory canals.

extracted from American individual, have been reported on various populations and modalities, including on a South African CBCT sample and in micro-CT studies.^{27,31,95,59,43,59,70} Vertucci determined that the root canal systems in the DB and P roots contain a type I configuration (one canal from orifice to apex), while the MB root is more diverse. In the MB roots, Vertucci et al.⁷⁰ described types I, II (two canals joining into one at the apex) and IV (two separate canals from orifice to apex), Kyaw Moe et al.⁴⁹ found all the Vertucci configuration types, Kim et al.³⁵ all the Vertucci classification types except type I, while Rwenyonyi et al.⁴³ found all the Vertucci classification types except type VIII (three separate canals from orifice to exit) while also types I, II and V in the D root.

The Ahmed classification system has recently been introduced.¹⁶ In this system, calculations are determined by following each root canal from the orifice to its pathway and eventual foramen (O-C-F). The system also allows the inclusion of complexities (Figure 11).

Most studies identified used CBCT as their investigative method on different teeth from various populations.⁷³⁻⁷⁵ the root number and canal configurations were described using the classification systems devised by Vertucci (1984) However, studies reporting on this new classification system in maxillary first molars are scarce. Using CBCT and the Ahmed et al. classification system, Mirza et al.⁷⁶ determined that most of the molars in a Saudi Arabian sample contained either ${}^3\text{MXFM MB}^2\text{-}^1\text{DB}^1\text{P}^1$, ${}^3\text{MXFM MB}^2\text{DB}^1\text{P}^1$ or ${}^3\text{MXFM MB}^1\text{DB}^1\text{P}^1$ configurations. This indicates that most of the three-rooted molars had single canals from orifice to apex in the DB and P roots and had either two separate canals, two joining into one or a single canal in the MB root. No micro-CT studies were found in which the Ahmed system was used to calculate root canal configurations to include complexities, for example accessory canals and deltas in different populations.

DISCUSSION

It is apparent that root and root canal morphology can differ between populations because of genetic and external factors.^{73,77} the root number and canal configurations were described using the classification systems devised by Vertucci (1984) It is important that clinicians are aware of any variations as they can greatly influence endodontic

treatment outcomes. Any missed roots and root canals increase the risk of treatment failure as they can harbour infected or irreversibly inflamed tissues.^{2,78}

Methodologies, study designs and sample sizes differ between investigations and care should be taken with interpretation.^{79,80} For example, one author found the MB2 canal in all maxillary first molars but the sample included only 13 teeth. Staining, CBCT and other techniques have been used to investigate root and canal morphology, but different results were noted depending on populations and the investigative techniques used. Micro-CT, the most commonly used methodology to investigate internal root morphology, has the ability to identify the finest detail, often missed with other methods.^{16,41,81} It can be speculated whether micro-CT would have provided different results in the studies where CBCT, staining, radiographs and other techniques were used. The clinical applicability of CBCT cannot be denied, but its use can be limiting in observing fine root canal morphology. However, it is sufficient to report on external and internal root and canal morphology without relying on the inclusion of fine detail.^{15,57}

Most maxillary first molars contain three or four canals. Although figures vary, an estimated guide is that three canals can be present in roughly 30% to 40% of teeth and 60% to 70% can have four canals.¹⁴ The presence of the MB2 canal has been identified as one of the reasons for treatment failure, making the maxillary first molar one of the most challenging teeth to treat endodontically.^{6,9} The MB2 canal is often hidden by dentine ledges and sclerotic tooth structure, which makes them difficult to discover, and unfortunately they are often missed. The presence of this canal is one of the main reasons why this tooth has the highest endodontic failure rate of all treated teeth.^{82,83} Dental practitioners may not have access to specialised equipment such as proper magnification and illumination.⁴¹ Different findings have been noted globally in different populations and the discovery of these canals has been a focus of research for years. Methods of investigation include radiographic⁸⁴ clearing and staining,⁸⁵ supporting and complementing commonly applied clearing technique, using access cavity modification and the pulpal groove deepening method. Three hundred and ninety eight extracted intact human maxillary first molars were included in this study. Firstly, modified rhomboidal shape access cavities were prepared

then, the developmental groove between the mesiobuccal and the palatal canals was deepened 1 mm with a round slow speed bur. Indian ink was injected into both the canal orifices of mesiobuccal roots and into the groove between mesiobuccal and palatal canals, using a 22 gauge syringe. Then the clearing technique was applied. The incidence of one canal was 30.90 %, two canals was 62.07 %, three canals was 7.03 %. In twenty five (6.28 % CBCT¹⁰ and micro-CT, with incidences ranging between 23.3% and 97.6%.

In Africa, studies from Egypt¹⁰ and Nigeria²⁶ report incidences of 62% for the MB2 canal using CBCT and a lower incidence of 23% using sectioning and magnified observation with surgical loupes. The number of MB2 canals may have been higher if three-dimensional techniques (CBCT or micro-CT) had been used in the Nigerian study. It is interesting to note that three South African CBCT studies reported findings of 60.5% Witwatersrand (Gauteng)²⁷, 92% Pretoria (Gauteng)¹¹ (100 female and 100 male patients and 95.6% Durban (KwaZulu-Natal)¹⁰ respectively. In all three, the teeth were collected from mixed populations. Genetic and/or external factors could have contributed to the difference in prevalence between different populations within one country. External factors could be associated with socio-economic status or geographic location. Differences between scan resolutions,⁰, experience of the researcher or the size of the sample in these three studies could also have played a role.

Apart from the MB2 canal, the MB root can contain more than two canals in the form of a third, namely the MB3. Although not as common in most populations, the MB3 canal can still result in treatment failure if not negotiated. The incidence can range anything between 0.1% and 17%, according to reports available. In a Ugandan population the prevalence was 0.5%⁴³ and in a Saudi Arabian sample it was 17%.³⁸ In the Saudi Arabian investigation the sample size was relatively small (35 teeth); a larger sample size could have revealed different results. The use of staining techniques can have certain disadvantages. It can be difficult to remove all blockages, debris and vital tissues from the entire root canal system during preparation of teeth to allow the flow of dyes, and this will hinder the identification of morphology.³² Any additional root canals in the Ugandan study could have remained unseen, whereas Alfouzan et al.³⁸ used micro-CT in their Saudi study. The smaller sample of the Saudi study might also have influenced results.

Additional canals can also be present in the DB and P roots and incidences may vary between 0 and 9.5% for the DB root and 0 to 4.5% for the P root. In much rarer cases, one, two, six, seven and eight canals have been reported. Clinicians should be aware of the possibility of internal morphology outside the expected findings and careful clinical observation and radiographic investigation are required. The clinical application of CBCT has been well documented^{11,14,73} (100 female and 100 male patients and it could allow proper pre-operative planning and diagnosis if available. Although the prevalence of root canals may vary, clinicians should expect to find additional canals until proven otherwise. Accurate predictions may also be impossible, but morphological studies can give clinicians a degree of predictability within populations.

Between 74% and 80% of teeth diagnosed with apical periodontitis contained biofilms of organisms in the apical

part of the root canals and in many cases within accessory canals.⁸⁶ Reports confirm that accessory canals are present in most roots and most frequently in the apical portion.^{39,43,44,58} However, discrepancies have been noted in terminology referring to accessory canals. Authors mention accessory canals, lateral canals and secondary canals, which has created some confusion.^{87,88} For example, the description of the apical delta according to the AAE glossary is a root canal morphology where the main root canal terminates in multiple accessory canals at or near the apex.⁸⁹ The question is how many accessory canals define an apical delta, and where exactly is "at or near the apex"? Recently, a group of authors suggested a standard description for accessory root canal branches (accessory canals, deltas and chamber canals) which encompasses other terminology.⁵⁷ These authors defined an apical delta where more than two accessory canals are present in the proximity of the apex. The current consensus is that a delta includes three or more ramifications at or near the apex of a root.^{31,57,88,90}

The presence of accessory canals and deltas can also play an important role in treatment outcomes. These additional types of root canal morphology are common in human dentition and connect the root canal system to the PDL space by encapsulating blood vessels during the Hertwig root sheet (HERS) development stage.⁶¹ They can also be very difficult to reach with root canal instrumentation and to disinfect with chemicals. This could prove problematic, as bacteria and their by-products can travel from infected root canals to PDL spaces causing disease, or periodontal disease can affect the pulpal space through these channels.⁸⁶ Apical deltas can provide multiple portals of communication between the root canal network and the PDL space which treating clinicians should take note of. Vigorous mechanical and chemical regimes should be followed to achieve proper disinfection.

Investigative methodologies differ but the main method used to observe apical deltas is the clearing technique.⁶⁸ Interestingly, apical deltas were noted in 5% of cases in Uganda but 25% in an Indian subpopulation using a similar technique of staining.^{43,66} Differences can be attributed to population group or even operator technique and sample size. Micro-CT studies focusing on apical deltas are not common. In one micro-CT study, it was determined that in Chinese individuals, the MB root can contain the highest number of apical deltas.⁶⁸ Similar micro-CT observations were made by others in different populations and the MB root was also identified as the one with the most complex internal morphology, including the presence of accessory canals and deltas.^{29,31,41,91}

The other type of accessory canal that can be present is a furcation or chamber canal. These canals can be significant clinically and cause caries-free teeth to become irreversibly affected if periodontal breakdown is present. Causative micro-organisms can gain entry to the root canal space through these channels and vice versa.⁹² This type of morphology has been investigated using different methods which include radiographic,⁹³ clearing and dyes⁹⁴ and scanning electron microscopy,⁹⁵ but micro-CT investigations are limited. One group of investigators conducted the first micro-CT study in 2022 and described the canals as either patent (inter-radicular) or blind ending (diverticula). Any of these can harbour organic material which can cause

inflammatory reactions.¹⁷ Treating clinicians should be mindful of the presence of these root canal morphologies. A proper three-dimensional seal of the pulpal space including the pulp chamber floor during endodontics is vital to close all possible portals of communication and avoid failure and a recurrence of infection.

Through the years authors have incorporated root canal classification systems into their study designs to identify common root canal patterns and their variants. Knowledge of root canal configurations can be beneficial to treating clinicians for diagnostic and treatment planning purposes during endodontics. One of the earliest classifications was described by Weine et al.,⁹⁶ it contained three basic configuration types and since then systems have evolved to include more complex configurations. It was clear from an early stage that not all complex configurations could fit into just a few simple categories. As a result, new systems have been suggested or additions made to current systems during investigations.^{21,44,70,97,98} Despite new classification types and modifications, shortcomings are still present, for example the inability to include detail.⁶⁹

The Ahmed et al.¹⁶ classification system is a welcome addition as it made it possible to include fine detail in calculations, such as accessory canals, apical deltas and complex connections between canals.^{15,16} Its clinical and academic applicability has also been described, including its merit in training undergraduate and postgraduate students.^{99,100} However, the authors themselves mention that the inclusion of fine detail, while beneficial, adds complexity and the risk of confusion among researchers.⁶¹ It seems that the authors faced similar challenges during the development to those that other authors experienced in the past. The number of subjective viewpoints, which could make comparisons between studies inaccurate, should be reduced.⁶¹ The current study identified no micro-CT studies where authors included accessory canals, chamber accessory canals or apical deltas in their calculations on any tooth using the Ahmed et al. classification system. The authors therefore believe that a modification to the Ahmed classification system is required that allows the inclusion of fine detail in configurations without the risk of further confusion and complexity. Clear guidelines and reference to applicable landmarks are also required. A solution will allow standardisation of comparisons of complex configurations of various teeth in different populations.

In conclusion, the internal root canal morphology of the maxillary first molar can be highly complex and the prevalence of the MB2, MB3, additional P and D canals, accessory canals, chamber canals and apical deltas varies across populations. Investigative studies using micro-CT could be beneficial in evaluating internal root and canal morphology for diagnosis and treatment planning. There is also a need to modify or revise classification systems using the Ahmed et al. criteria to include complex configurations. Studies within Africa and South Africa are limited and no micro-CT studies that indicated a prospect of future investigations were identified.

Declaration

The authors declare that there is no financial interest in this paper and that this paper has not been submitted elsewhere for publication. All authors agree with the content of the manuscript. This manuscript did not receive any funding from funding agencies in the public, commercial, or not-for-profit sectors.

Conflict of interest

The authors declare that there is no conflict of interest.

REFERENCES

1. Wu MK, Wesselink PR, Walton RE. Apical terminus location of root canal treatment procedures. *Oral Surg Oral Med Oral Pathol Oral Radiol Endod* 2000; 89: 9–103. DOI: 10.1016/S1079-2104(00)80023-2
2. Vertucci FJ. Root canal morphology and its relationship to endodontic procedures. *Endod Topics* 2005; 10: 3–29. DOI: 10.1111/j.1601-1546.2005.00129.x
3. Chourasia HR, Meshram GK, Warhadpande M, Dakshindas D. Root canal morphology of mandibular first permanent molars in an Indian population. *Int J Dent*. 2012; 2012:16.
4. Jonker C, Van der Vyver PJ. Factors influencing the lifespan of modern root canal instruments – a literature review. *S Afr Dent J*. 2013; 68: 14–23.
5. Peters O. Current challenges and concepts in the preparation of root canal systems: A review. *J Endod*. 2004; 30: 559–67. DOI: 10.1097/01.DON.0000129039.59003.9D
6. Wolcott J, Ishley D, Kennedy W, Johnson S, Minnich S, Meyers J. A five-year clinical investigation of second mesiobuccal canals in endodontically treated and retreated maxillary molars. *J Endod*. 2005; 31: 22–4. DOI: 10.1097/01.don.0000140581.38492.8b
7. Blattner TC, George N, Lee CC, Kumar V, Yelton CDJ. Efficacy of cone-beam computed tomography as a modality to accurately identify the presence of second mesiobuccal canals in maxillary first and second molars: A pilot study. *J Endod*. 2010; 36: 86–70. DOI: 10.1016/j.joen.2009.12.023
8. Degerness RA, Bowles WR. Dimension, anatomy and morphology of the mesiobuccal root canal system in maxillary molars. *J Endod*. 2010; 36: 985–9.
9. Gutmann JL, Fan B. Tooth morphology, isolation, and access. In: Berman LH, Hargreaves KM, 12th ed. *Cohen's pathways of the pulp*. St Louis: Elsevier, 2016: 103–208.
10. Martins JNR, Alkawas MAM, Altaki Z, et al. Worldwide analyses of maxillary first molar second mesiobuccal prevalence: A multicenter cone-beam computed tomographic study. *J Endod*. 2018; 44: 1641–9. DOI: 10.1016/j.joen.2018.07.027
11. Fernandes NA, Herbst D, Postma TC, Bunn BK. The prevalence of second canals in the mesiobuccal root of maxillary molars: A cone-beam computed tomography study. *Aust Endod J*. 2019; 45: 6–50. DOI: 10.1111/aej.12263
12. Filpo-Perez C, Bramante CM, Villas-Boas MH, Húngaro Duarte MA, Versiani MA, Ordiniola-Zapata R. Micro-computed tomographic analysis of the root canal morphology of the distal root of mandibular first molar. *J Endod*. 2015; 41: 21–6. DOI: 10.1016/j.joen.2014.09.024
13. Tomaszewska IM, Jarzebska A, Skinningsrud B, Pekala PA, Wronski S, Iwanaga J. An original Micro-CT study and meta-analysis of the internal and external anatomy of maxillary molars: Implications for endodontic treatment: Morphology of maxillary molars. *Clin Anat*. 2018; 31: 83–53. DOI: 10.1002/ca.23201
14. Versiani MA, Sousa-Neto MD, Basrani B. The root canal dentition. In: *Permanent dentition*, 1st ed. Heidelberg: Springer, 2018: 89–240.
15. Ahmed HMA, Ibrahim N, Mohamad NS, et al. Application of a new system for classifying root and canal anatomy in studies involving micro-computed tomography and cone-beam computed tomography: Explanation and elaboration. *Int Endod J*. 2021; 54: 106–82.
16. Ahmed HMA, Versiani MA, De-Deus G, Dummer PMH. A new system for classifying root and root canal morphology. *Int Endod J*. 2017; 50: 761–70.
17. Andereg AL, Hajdarevic D, Wolf TG. Interradicular canals in 213 mandibular and 235 maxillary molars by means of micro-computed tomographic analysis: An ex vivo study. *J Endod*. 2022; 48: 234–9.
18. Cotton TP, Geisler TM, Holden DT, Schwartz SA, Schindler WG. Endodontic applications of cone-beam volumetric tomography. *J Endod*. 2007; 33: 1121–1132. DOI: 10.1016/j.joen.2007.06.011
19. Nielsen RB, Alyassin AM, Peters DD, Carnes DL, Lancaster J. Microcomputed tomography: An advanced system for detailed endodontic research. *J Endod*. 1995; 21: 561–8.
20. Stauber M, Müller R. Micro-computed tomography: A method for the non-destructive evaluation of the three-dimensional structure of biological specimens. *Methods Mol Biol*. 2008; 455: 273–92. DOI: 10.1007/978-1-59745-104-8_19
21. Briseño-Marroquín B, Paqué F, Maier K, Willershausen B, Wolf TG. Root canal morphology and configuration of 179 maxillary first molars by means of micro-computed tomography: An ex vivo study. *J Endod*. 2015; 41: 2008–13.
22. Grande NM, Plotino G, Gambirani G, et al. Present and future in the use of Micro-CT scanner 3D analysis for the study of dental and root canal morphology. *Ann Ist Super Sanita*. 2012; 48: 26–34.
23. Westenberger P, Avizo – Three-dimensional visualization framework. In: *Proceedings of the Geoinformatics 2008 – Data to knowledge*, USGS, 2008, 13–4.
24. Roerdink JBTM, Meijster A. The watershed transform: Definitions, algorithms and parallelization strategies. *Fundam Inform*. 2000; 41: 18–2.
25. Meyer F, Beucher S. Morphological segmentation. *J Vis Commun Image Represent*. 1990; 1: 21–46
26. Abiodun-Solanke IMF, Dosumu OO, Shaba PO, Ajayi DM. Prevalence of additional canals in maxillary first molars in a Nigerian population. *J Contemp Dent Pract*. 2008; 9: 1–8
27. Irhaim AA. Evaluation of the root and canal morphology of permanent maxillary first molars cone-beam computed tomography in a sample of patients treated at the Wits Oral Health Centre. Dissertation, University of Witwatersrand, 2016: 1–56
28. Park JW, Lee JK, Ha BH, Choi JH, Perinpanayagam H. Three-dimensional analysis of maxillary first molar mesiobuccal root canal configuration and curvature using micro-computed tomography. *Oral Surg Oral Med Oral Pathol Oral Radiol Endod*. 2009; 108: 43–42. DOI: 10.1016/j.tripleo.2009.01.022
29. Somma F, Leoni D, Plotino G, Grande NM, Plasschaert A. Root canal morphology of the mesiobuccal root of maxillary first molars: A micro-computed tomographic analysis. *Int Endod J*. 2009; 42: 15–74. DOI: 10.1111/j.1365-2591.2008.01472.x
30. Gu Y, Lee JK, Spångberg LSW, et al. Minimum-intensity projection for in-depth morphology study of mesiobuccal roots. *Oral Surg Oral Med Oral Pathol Oral Radiol Endod*. 2011; 112: 67–.
31. Verma P, Love RM. A Micro-CT study of the mesiobuccal root canal morphology of the maxillary first molar tooth: Mesiobuccal root canal morphology. *Int Endod J*. 2011; 44: 20–7. DOI: 10.1111/j.1365-2591.2010.01800.x
32. Yamada M, Ide Y, Matsunaga S, Kato H, Nakagawa KI. Three-dimensional analysis of mesiobuccal root canal of Japanese maxillary first molars using micro-CT. *Bull Tokyo Dent Coll* 2011; 52: 7–84. DOI: 10.2209/tdcppublication.52.77
33. Hosoya N, Yoshida T, Iino F, Arai T, Mishima A, Kobayashi K. Detection of a secondary mesio-buccal canal in maxillary first molars: A comparative study. *J*

- Conserv Dent. 2012; 15: 12–31. DOI: 10.4103/0972-0707.94579
34. Domark JD, Hatton JF, Benison RP, Hildebolt CF. Ax ex vivo comparison of digital radiography and cone-beam and micro-computed tomography in the detection of the number of canals in the mesiobuccal roots of maxillary molars. *J Endod.* 2013; 39: 90–5. DOI: 10.1016/j.joen.2013.01.010
35. Kim Y, Chang S-W, Lee J-K, et al. A micro-computed tomography study of canal configuration of multiple-canal mesiobuccal roots of maxillary first molars. *Clin Oral Invest.* 2013; 17: 154–6. DOI: 10.1007/s00784-012-0852-8
36. Lee K-W, Kim Y, Perinpanayagam H, et al. Comparison of alternative image reformatting techniques in micro-computed tomography and tooth clearing for detailed canal morphology. *J Endod.* 2014; 40: 41–22. DOI: 10.1016/j.joen.2013.09.014
37. Zurawski AL, Lambert P, Solda C, Zanesco C, Reston EG, Barletta FB. Mesiolingual canal prevalence in maxillary first molars assessed through different methods. *J Contemp Dent Pract.* 2018; 19: 959-63
38. Alfouzan K, Alfadley A, Alkadi L, Alhezam A, Jamleh A. Detecting the second mesiobuccal canal in maxillary molars in a Saudi Arabian population: A Micro-CT study. *Scanning.* 2019; 2019: 1-7
39. Camargo Dos Santos B, Pedano MS, Giraldo CK, De Oliveira JCM, Lima ICB, Lambrechts P. Mesiobuccal root canal morphology of maxillary first molars in a Brazilian sub-population: A micro-CT study. *Eur Endod J.* 2020; 5: 105-11
40. Tonelli SQ, Sousa-Neto MD, Leoni GB, et al. Micro-CT evaluation of maxillary first molars: Interforifice distances and internal anatomy of the mesiobuccal root. *Braz Oral Res.* 2021; 35: 1-8
41. Ordinolá-Zapata R, Martins JN, Plascencia H, Versiani MA, Bramante CM. The MB3 canal in maxillary molars: A Micro-CT study. *Clin Oral Investig.* 2020; 24: 410–1.
42. Rezaeian M, Tonekaboni MR, Iranmanesh F. Evaluating the root canal morphology of permanent maxillary first molars in an Iranian population. *Iran Endod J.* 2018; 13: 7–.
43. Rwenyonyi CM, Kutesa AM, Muwazi LM, Buwembo W. Root and canal morphology of maxillary first and second permanent molar teeth in a Ugandan population. *Int Endod J.* 2007; 40: 679-83
44. Sert S, Bayirli G. Evaluation of the root canal configurations of the mandibular and maxillary permanent teeth by gender in the Turkish population. *J Endod.* 2004; 30: 39–8. DOI: 10.1097/00004770-200406000-00004
45. Thomas RP, Moule AJ, Bryant R. Root canal morphology of maxillary permanent first molar teeth at various ages. *Int Endod J.* 1993; 26: 25–67. DOI: 10.1111/j.1365-2591.1993.tb00570.x
46. Zheng Q, Wang Y, Zhou X, Wang Q, Zheng G, Huang D. A cone-beam computed tomography study of maxillary first permanent molar root and canal morphology in a Chinese population. *J Endod.* 2010; 36: 148–4. DOI: 10.1016/j.joen.2010.06.018
47. Razumova S, Brago A, Khaskhanova L, Barakat H, Howjijeh A. Evaluation of anatomy and root canal morphology of the maxillary first molar using the cone-beam computed tomography among residents of the Moscow region. *Contemp Clin Dent* 2018; 9: S133-S1.
48. Tian X, Yang X, Qian L, Wei B, Gong Y. Analysis of the root and canal morphologies in maxillary first and second molars in a Chinese population using cone-beam computed tomography. *J Endod.* 2016; 42: 696-701
49. Kyaw Moe MM, Jo HJ, Ha JH, Kim SK. Root canal configuration of Burmese (Myanmar) maxillary first molars: A micro-computed tomography study. *Int J Dent.* 2021; 2021:1-8
50. Matsunaga S, Shimoo Y, Kinoshita H, et al. Morphologic classification of root canals and incidence of accessory canals in maxillary first molar palatal roots: Three-dimensional observation and measurements using Micro-CT. *J Hard Tissue Biol.* 2014; 23: 329-34
51. Albuquerque DV, Kottoor J, Dham S, Velmurugan N, Abarajithan M, Sudha R. Endodontic management of maxillary permanent first molar with 6 root canals: 3 case reports. *Oral Surg Oral Med Oral Pathol Oral Radiol Endod.* 2010; 110: e7–83. DOI: 10.1016/j.tripleo.2010.04.017
52. de Almeida-Gomes F, Maniglia-Ferreira C, De Sousa BC, Dos Santos RA. Six root canals in maxillary first molars. *Oral Surg Oral Med Oral Pathol Oral Radiol Endod.* 2009; 108: e157-e159
53. Karthikeyan K, Mahalaxmi S. New nomenclature for extra canals based on four reported cases of maxillary first molars with six canals. *J Endod.* 2010; 36: 107–8. DOI: 10.1016/j.joen.2009.12.001
54. Kottoor J, Velmurugan N, Sudha R, Hemamalathi S. Maxillary first molar with seven root canals diagnosed with cone-beam computed tomography scanning: A case report. *J Endod.* 2010; 36: 915-21
55. Martins JN. Endodontic treatment of a maxillary first molar with seven root canals confirmed with cone-beam computer tomography – Case report. *J Clin Diagn Res.* 2014; 8: 1-3
56. Kottoor J, Velmurugan N, Surendran S. Endodontic management of a maxillary first molar with eight root canal systems evaluated using cone-beam computed tomography scanning: A case report. *J Endod.* 2011; 37: 71–9. DOI: 10.1016/j.joen.2011.01.008
57. Ahmed HMA, Neelakantan P, Dummer PMH. A new system for classifying accessory canal morphology. *Int Endod J.* 2018; 51: 164-76.
58. Shalabi RMA, Omer JG OE, Jennings M, Claffey NM. Root canal anatomy of maxillary first and second permanent molars. *Int Endod J.* 2000; 33: 40–14. DOI: 10.1046/j.1365-2591.2000.00221.x
59. Marceliano-Alves M, Alves FRF, Mendes D de M, Provenzano JC. Micro-computed tomography analysis of the root canal morphology of palatal roots of maxillary first molars. *J Endod.* 2016; 42: 28–3. DOI: 10.1016/j.joen.2015.10.016
60. Divine KA, McClanahan SB, Fok A. Anatomic analysis of palatal roots of maxillary molars using micro-computed tomography. *J Endod.* 2019; 45: 72–8. DOI: 10.1016/j.joen.2019.03.007
61. Xu T, Fan W, Tay FR, Fan B. Micro-computed tomographic evaluation of the prevalence, distribution, and morphologic features of accessory canals in Chinese permanent teeth. *J Endod.* 2019; 45: 99–9. DOI: 10.1016/j.joen.2019.04.001
62. Yamada M, Matsunaga S, Kasahara N, et al. The microscopic structure of the root canal morphology of the distobuccal root of the maxillary first molar in Japanese people: A micro-computed tomography study. *J Hard Tissue Biol.* 2023; 32: 35-40
63. Alavi AM, Opasanon A, Ng YL, Gulabivala K. Root and canal morphology of Thai maxillary molars. *Int Endod J.* 2002; 35: 478-85.
64. Matsunaga S, Yamada M, Kasahara N, et al. Japanese maxillary first molar root canal morphology: An ultrastructural study using micro-computed tomography. *J Hard Tissue Biol.* 2022; 31: 109-14
65. Haznedaroglu F, Ersev H, Odabasi H, et al. Incidence of patent furcal accessory canals in permanent molars of a Turkish population. *Int Endod J.* 2003; 36: 515-9
66. Bhuyan AC, Katakri R, Phylle P, Gill GS. Root canal configuration of permanent maxillary first molars in a Khasi population of Meghalaya: An in vitro study. *J Conserv Dent.* 2014; 17: 359-63
67. Mazzi-Chaves JF, Silva-Sousa YTC, Leoni GB, et al. Micro-computed tomographic assessment of the variability and morphological features of root canal system and their ramifications. *J Appl Oral Sci.* 2020; 28: 1-10
68. Gao X, Tay FR, Gutmann JL, Fan W, Xu T, Fan B. Micro-CT evaluation of apical delta morphologies in human teeth. *Sci Rep.* 2016; 6: 1–6. DOI: 10.1038/srep36501
69. Karobari MI, Parveen A, Mirza MB, et al. Root and root canal morphology classification systems. *Int J Dent.* 2021; 2021: 1-6
70. Vertucci FJ. Root canal anatomy of human permanent teeth. *Oral Surg Oral Med Oral Pathol* 1984; 58: 58–99. DOI: 10.1016/0030-4220(84)90085-9
71. Ratanajirasut R, Panichuttra A, Panmekiate S. A Cone-beam computed tomographic study of root and canal morphology of maxillary first and second permanent molars in a Thai population. *J Endod.* 2018; 44: 5–61. DOI: 10.1016/j.joen.2017.08.020
72. Martins JNR, Ordinolá-Zapata R, Marques D, Francisco H, Caramês J. Differences in root canal system configuration in human permanent teeth within different age groups. *Int Endod J.* 2018; 51: 93–41. DOI: 10.1111/iej.12896
73. Buchanan GD, Gamielidien MY, Tredoux S, Vally ZI. Root and canal configurations of maxillary premolars in a South African subpopulation using cone-beam computed tomography and two classification systems. *J Oral Sci.* 2020; 62: 9–7. DOI: 10.2334/josnusd.19-0160
74. Buchanan GD, Gamielidien MY, Fabris-Rotelli I, Van Schoor A, Uys A. Root and canal morphology of maxillary second molars in a Black South African subpopulation using cone-beam computed tomography and two classifications. *Aust Endod J.* 2022; 00: –.
75. Olczak K, Pawlicka H, Szymanski W. Root form and canal anatomy of maxillary first premolars: A cone-beam computed tomography study. *Odontology.* 2022; 110: 365-75. DOI: 10.1007/s10266-021-00670.
76. Mirza MB, Gufran K, Alhabib O, et al. CBCT-based study to analyze and classify root canal morphology of maxillary molars: A retrospective study. *Eur Rev Med Pharmacol Sci.* 2022; 26: 6550-60
77. Kuzekanani M, Najafipour R. Prevalence and distribution of radix paramolaris in the mandibular first and second molars of an Iranian population. *J Int Soc Prev Community Dent.* 2018; 8: 240-4
78. Cantatore G, Berutti E, Castellucci A. Missed anatomy: Frequency and clinical impact. *Endod Topics.* 2006; 15: 3-31
79. Rouhani A, Bagherpour A, Akbari M, Azizi M, Nejat A, Naghavi N. Cone-beam computed tomography evaluation of maxillary first and second molars in an Iranian population: A morphological study. *Iran Endod J.* 2014; 9: 190-4
80. Pérez-Heredía M, Ferrer-Luque CM, Bravo M, Castelo-Baz P, Ruiz-Piñón M, Baca P. Cone-beam computed tomographic study of root anatomy and canal configuration of molars in a Spanish population. *J Endod.* 2017; 43: 151–6. DOI: 10.1016/j.joen.2017.03.026
81. Ahmed HMA. A critical analysis of laboratory and clinical research methods to study root and canal anatomy. *Int Endod J.* 2022; 55: 229-80
82. Smadi L, Khraisat A. Detection of a second mesiobuccal canal in the mesiobuccal roots of maxillary first molar teeth. *Oral Surg Oral Med Oral Pathol Oral Radiol Endod.* 2007; 103: e7–e81. DOI: 10.1016/j.tripleo.2006.10.007
83. Hartwell G, Appelstein CM, Lyons WW, Guzek ME. The incidence of four canals in maxillary first molars: A clinical determination. *J Am Dent Assoc.* 2007; 138: 134–6. DOI: 10.14219/jada.archive.2007.0050
84. Al-Nazhan S. The prevalence of two root canals in mesial roots of endodontically treated maxillary first molars among a Saudi Arabian sub-population. *Saudi Dent J.* 2006; 13: 46-52
85. Kaya-Büyükbayram I, Kartal N. Evaluation of complex mesiobuccal root anatomy in maxillary first molar teeth. *Int J Morphol.* 2018; 36: 46–64. DOI: 10.4067/S0717-95022018000200460
86. Ricucci D, Siqueira Jr. JF. Fate of the tissue in lateral canals and apical ramifications in response to pathologic conditions and treatment procedures. *J Endod* 2010; 36: –15. DOI: 10.1016/j.joen.2009.09.038
87. De Deus QD. Frequency, location, and direction of the lateral, secondary, and accessory canals. *J Endod.* 1975; 1: 361-6
88. Cheung GSP, Yang J, Fan B. Morphometric study of the apical anatomy of C-shaped root canal systems in mandibular second molars. *Int Endod J.* 2007; 40: 239-46
89. AAE. Glossary of Endodontic Terms. <https://www.aae.org/specialty/download/glossary-of-endodontic-terms/2020>; accessed 8 August 20.
90. Liu N, Li X, Liu N, et al. A micro-computed tomography study of the root canal morphology of the mandibular first premolar in a population from southwestern China. *Clin Oral Investig.* 2013; 17: 999-1007
91. Ordinolá-Zapata R, Martins JNR, Niemczyk S, Bramante CM. Apical root canal anatomy in the mesiobuccal root of maxillary first molars: Influence of root apical shape and prevalence of apical foramina – a micro-CT study. *Int Endod J.* 2019; 52: 128–.
92. Simon JH, Glick DH, Frank AL. The relationship of endodontic-periodontic lesions. *J Periodontol.* 1972; 43: 202-8
93. Pineda F, Kuttler Y. Mesiodistal and buccolingual roentgenographic investigation of 7,275 root canals. *Oral Surg Oral Med Oral Pathol.* 1972; 33: 11–10. DOI: 10.1016/0030-4220(72)90214-9
94. Wolf TG, Wentaschek S, Wierichs RJ, Briseño-Marroquín B. Interradicular root canals in mandibular first molars: A literature review and ex vivo study. *J Endod.* 2019; 45: 19–35. DOI: 10.1016/j.joen.2018.10.019
95. Dammaschke T, Witt M, Ott K, Schäfer E. Scanning electron microscopic investigation of incidence, location, and size of accessory foramina in primary and permanent molars. *Quintessence Int.* 2004; 35: 699-705
96. Weine FS, Healey HJ, Gerstein H, Evanson L. Canal configuration in the mesiobuccal root of the maxillary first molar and its endodontic significance. *Oral Surg Oral Med Oral Pathol.* 1969; 28: 419-25
97. Kartal N, Cimilli H (Kapkin). The degrees and configurations of mesial canal curvatures of mandibular first molars. *J Endod.* 1997; 23: 38–62. DOI: 10.1016/S0099-2399(97)80182-3
98. Gupta SK, Saxena P. Proposal for a simple and effective diagrammatic representation of root canal configuration for better communication amongst oral radiologists and clinicians. *J Oral Biol Craniofac Res.* 2016; 6: 0–6. DOI: 10.1016/j.jobcr.2015.09.005
99. Ahmed HMA, Dummer PMH. Advantages and applications of a new system for classifying roots and canal systems in research and clinical practice. *Eur Endod J.* 2018; 3: 9–.
100. Ahmed HMA, Che Ab Aziz ZA, Azami NH, et al. Application of a new system for classifying root canal morphology in undergraduate teaching and clinical practice: A national survey in Malaysia. *Int Endod J.* 2020; 53: 871-9

In vitro comparative study of the ethanol and aqueous extracts of *Spondias mombin* leaves, stem bark and charcoal on *Streptococcus mutans*

SADJ March 2024, Vol. 79 No.2 p86-91

Gertrude C Iwueke¹, W Braide², Stanley C Onwubu³, Samuel C Iwuji⁴, AS Joe-Izuegbu⁵

ABSTRACT

Background

Plants are increasingly explored for their potential as antimicrobial agents. *Spondias mombin* plants have been used in folkloric medicine in the treatment of dental health and general health issues.

Aims and objectives

To compare zone of inhibition, minimum inhibitory concentration and minimum bactericidal concentration of *S. mombin* aqueous and ethanol stem bark, leaves and charcoal extracts on *Streptococcus mutans*.

Material and methods

Twenty grams of each plant part was soaked in 100ml of ethanol and boiled in distilled water and left to stand for 24h with intermittent shaking until evaporated. The dried filtrates were diluted to obtain concentrations of 500mg/ml, 250mg/ml, 125mg/ml and 62.5mg/ml in duplicates. The zone of inhibition, minimum inhibition concentration and minimum bactericidal concentration tests on *S mutans* were carried out using a standard procedure.

Results

Ethanol and aqueous extracts of *S. mombin* displayed antimicrobial activity against *Streptococcus mutans*. The leaves and stem bark extracts demonstrated superior potency compared to charcoal extracts. Ethanol extracts

(32.4mm) consistently exhibited stronger inhibitory effects than aqueous extracts (25mm).

Conclusion

The salient feature of this study justifies the folkloric medicinal use of *Spondias mombin* plants in the treatment of toothaches and prevention of dental caries.

Keywords

Streptococcus mutans, *Spondias mombin*, dental caries, dextran, zone of inhibition, minimum bactericidal

INTRODUCTION

Streptococcus mutans is classified as a gram-positive facultative anaerobe. It is an important pathogen in dental caries formation. *Streptococcus mutans* can be isolated from active and non-active sites in the oral cavity.¹ The pathogenicity of *Streptococcus mutans* is more associated with the presence of dietary sucrose. *Streptococcus mutans* produces complex extracellular polysaccharide (dextran) and glycoproteins from sucrose which helps *Streptococcus mutans* and other associated microbes bind tightly to the teeth and the surrounding structures leading to a large colony of *Streptococcus mutans* producing acids from sucrose. The acidic environment resulting from acid production from the metabolism of carbohydrate substrates on the teeth surface leads to the formation of lesions on the teeth enamel.² Untreated dental caries can cause difficulties in chewing, sleeping, pain, systemic infections, stunted growth in children and absence from work and school, thus impairing quality of life.³ The breakdown of pulpal tissues can lead to intense pain. It can also cause halitosis, foul taste, sensitivity, discomfort when chewing, difficulty in facial movement, jaw pain etc.⁴

Several studies have revealed that dental caries can be prevented by eliminating and reducing the growth of *Streptococcus mutans* in the oral cavity by preventing formation of dental plaque inhabited by dextran-mediating bacterial aggregation. This can be achieved by mechanical means such as brushing, which may not be sufficient.⁵ Chemical agents such as xylitol and chlorhexidine have proven to be effective in reducing the growth of *Streptococcus mutans*. However, prolonged use of chlorhexidine is associated with altered microbiota, taste alteration, staining of teeth and restorations and mucosal desquamation.^{6,7}

The folkloric medicinal plants have been suggested as an alternative to synthetic chemical agents since

Authors' information

1. Gertrude C Iwueke, Department of Dental Technology, Federal University of Technology, Owerri, Imo State, Nigeria
ORCID: <https://orcid.org/0009-0001-1085-8970>
2. W Braide, Department of Microbiology, Federal University of Technology, Owerri, Imo State, Nigeria
3. Stanley C Onwubu, Chemistry Department, Durban University of Technology, Durban, South Africa ORCID: <https://orcid.org/0000-0002-4499-1534>
4. Samuel C Iwuji, Department of Biomedical Engineering, Federal University of Technology, Owerri, Imo State, Nigeria
5. AS Joe-Izuegbu, Department of Dental Technology, Federal University of Technology, Owerri, Imo State, Nigeria

Corresponding author

Name: Stanley Chibuzor Onwubu
Email: stanleyo@dut.ac.za

Author's contribution

1. Gertrude C Iwueke – writing article, conceptualisation, data collection (50%)
2. Stanley Chibuzor Onwubu – writing article, editing, data analysis (25%)
3. AS Joe-Izuegbu – writing article, literature review (10%)
4. W Braide – editing, adviser (10%)
5. Samuel C Iwuji – adviser (5%)

they have little or no side effects on the oral tissues.⁸ *Spondias mombin* is one such plant. *Spondias mombin* is a fructiferous tree growing in Nigeria and other tropical zones. It can be cultivated easily and is used for fencing and enclosures in eastern and western Nigeria.⁹ It is called “uvuru”/“ijinkara” in Igbo, “iyeye”/“akika”/“ebo” in Yoruba, “isada”/“tsardamaster” in Hausa, “Chabbuh” in Fulani, “Cheegbe” in Edo, “Aginiran” in Ijaw, “Kaka” in Tiv, “Nuskakara” in Efik, “Bula” in Costa Rica, “Jobito” in Panama, “Jobo blanco” in Colombia, “Jobo corronchoso” in Venezuela, “Hoebob” in Surinam, “Cja” in Brazil, “Ubo” in Peru and “Hobo” in Mexico.¹⁰

All parts of the *Spondias mombin* tree are medically important in folkloric medicine. The fruit decoction is used as a diuretic and febrifuge.¹¹ Tea made of *Spondias mombin* leaves and flowers relieves stomachache, biliousness and inflammation. Decoction of young leaves is used to treat diarrhoea and dysentery. Crushed leaves and the powder of dry leaves are applied to wounds. They were also used for their antimicrobial, antiviral, abortifacient anti-inflammatory properties.¹² The Ivoirians use the roots as febrifuge. The stem is used as a purgative and local treatment for leprosy. The decoction of stem barks is used for the treatment of severe cough, serves as emetic, remedy for diarrhoea, dysentery, hemorrhoids, gonorrhoea and leucorrhoea.¹² The decoction of astringent stem bark is used to expel calcification from kidneys. The gum in the trees is used as expectorant and to expel tapeworms.¹³ The Igbos used the decoction of the leaves to wash swollen faces.¹¹ The antimicrobial properties of parts of the *Spondias mombin* tree – leaves, stem bark and fruits – have been confirmed by numerous phytochemical studies.¹⁴ Plants and plant-derived products have been used for centuries to improve human health, even before contemporary medicine.¹⁵ The medical use of *Spondias mombin* has been mostly through oral communication but there has not been any report of adverse effects through the use of the leaves.¹⁶ The purpose of this study is to determine the part of *Spondias mombin* plant that has greater antimicrobial activities against *Streptococcus mutans* in order to encourage developing countries to incorporate *Spondias mombin* in plant-based therapies in their healthcare systems for the prevention and treatment of dental caries.

MATERIALS AND METHODS

Collection of plant materials

Fresh leaves, stem bark and wood of *Spondias mombin* for the charcoal were obtained from Eziobodo in Owerri, Imo State, Nigeria.

Preparation and extraction of *Spondias mombin* plant

The leaves, stem bark and wood were sundried. The leaves and stem barks were pulverised using a mechanical grinder. The dried wood was burnt to obtain charcoal which was pulverised using a mechanical grinder. Twenty grams of each plant material was weighed with a digital weighing balance and soaked in 100ml of ethanol and hot water in 250ml Uniscope flasks. The flasks were covered with a cotton plug and then wrapped with aluminum foil and allowed to stand for 24h in an electronic shaker. Filtration was done using Whatman 42 filter paper. The filtrates were allowed to evaporate to dryness in as many petri dishes that could contain the leaves, stem bark and charcoal solution and labelled accordingly on the base of the petri dishes. The ethanol and aqueous filtrates of the leaves, stem bark and charcoal extracts of *S. mombin* were scraped off the

dish with a sterile scalpel into separate sterile containers labelled appropriately and covered, ready to be used. 80ml of Gentamycin infusion and mouthwash were used as the control to compare the effectiveness of the plant against *Streptococcus mutans* in zones of inhibition. The tests for each plant part and the controls were done in duplicate to obtain the standard deviation. Minimum inhibitory concentration and minimum bactericidal concentration were also done using the concentrations of plant parts.

Source of *Streptococcus mutans* isolate

Tooth swabs were collected from the gum and cavity of a patient in a dental clinic using a sterile swab stick. The swab stick was immediately transported to the laboratory in an ice pack. The swab stick was transferred into a nutrient broth to resuscitate the organisms in the swab stick. One-tenth millilitre (0.1ml) from dilution 10⁴ was inoculated into pre-sterilised MS agar, and inocula spread evenly and incubated anaerobically in an anaerobic jar maintained at 37°C for 48h. *Streptococcus mutans* was identified according to the method of Cheesbrough (2002).

Antimicrobial susceptibility tests of *Spondias mombin* ethanol and aqueous extracts of the leaves, stem bark and charcoal

Susceptibility of *Streptococcus mutans* to the extracts of *Spondias mombin* leaves, stem bark and charcoal was done by means of agar well diffusion assay. Four wells 6.25mm deep labelled A-D were made with a sterile cork borer on each four (4) Mueller Hinton Agar petri dishes previously seeded with the 24h old, standardised cultures (*Streptococcus mutans*). For this test, dried ethanol and aqueous filtrates of *Spondias mombin* leaves, stem bark and charcoal were each introduced into a test tube (labelled appropriately) with 1ml of distilled water using a pipette and then shaken. These were then used to obtain different concentrations of 500mg/ml, 250mg/ml, 125mg/ml and 62.5mg/ml using 2-by-2-dilution method in duplicate for each plant part (labelled A-500mg/ml, B- 250mg/ml, C-125mg/ml, D-62.5mg/ml). The four wells on each petri dish (A-D) were filled with different concentrations (500mg/ml, 250mg/ml, 125mg/ml and 62.5mg/ml) of ethanol and aqueous extracts of *Spondias mombin* leaves, stem bark and charcoal drawn with a pipette according to the alphabet. 80mg/ml of Gentamycin and mouthwash were introduced to two wells on the fourth petri dish as controls. This was done in duplicate. The plates were incubated for 24h at 37°C. Clear zones of inhibition were measured after incubation and recorded in millimeters (mm) using a transparent ruler.

Minimum inhibitory concentration (MIC) of *Spondias mombin* ethanol and aqueous extracts of the leaves, stem bark and charcoal

Serial dilutions of the ethanol and aqueous extracts of *Spondias mombin* leaves, stem bark and charcoal (representing different concentrations of 500mgml⁻¹, 250mgml⁻¹, 1.25mgml⁻¹ and 62.5mgml⁻¹) were made in two-fold dilution in nutrient broth. 0.5ml of standardised *Streptococcus mutans* cultures were introduced into the broth containing the different concentrations of the extract and incubated at 37°C for 24h. The procedure was repeated for the extracts. Broth tubes that appear turbid are indicative of bacterial growth while tubes that remain clear indicate no growth. The MIC of the antibiotics/antimicrobial agents is the lowest concentration that does not show growth. The overnight grown isolates in

the broth were further subjected to spectrophotometric reading to determine the optical density at 340nm. Each broth tube containing different concentrations of leaves, stem bark and charcoal extracts of *Spondias mombin* (labelled according to the plant parts and concentrations) was placed into a spectrophotometer (machine), which had its readings reset to zero, using distilled water. The spectrophotometer, when switched on, allowed the passage of light rays through the broth tubes. Readings of last figures on display were recorded. Broth tubes with clearer solution recorded higher figures on the machine. This also indicated no growth of test organism. Turbid broth tubes recorded lower figures on the machine, indicating growth of test organism.

Minimum bactericidal concentration of *Spondias mombin* ethanol and aqueous extracts of the leaves, stem bark and charcoal

A loopful of wire loop suspensions from MIC (with different concentrations of leaves, stem bark and charcoal extracts of *Spondias mombin*) were streaked equally on a freshly prepared surface of dried Mueller Hinton agar plates labelled according to the plant parts and concentrations (30 plates in all), and incubated overnight at 37°C. Each concentration of leaves, stem bark and charcoal extracts of *Spondias mombin* were in duplicate which resulted in 24 plates for ethanol extracts and 24 plates for aqueous extracts. The streaking with loopful of wire loop suspensions from MIC was carried out on all the plates. MBC was indicated as the plate/concentration with the least bacteria growth. The different concentrations were duplicated.

Data analysis

Using Statistical Package for Social Science (SPSS version 29, IBM), paired sample t-test was applied to test the mean zone of inhibition (mm) effects between aqueous extracts and ethanol extracts for each of the concentrations. One-way analysis of variance was applied to compare the mean zone of inhibition (mm) for 500mg leaf extracts, Gentamycin (80mg) and mouthwash. All analysis was performed at $\alpha=0.05$.

RESULTS

Antimicrobial activities of *Spondias mombin* against *Streptococcus mutans*

For each *Spondias mombin* ethanol and aqueous extracts of stem bark, leaves and charcoal, multiple concentrations were tested against *Streptococcus mutans*. The zone of

inhibition values were recorded as the mean of duplicates, along with the standard deviation to show the variability within those duplicates.

The results in Table I revealed interesting patterns. At a concentration of 500mg, both *Spondias mombin* bark and leaves ethanol extracts exhibited substantial antimicrobial activity, with zone of inhibition values ranging from 22.5±3.5mm to 32.5±3.5mm, respectively. The ethanol extract of *Spondias mombin* leaves showed the highest zone of inhibition (32.5±3.5), suggesting it had a stronger inhibitory effect on *Streptococcus mutans* compared to aqueous extracts (25±0.0). This difference is not statistically significant – ie t-test p-value=,102.

As the concentration of the extracts decreased to 250mg and 125mg, the zone of inhibition also reduced. However, the extracts still demonstrated noticeable antimicrobial activity, especially the ethanol extract of *Spondias mombin* leaves at 125mg concentration, which showed a zone of inhibition of 17.5±3.5mm against the aqueous extract of *Spondias mombin* leaves.

The antimicrobial activities of the stem bark, and ethanol extracts of the leaves and charcoal, are nonexistent at the concentration of 62.5mg. The aqueous extracts of the leaves and charcoal show some antimicrobial activity, 7.5 µg/mL ± 3.5 and 7.5 µg/mL ± 0.0 respectively.

Figure 1 depicts the antimicrobial activities of ethanol and aqueous extracts of *Spondias mombin* leaves, Gentamycin (an antibiotic) and mouthwash against *Streptococcus mutans*. The zone of inhibition was measured in millimetres (mm) to assess the extent of inhibitory effect of each extract on the growth of the test organism.

The *Spondias mombin* leaves ethanol extract exhibited a zone of inhibition of 32.5mm at 500mg/ml against the test microorganism. This suggested that the extract at this concentration had a significant inhibitory effect on the growth of the test organism.

The *Spondias mombin* leaves aqueous extract showed a slightly reduced zone of inhibition of 25mm at 500mg/ml. While the inhibitory effect was slightly lower compared to the ethanol extract, it still demonstrated substantial antimicrobial activity against the microorganisms.

Table I. Diameter of the Zone of Inhibition of ethanol and aqueous extracts of *Spondias mombin* stem bark, leaves and charcoal against *Streptococcus mutans*

Concentration (mg)	Zone of inhibition (mm)								
	Spondias mombin stem bark			Spondias mombin Leaves		Charcoal			
	Ethanol	Aqueous	P value	Ethanol	Aqueous	P value	Ethanol	Aqueous	P value
500	22.5±3.5	22.5±3.5	0.500	32.5±3.5	25±0.0	0.102	10±0.0	0.0±0.0	0 ^a
250	15±0.0	15±0.0	0.374	22.5±3.5	16.5±2.1	0.144	6.5±0.0	0.0±0.0	0 ^a
125	6.5±2.1	12.5±3.5	0.500	17.5±3.5	12.5±3.5	0.500	2.5±3.5	5±7.1	0.500
62.5	0.0±0.0	0.0±0.0	0 ^a	0.0±0.0	7.5±3.5	0.205	0.0±0.0	7.5±0.0	0.500

Values are the mean of two duplicates ± standard deviation. P>0.05 (t-test), 0^a= t cannot be computed because the standard deviation of the difference is equal to 0.

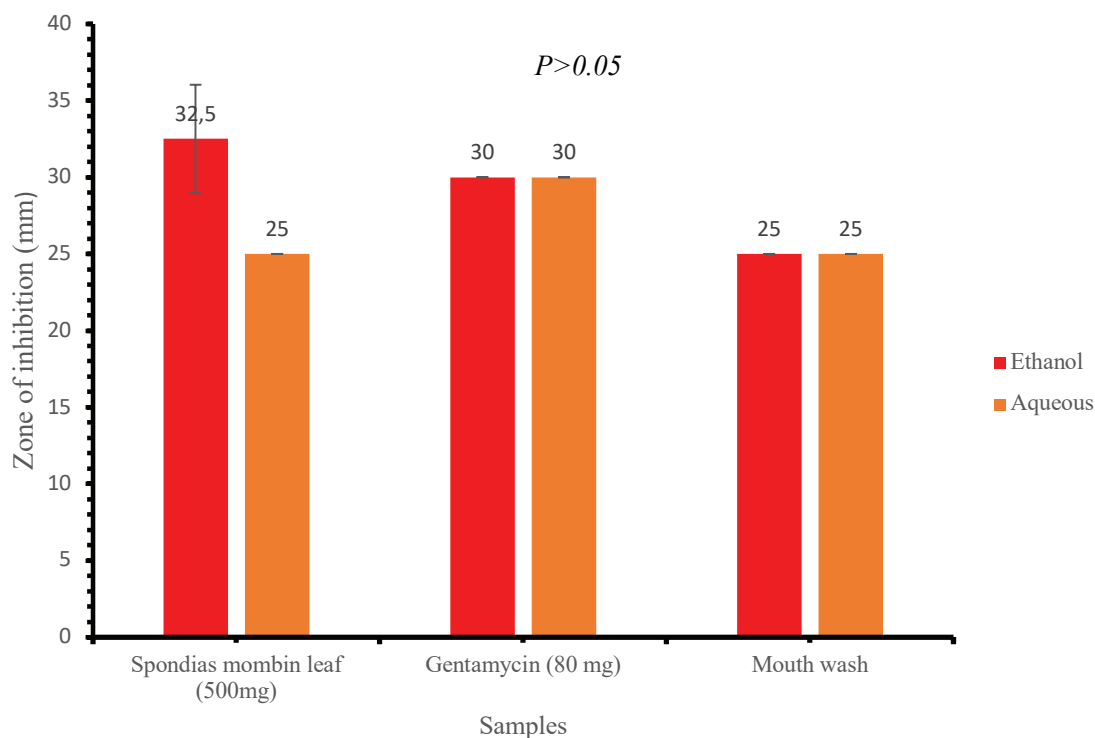


Figure 1. Graphical representation of the zone of inhibition of ethanol and aqueous extracts of *Spondias mombin* leaves against test organism compared with the controls

Figure 1 shows that the ethanol extract of *Spondias mombin* leaves has a larger zone of inhibition compared to Gentamycin (32.5mm vs 30mm). Nevertheless, Gentamycin exhibited substantial zones of inhibition of 30mm at 80mg/ml while the leaves extracts performed stronger at higher concentration. Mouthwash also showed zones of inhibition of 25mm at 80mg/ml than both ethanol and aqueous extracts of the plant parts at lower concentrations (250mg/ml, 125mg/ml and 62.5mg/ml).

In summary, the results demonstrated that *Spondias mombin* leaves ethanol and aqueous extracts, at a concentration of 500mg, exhibited notable antimicrobial activity against the test microorganism. However, the antimicrobial activity was stronger in the ethanol leaves extract.

The data in Table II shows the Minimal Inhibitory Concentration (MIC) of different extracts from *Spondias*

mombin bark, *Spondias mombin* leaves and *Spondias mombin* charcoal against *Streptococcus mutans*. The MIC is the lowest concentration of an antimicrobial agent that inhibits visible growth of a microorganism.

At the highest concentration of 500mg, the *Spondias mombin* bark and leaves extracts exhibited MIC values ranging from approximately 1.53 µg/mL to 1.98 µg/mL against *Streptococcus mutans*. Among these extracts, the ethanol extract of *Spondias mombin* leaves showed the most potent inhibitory effect, having an MIC of 1.46 µg/mL against *Streptococcus mutans*.

As the concentration of the extracts decreased to 250mg and 125mg, the MIC values generally increased, indicating that higher concentrations were required to achieve the same level of inhibition. However, the extracts still demonstrated considerable antimicrobial activity, with the ethanol extract

Table II. Minimum Inhibitory Concentration of ethanol and aqueous extracts of *Spondias mombin* stem bark, leaves and charcoal against *Streptococcus mutans*

Minimal inhibitory concentration									
Concentration (mg)	<i>Spondias mombin</i> bark			<i>Spondias mombin</i> leaf			Charcoal		
	Ethanol	Aqueous	P value	Ethanol	Aqueous	P value	Ethanol	Aqueous	P value
500	1.5310±0.01	1.1145±0.05	0.065	1.9840±0.29	1.6560±0.71	0.470	0.3435±0.20	1.0585±0.18	0.097
250	1.4420±0.01	1.3050±0.07	0.181	2.03380±0.02	1.8790±0.18	0.420	0.3680±0.02	0.5120±0.06	0.244
125	1.4970±0.56	0.9825±0.19	0.409	1.4490±0.59	1.3720±0.22	0.248	0.4115±0.06	0.8805±0.52	0.458
65.2	1.0775±0.56	0.9180±0.24	0.603	1.4590±0.05	1.0590±0.26	0.228	0.8145±0.52	0.7285±0.26	0.729

Values are the mean of two duplicates ± standard deviation. P>0.05

Table III. Minimum bactericidal concentration of ethanol and aqueous extracts of *Spondias mombin* stem bark, leaves and charcoal on *Streptococcus mutans*

Minimal bactericidal concentration					
Spondias mombin stem bark		Spondias mombin Leaves		Charcoal	
Ethanol	Aqueous	Ethanol	Aqueous	Ethanol	Aqueous
-	+	-	+	+	++
-	-	-	-	+	++
+	++	-	++	++	+++
++	+++	+	+++	++++	++++

of *Spondias mombin* leaves showing the highest MIC of approximately 2.04 µg/mL against *Streptococcus mutans*.

At the lowest concentration of 65.2mg, the MIC values decreased further, showing that the antimicrobial activity decreased at this concentration. However, the extracts remained effective against the microorganism, with the ethanol extract of *Spondias mombin* leaves having an MIC of approximately 1.46 µg/mL against *Streptococcus mutans*.

The charcoal extract showed varying MIC values across different concentrations and extraction medium but generally exhibited weaker inhibitory effects compared to the *Spondias mombin* bark and leaves extracts.

Overall, the data in Table III indicates that both *Spondias mombin* bark and leaves extracts possess notable bactericidal properties, with the ethanol extracts demonstrating stronger bactericidal effects compared to the aqueous extracts. The MBC values provide valuable information about the effectiveness of each extract and concentration against the tested microorganism.

Indicates no growth of *Streptococcus mutans*. + slight growth of *Streptococcus mutans*. ++ noticeable growth of *Streptococcus mutans*. +++ overgrowth of *Streptococcus mutans*.

DISCUSSION

This study compared the zone of inhibition (ZOI), minimum inhibition concentration (MIC) and minimum bactericidal concentration (MBC) of ethanol and aqueous extracts of *Spondias mombin* stem bark, leaves and charcoal against *Streptococcus mutans*, which is a cariogenic organism. Many studies have shown that plants contain antibacterial and even antifungal substances. *Spondias mombin* is among the numerous plants of medicinal interest due to its use in folkloric medicine in the treatment of various ailments including dental health issues.¹⁷

In this study, *Spondias mombin* stem bark, leaves and charcoal ethanol and aqueous extracts all exhibited antimicrobial activities at varying concentrations (with the exception of 62.5mg/ml of ethanol and aqueous extracts of the stem bark and leaves extracts) in zone of inhibition assay. This result from zone of inhibition was similar to the research carried out by Garga, Garasin¹⁸ and Mada, Garba¹⁹ who reported that the higher the concentrations of both extracts, the higher the antibacterial activities against test organism.

The stem bark extracts showed concentration dependent activity. The result contrasted the findings of Osuntokun¹¹ who reported that aqueous extracts of stem bark of *Spondias mombin* were less active against the test bacteria than ethanol extract. He attributed his findings to the partial dissolution of some of the active components by water. However, the result of these findings could be attributed to the use of hot distilled water instead of cold distilled water which could mean that hot water is a better solvent than cold water, and so justifies the use of hot water as extractant by traditional healers.²⁰

The result from this study revealed that ethanol leaves extract of *Spondias mombin* had higher antibacterial activities in zone of inhibition with mean value of 32.5mm at 500mg/ml (higher than Gentamycin (30mm) and mouthwash (25mm)). The present results confirm the finding from a study by Cordeiro, de Mendonca²¹ where they discovered that ethanol extracts of *Spondias mombin* leaves had more inhibitory activities against *Streptococcus mutans* while using chlorhexidine digluconate as gold standard. Further, this study supports the finding by Maduka, Okpogba²² who reported that ethanol extract of *Spondias mombin* leaves inhibited growth of *Staphylococcus aureus* more than hot and cold aqueous leaves extract of *Spondias mombin*. A study by Amadi, Oyeka²³ did not notice any noticeable antimicrobial activities of *Spondias mombin* ethanol and hot water extracts against *Streptococcus mutans* in zone of inhibition diameter. However, they reported higher zone of inhibition diameter of the cold-water extracts of *Spondias mombin* leaves and *Baphia nittida* leaves combined than *Baphida nittida* alone against *Streptococcus mutans*. Kudi, Umoh²⁴ suggested that plants extract with zone of inhibition of 6mm and above against a selected pathogen is considered to have antimicrobial activities while Adeleye, Omadime²⁵ suggested 10mm and above. In this study, the stem bark, the leaves and charcoal ethanol extracts all demonstrated zone of inhibition diameter greater than 6mm and above, at varying concentrations. The aqueous extract of charcoal had a zone of inhibition diameter of 7.5mm at 62.5mg/ml. The ethanol and hot water extracts of *Spondias mombin* charcoal had the least zone of inhibition diameter among the parts of *Spondias mombin* tree. The hot water extracts of charcoal were noticed to have some inhibitory diameter at lower concentration than ethanol extracts.

The spectrophotometric readings of minimum inhibitory concentrations of ethanol extract of leaves of *Spondias mombin* showed more inhibitory activity against test organism at higher concentrations (500mg/ml to 250mg/ml) but, at 125mg/ml, ethanol stem bark extract demonstrated slightly higher inhibitory activity. This result corroborates the

finding by Maduka, Okpogba²² who reported that stem bark and leaves ethanol extracts of *Spondias mombin* inhibited *E. coli*, *Pseudomonas*, *Klebsiella* and *Staphylococcus*. The ethanol and aqueous extracts of the leaves showed highest inhibitory activities at 500mg/ml, while aqueous extracts of the charcoal exhibited more inhibitory action against the test organism than ethanol extracts of charcoal. This finding confirmed the result by Cordeiro, de Mendonca²¹ and de Lima, Alves²⁶ who reported that the aqueous and ethanol extracts of *Spondias mombin* leaves exhibited bactericidal actions in the first two hours after initial contact with test organisms. It was suggested that hydroethanolis extracts of *Spondias mombin* leaves in clinical test as mouthwash. Chlorhexidine was found to exhibit bactericidal effect for up to 12h²¹. Bactericidal actions decreased with a decrease in concentration. However, aqueous extracts of stem bark exhibited bactericidal action at 250mg/ml, barest growth at 500mg/ml and noticeable growth at decreased concentrations. The bactericidal activities of aqueous extract of the leaves reduced with decreased concentration. The aqueous extracts of the charcoal had the least bactericidal activities against test organisms. All the extracts exhibited concentration dependent bactericidal activities.¹⁹ These findings provide valuable insights into the antimicrobial properties of *Spondias mombin* leaves extract and the effectiveness of Gentamycin and mouthwash as antimicrobial agents. The study highlights the potential applications of *Spondias mombin* leaves extract in various contexts where inhibiting the growth of the *Streptococcus mutans* is desired, such as in the development of pharmaceuticals, oral care products and antimicrobial agents. Further research and analysis may be required to explore the mechanisms underlying the observed antimicrobial activities and to optimise the concentrations of the treatments for specific applications.

CONCLUSION

This study revealed that *Spondias mombin* plant parts possessed antimicrobial activities against *Streptococcus mutans*. The ethanol extract of *Spondias mombin* leaves showed significantly higher antimicrobial activities than aqueous and ethanol extracts of the stem bark, leaves and charcoal. This result justified the use of this plant in traditional medicine for treatment of dental and other health issues. These findings provide valuable insights into the antimicrobial properties of *Spondias mombin* leaves extract and the effectiveness of Gentamycin and mouthwash as antimicrobial agents. The study also highlights the potential applications of *Spondias mombin* leaves extract in various contexts where inhibiting the growth of the test organism is desired, such as in the development of pharmaceuticals, oral care products and antimicrobial agents.

RECOMMENDATION

The antimicrobial activities of ethanol and aqueous extracts of *Spondias mombin* plant can be used to inhibit the growth of *Streptococcus mutans*, the organism colonising the biofilm and implicated in dental caries formation. More research needs to be carried out on the use of *Spondias mombin* extracts in dental restorative materials such as dental cement, denture base materials, mouthwash and dentifrices to inhibit growth of *Streptococcus mutans* in biofilms and subsequently dental caries. Further research and analysis may be required to explore the mechanisms underlying the observed antimicrobial activities and to optimise the concentrations of the treatments for specific

applications. Moreso, since dental treatment is expensive in most underdeveloped countries, *Spondias mombin* could be refined and employed in the primary health centres for preventive treatment of dental caries. This would greatly support the current trend of preventive dentistry.

Acknowledgement

The authors acknowledge the support of the staff at the Anthony Van Leeuwenhoek Research Center and Dr Adolanum.

Conflict of interest

The authors declare no conflict of interest. The authors alone were responsible for the content and the writing of the paper.

REFERENCES

1. Matsumoto-Nakano M. Role of *Streptococcus mutans* surface proteins for biofilm formation. *Japanese Dental Science Review*. 2018;54(1):22-9
2. Sivamaruthi BS, Kesika P, Chaiyasut C. A review of the role of probiotic supplementation in dental caries. *Probiotics and antimicrobial proteins*. 2020;12:1300-9
3. World Health Organization. Sugars and dental caries. Geneva: WHO; 2017
4. Timmerman A, Parashos P. Management of dental pain in primary care. *Australian prescriber*. 2020;43(2):39
5. Forssten SD, Björklund M, Ouwehand AC. *Streptococcus mutans*, caries and simulation models. *Nutrients*. 2010;2(3):290-8
6. Matos LM, Oliveira LP, Serra MGD, Silva ML. Efeito dos antissépticos com e sem álcool sobre a microbiota oral. *Revista Interdisciplinar*. 2015;8(4):174-80
7. Hajifattahi F, Moravej-Salehi E, Taheri M, Mahboubi A, Kamalinejad M. Antibacterial effect of hydroalcoholic extract of *Punica granatum* Linn. petal on common oral microorganisms. *International journal of biomaterials*. 2016;2016:1-6
8. Palombo EA. Traditional medicinal plant extracts and natural products with activity against oral bacteria: potential application in the prevention and treatment of oral diseases. *Evidence-based complementary and Alternative Medicine*. 2011;2011:1-15
9. Morton JF. *Fruits of warm climates*: JF Morton; 1987
10. Gbile ZO, Soladoye O. *Vernacular names of Nigerian Plants (Yoruba)*. 2nd ed. Ibadan, Nigeria: Forestry Research Institute of Nigeria (FRIN) Press; 2002
11. Osuntokun O. Evaluation of Inhibitory Zone Diameter (IZD) of crude *Spondias mombin* (Linn.) extracts (root, leaf, and stem bark) against thirty infectious clinical and environmental isolates. *J Bacteriol Infect Dis* 2018; 2 (1): 8. 2018;16
12. Ayoka AO, Akomolafe RO, Iwalewa EO, Akanmu MA, Ukponmwan OE. Sedative, antiepileptic and antipsychotic effects of *Spondias mombin* L.(Anacardiaceae) in mice and rats. *Journal of Ethnopharmacology*. 2006;103(2):166-75
13. Rodrigues KF, Hesse M, Werner C. Antimicrobial activities of secondary metabolites produced by endophytic fungi from *Spondias mombin*. *Journal of Basic Microbiology: An International Journal on Biochemistry, Physiology, Genetics, Morphology, and Ecology of Microorganisms*. 2000;40(4):261-7
14. Asuquo O, Oko O, Brownson E, Umotek G, Utin I. Effects of ethanolic leaf extract of *Spondias mombin* on the pituitary-gonadal axis of female Wistar rats. *Asian Pacific Journal of Reproduction*. 2013;2(3):169-73
15. Mazzari AL, Prieto JM. Herbal medicines in Brazil: pharmacokinetic profile and potential herb-drug interactions. *Frontiers in Pharmacology*. 2014;5:162
16. Nworu CS, Akah PA, Okoye FB, Toukam DK, Udeh J, Esimone CO. The leaf extract of *Spondias mombin* L. displays an anti-inflammatory effect and suppresses inducible formation of tumor necrosis factor- and nitric oxide (NO). *Journal of immunotoxicology*. 2011;8(1):10-6
17. Ogunro OB, Yakubu MT. Antifertility effects of 60-day oral gavage of ethanol extract of *Spondias mombin* leaves in guinea pigs: A biochemical, reproductive and histological study. *Asian Pacific Journal of Reproduction*. 2021;10(2):56-67
18. Garga MA, Garasin UM, Abdullahi M, et al. Antibacterial Activity and Phytochemical Screening of *Mangifera indica* Ethanol and Aqueous leaf extracts against *Pseudomonas aeruginosa* and *Staphylococcus aureus*. *International Journal of Research -GRANTHAALAYA*. 2020
19. Mada S, Garba A, Mohammed HAA, Muhammad A, Olagunju A, Muhammad A. Antimicrobial activity and phytochemical screening of aqueous and ethanol extracts of *Momordica charantia* L. leaves. *Journal of Medicinal Plants Research*. 2013;7(10):579-86
20. Lifongo LL, Simoben CV, Ntie-Kang F, Babiaka SB, Judson PN. A bioactivity versus ethnobotanical survey of medicinal plants from Nigeria, West Africa. *Natural products and bioprospecting*. 2014;4:1-19
21. Cordeiro TO, de Mendonca AKP, Gomes MS, et al. Antimicrobial action of hydroethanolic extract of *Spondias mombin* L. against oral bacteria of the genus *Streptococcus*. *Research, Society and Development*. 2021;10(1):1-8
22. Maduka H, Okpogba A, Ugwu C, et al. Phytochemical, antioxidant and microbial inhibitory effects of *Spondias mombin* leaf and stem bark extracts. *J Pharm Biol Sci*. 2014;9(2):14-7
23. Amadi E, Oyeka A, Onyeagba R, Okoli I, Ugbogu O. Studies on the antimicrobial effects of *Spondias mombin* and *Baphia nittida* on dental caries organism. *Pakistan journal of biological sciences: PJBs*. 2007;10(3):393-7
24. Kudi A, Umoh J, Eduvie L, Gefu J. Screening of some Nigerian medicinal plants for antibacterial activity. *Journal of ethnopharmacology*. 1999;67(2):225-8
25. Adeleye I, Omadime M, Daniels F. Antimicrobial activity of essential oil and extracts of *Gongronema latifolium* Decne on bacterial isolates from blood stream of HIV infected patients. *Journal of Pharmacology and Toxicology*. 2011;6(3):312-20
26. de Lima IPA, Alves RAH, Mayer JdSL, et al. Antimicrobial activity of *Spondias mombin* L. aqueous and hydroethanolic extracts on *Enterococcus faecalis* and *Pseudomonas aeruginosa*-an in vitro study. *Research, Society and Development*. 2021;10(1):e50710111949-e

A simplified and evidence-informed approach to designing removable partial dentures.

Part 5. Design examples for Kennedy classifications

SADJ March 2024, Vol. 79 No.2 p92-101

C Peter Owen¹

SUMMARY

For many decades the literature has regularly reported that there is a discrepancy between what is taught in dental school and what is practised, especially in the field of removable partial dentures. Not only that, but for more than 60 years reports from around the world have shown that, usually, the majority of clinicians abdicate their responsibility to design a removable partial denture (RPD) and instead leave this to the dental technician, who has no knowledge of the clinical condition of the patient and works only from a cast. Most patients around the world who require RPDs to improve aesthetics and chewing can only afford a removable prosthesis simply because the majority are poor. But RPDs can improve these aspects and contribute to an improved quality of life.

The purpose of this series of articles is to derive the basic, evidence-informed principles of partial denture design and to suggest a simplified explanation and application of those principles in the hope that clinicians will increasingly take responsibility for the design of partial dentures. Part 1 summarised studies revealing what can only be described as the malpractice of abdication of responsibility for design by clinicians, and then explained the evidence-informed basic principles of design; Part 2 looked at the biomechanical basis of those principles in terms of support; Part 3 did the same for the biomechanical basis of retention; Part 4 provided a simple seven-step approach to design, applied to an example of an acrylic resin-based and a metal framework-based denture for the same partially edentulous arch; and, finally, this part will provide examples of designs for RPDs that have been successfully worn by patients, for each of the Kennedy Classifications of partially dentate arches. Much of this is referenced from an electronic book on the Fundamental of removable partial dentures.¹

Introduction to Part 5

The purpose of these design examples is not to be prescriptive about how a design should look, such as for a particular Kennedy classification. No clinical details have been given, so that some designs are only possible because of favourable occlusions: many times modifications have to be made, for example when an overbite exists. So, these designs are more to provide a suggestion for how a prescription to a dental laboratory might look, and how much information can be conveyed by means of a simple drawing. Although these designs have been produced with a computer drawing package, simple hand drawings are easier to produce and, with practice, clinicians can become very adept at making them quickly; or at least conveying what they need to the dental technician. For the metal-based designs shown here, the darker shading represents the polished portions of the base, and the lighter shaded areas the sand-blasted portions which carry the acrylic base with the replacement teeth. Any cingulum rest seats beneath acrylic or metal are shaded darker. Designs will be given for each main Kennedy classification, with examples using both acrylic and metal bases. All are real-life examples, taken from dentures that are being successfully worn – and used – by patients.¹ They do not preclude other appropriate designs, but it should be noted that if sensible and biological principles of design are adhered to, it turns out that there will, in fact, be limited options available for each clinical situation.

KENNEDY CLASS I

Mandibular

All mandibular distal extension base dentures require indirect retention as well as active retention in the form of clasps on the abutment teeth, as explained in Part 3 of this series.² A recent paper also found a positive association between masticatory performance and the presence of indirect retention.³ There is no evidence that a mesial rest imparts any advantage, and as also explained in Part 3² there is no evidence for the use of the RPI clasp system.

For acrylic bases, a lingual plate is unavoidable. It is possible to purchase stainless steel lingual bars for these cases, but they are unstable and the acrylic over the saddles must be quite bulky; even so, crazing and fractures are common. They are therefore not recommended. The lingual plate will rest against the inclined planes of the incisors, so it is necessary to place cingulum rests to prevent any untoward forward movement of the incisors. It is recommended that good cingulum rest seats be prepared on the canines and smaller ones on the incisors (as there is less enamel on these teeth). The rests on the canines also provide indirect retention. All this will apply also to a metal lingual plate or dental bar as a major connector. The rules for the possible framework-based major connectors are given in the box.

Author's information

CP Owen, Professor Emeritus, Faculty of Health Sciences, University of the Witwatersrand, Johannesburg, South Africa
ORCID: 0000-0002-9565-801

Running title

A simplified approach to designing RPDs

Keywords

Removable partial denture, design, support, retention, acrylic-based, framework-based

Corresponding author

Name: Prof CP Owen
Tel: +27 83 679 2205
Email: peter.owen@wits.ac.za

Conflict of interest

None

RULES FOR FRAMEWORK-BASED MANDIBULAR MAJOR CONNECTORS

Lingual Plate

Location: The superior border is continuous with the cingulum areas of the anterior teeth, or at the lingual survey line of the posterior teeth. The inferior border is at or just superior to the level of the elevated lingual sulcus. The apron extends interproximally to the height of the contact.

Indications: As this covers all gingival margins, it should be avoided and is used only when there is insufficient space for a lingual bar, a Kennedy bar or the alignment of the teeth precludes the use of a dental bar. It may perhaps be useful if there is the possibility of future loss of anterior teeth, though in this case an acrylic base would be more sensible.

Lingual Bar

Location: Superior border at least 2mm from the gingival margin. Inferior border at the level of the elevated (functional) lingual sulcus.

Indications: Sufficient space between the elevated lingual sulcus and the lingual gingival tissues. This is the connector of choice if there is at least 8mm between the gingival margins and the lingual sulcus.

Shape and size: Half tear-drop shaped, bulkiest portion inferiorly; superior border tapered, at least 6mm in height. Very occasionally a short bar passing only two or three teeth can be thinner, but must be at least 4mm in height.

Kennedy Bar (Lingual Bar and Continuous dental bar)

Location: Lingual bar: superior border at least 2mm from the gingival margin. Inferior border at the level of the elevated (functional) lingual sulcus. Dental bar: continuous bar along the cingula of the anterior teeth and lingual surfaces of premolars.

Indications: When there is insufficient room for a normal lingual bar (ie less than 8mm), usually as a result of gingival recession. But there must be at least 6mm between the gingival margins and the lingual sulcus. The alignment of the teeth must allow for the use of a dental bar.

Shape and size: Dental bar 3mm in height, tapers to tooth superiorly and inferiorly. Because the lingual bar forms part of a double bar it can be thinner. It should still be the same shape (half tear-drop shaped, bulkiest portion inferiorly; superior border tapered) and 4mm in height.

Dental Bar

Location: A continuous bar along the cingula of the anterior teeth.

Indications: When there is insufficient room for a lingual bar or a Kennedy bar. Tooth alignment must be favourable.

Shape and size: 4-6mm in height, depending on the size of the teeth, tapers to tooth superiorly and inferiorly. Must be thick enough for adequate rigidity, depending on length.

Sublingual Bar

Location: Occupies the width and depth of the lingual sulcus. Of academic interest only, as the other alternatives always provide a valid solution. The impression is difficult to make and this connector requires high adaptability on the part of the patient.

Whatever the base material used, the evidence is that these dentures are not easy to use, but there is little evidence to explain why, and the few follow-up surveys have shown contrasting results. After 8-9 years, one study found that 24% of mandibular Class I dentures were no longer being worn;⁴ whereas another study found that there was a 7% loss over 10 years and a 31% loss over 20 years (but the observation period was from 3 to 36 years).⁵ There is, however, some correlation between some features of these dentures when having been worn successfully, and which were important in preserving health, and those are:⁶

- the presence of positive occlusal and/or cingulum rests
 - the presence of guide plane/guiding surface contact on the abutment teeth
 - extension of the distal extension base onto the retromolar pad and over the buccal shelf to the buccal vestibule
 - placing rests on 2 or more teeth adjacent to each distal extension.
- It is important to bear these features in mind, especially that of the denture base over the distal extension, as so many encountered are underextended. It is useful to think of the denture base that extends from the abutment tooth posteriorly as being the equivalent of what a complete denture would be in that same area.

DESIGN EXAMPLES

Mandibular

Figures 1-2 show typical examples of acrylic-based and framework-based mandibular distal extension partial dentures.

If there is insufficient room for a lingual bar, then an alternative design well accepted by patients (again, if there is sufficient room) is the Kennedy bar, as in Figure 3.

Maxillary

There are differing opinions, not often expressed in the literature, and certainly without evidence, as to whether indirect retention is required in maxillary distal extension bases. The issue is whether you believe the distal part of the denture will fall down either under gravity or during chewing.

The answer may lie in what happens in a complete denture. Patients who wear and use complete dentures successfully appear to use their tongue quite differently: the posterior part rises to contact the posterior half of the maxillary denture, and the mandibular denture is controlled by the tongue sitting comfortably behind and in contact with the mandibular incisors. This has been shown to increase the retention and stability of the mandibular complete denture.⁷ It is reasonable to assume that the same will apply to distal extension bases. In general, then, the (albeit anecdotal, experiential) advice is that indirect retention is unlikely to be required in a maxillary distal extension base denture.

Design examples

Figure 4 shows a typical design for a maxillary Class I acrylic-based denture. There is a cingulum rest on the 13

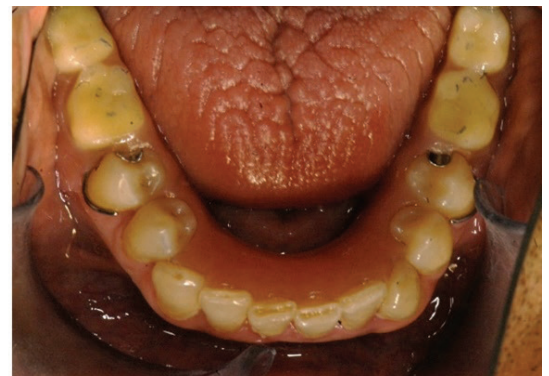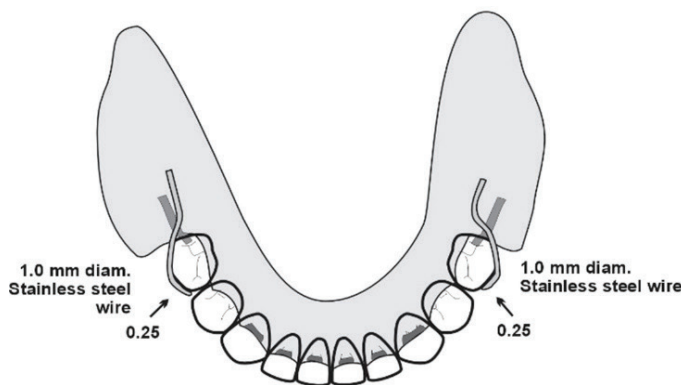


Figure 1. The drawing, and the denture in the mouth for an acrylic-based denture. Note that there are rest preparations on the canines and all incisors. The undercut of 0.25mm is appropriate for the wrought wire clasps.

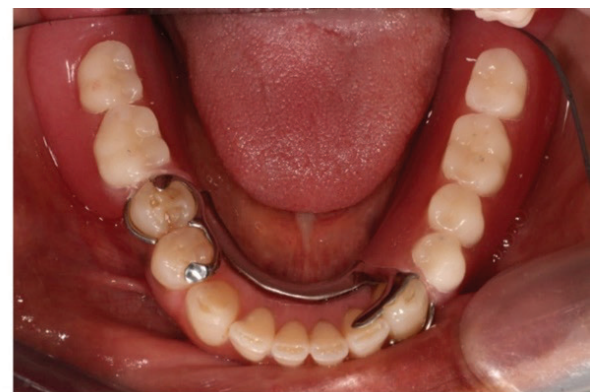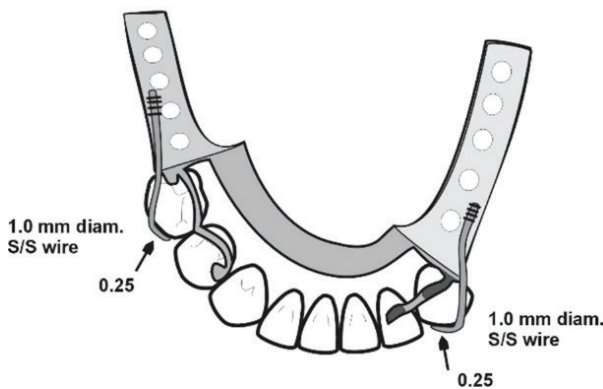


Figure 2. The drawing, and the denture in the mouth for a metal-based denture. Cingulum rests are on the 33 and 32, which provides indirect retention, as does the mesial rest on 44. Wrought wire has been used for the clasps because of their length; the wire is soldered or welded to the metal framework (depicted by the small cross-lines).

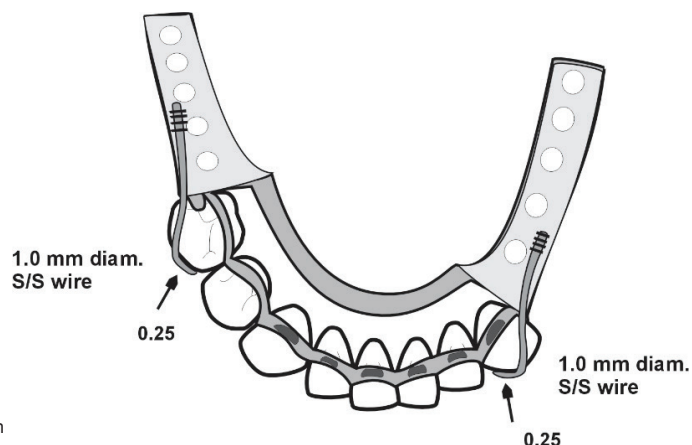


Figure 3. An alternative design for the case in Figure 2, using a Kennedy bar. Rest seats are on the canines and all incisors.

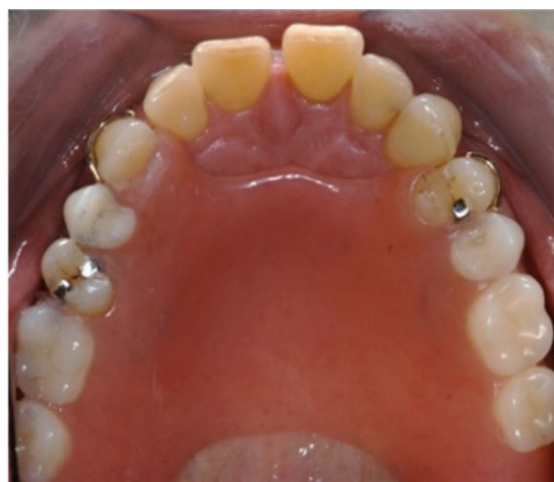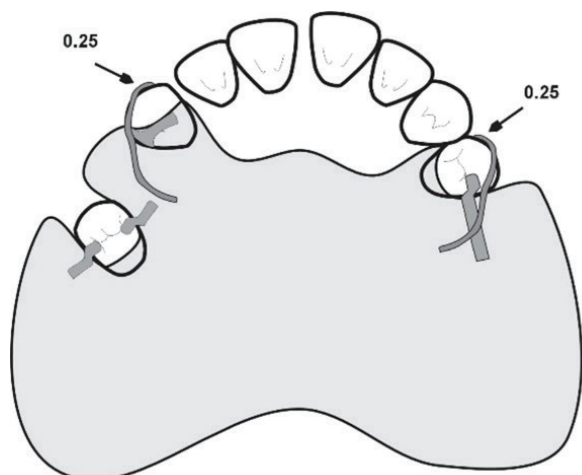


Figure 4. The drawing, and the denture in the mouth for an acrylic-based denture. Note that it is not necessary to festoon the denture around all the teeth – that would be unnecessary gingival coverage and potentially iatrogenic. Note also that the lone standing premolar has both mesial and distal rests. This ensures that this somewhat periodontally susceptible tooth is protected and is a good rule of thumb for all lone standing teeth.

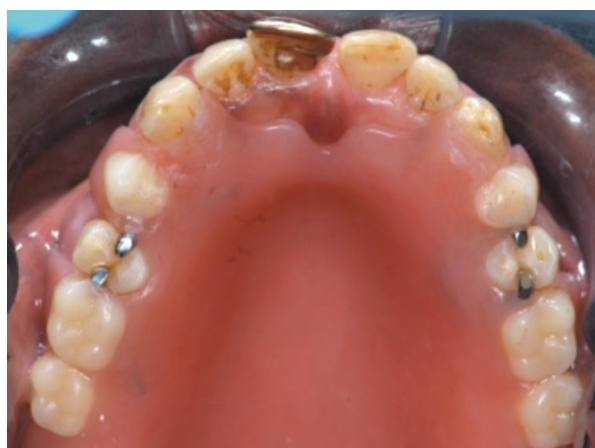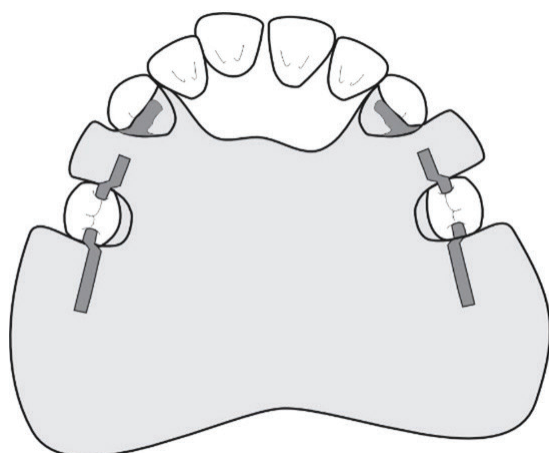


Figure 5. The drawing, and the denture in the mouth for an acrylic-based denture without clasps.

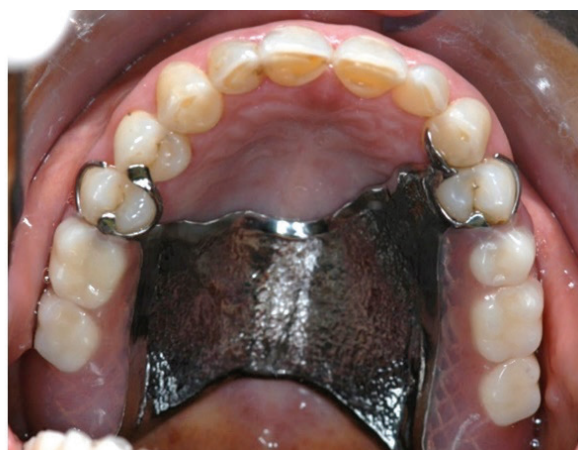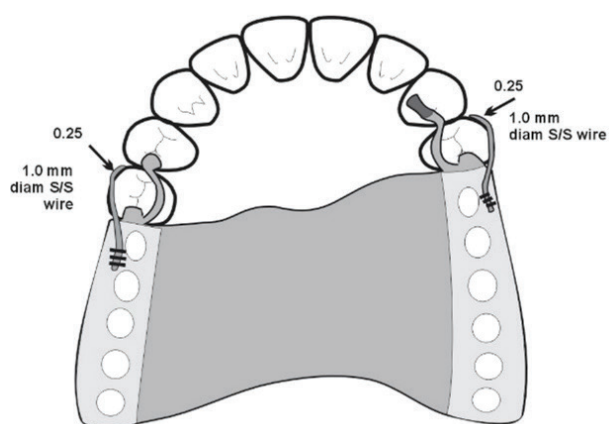


Figure 6. The drawing, and the denture in the mouth for the metal-based denture.

which will be continuous with the guide plane. The clasps will, unfortunately, be visible if the patient has a high smile line. Where sufficient guide planes can be made, and the guiding surfaces are refined in the mouth, clasps may not be necessary, as shown in Figure 5.

The metal-based denture shown in Figure 6 does have indirect retention by extending onto the 14 and the 23.

KENNEDY CLASS II Mandibular

The principles elucidated above apply to unilateral distal extension bases as well, but the design requires cross-arch stabilisation as well as retention, which makes acrylic-based dentures a lot bulkier than their framework-based counterparts. When there is a modification space, that makes the design a little easier.

Design examples
Mandibular

Figure 7 shows a typical design for a Kennedy Class II acrylic-based denture and Figure 8 shows a design when there is no modification space in the opposing arch. Figure 9 shows a typical metal-based design and Figure 10 shows a variation to reduce gingival coverage.

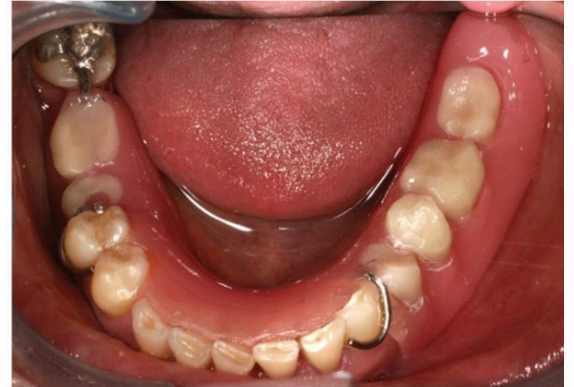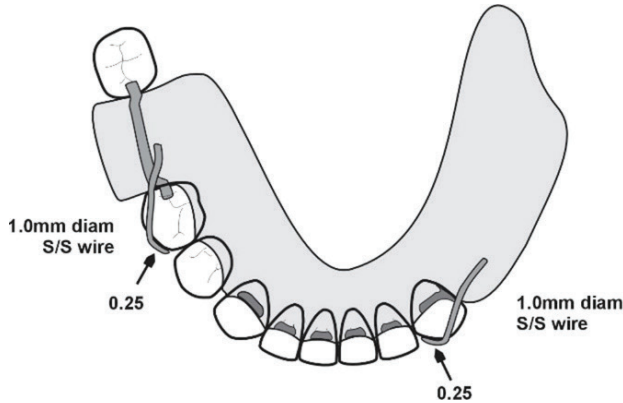


Figure 7. The drawing, and the denture in the mouth for an acrylic-based denture. As with the Class I situation, the lingual plate requires cingulum rests. If there is no modification space in the opposing arch, then a typical design would be as in Figure 8.

Figure 8. A design for a Kennedy Class II acrylic-based denture with no modification spaces. The decision has to be whether to engage the distal or mesial undercut. Because any rotation caused by lifting of the distal extension base needs to be counteracted, it seems sensible to engage the distal undercut. Note that the clasp also acts a rest, as it passes between the 45 and the 46.

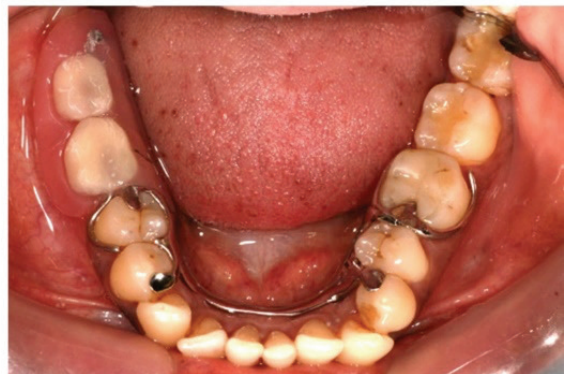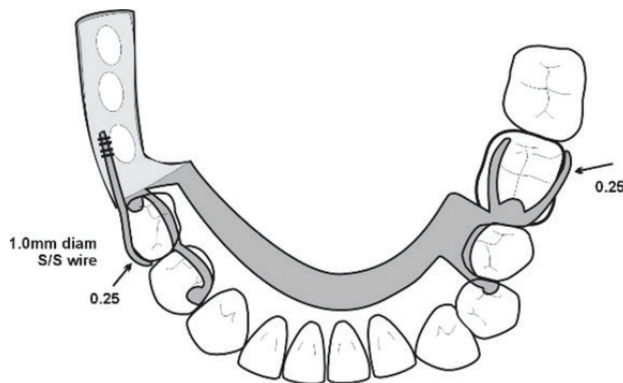
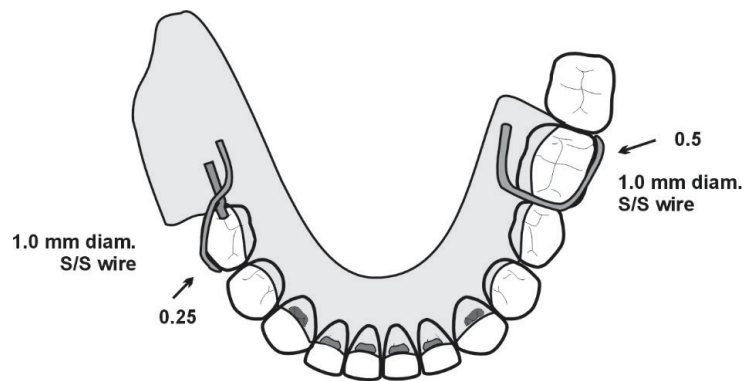
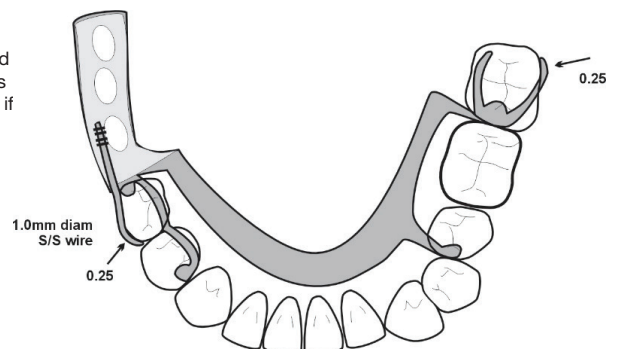


Figure 9. The drawing, and the denture in the mouth for a metal-based denture. As with the acrylic-based design with no modification space, the distal undercut is engaged. There is, though, gingival coverage of the 35 because of the need to place a rest on the 34 to ensure a distribution of rests for stability. This gingival coverage can be corrected as in Figure 10.

Figure 10. The design from Figure 9 can be modified to ensure no gingival coverage. In this case the 37 is clasped so that more than one tooth is uncovered – if just one tooth is left open there is the real danger of hyperplasia of the gingiva.



Maxillary

Once again, the same principles apply, as illustrated in Figures 11-13.

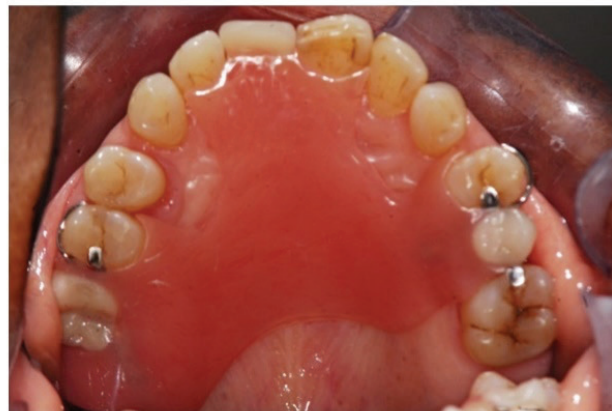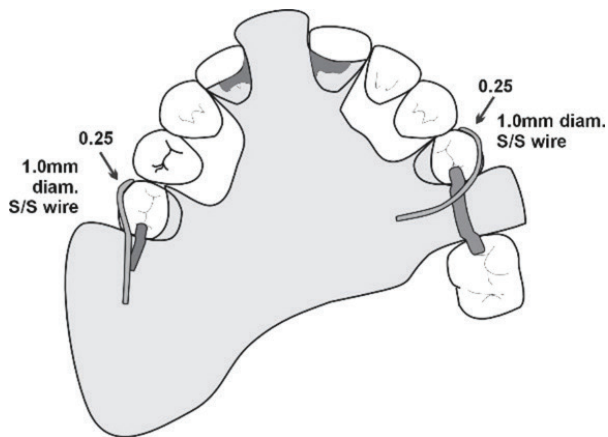


Figure 11. The drawing, and the denture in the mouth for an acrylic-based denture. The cingulum rests (which also provide indirect retention) will be continuous with the guide planes. The clasp on 15 is necessary but may show depending on the patient's smile. The clasp on the 14 will almost certainly show, and so a better aesthetic design is that shown in Figure 12.

Figure 12. An alternative design for the case shown in Figure 11. An additional benefit is that there is cross-arch reciprocation of clasps, with a mesial undercut engaged on the one side and a distal undercut engaged on the other.

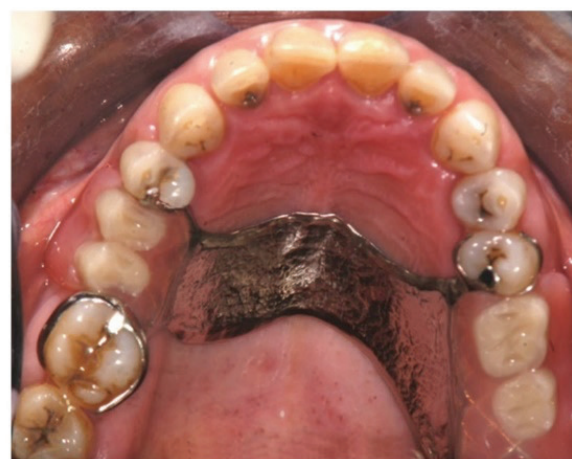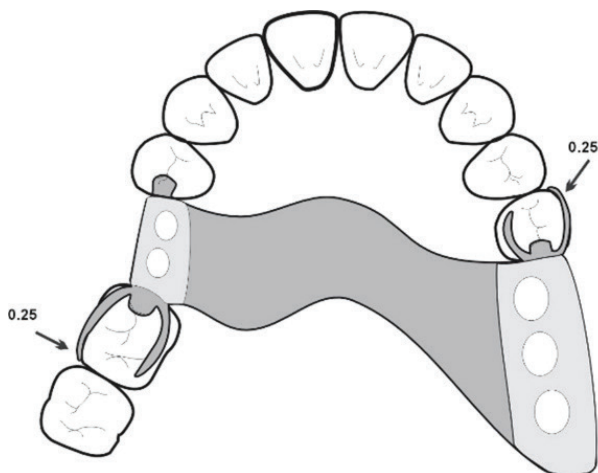
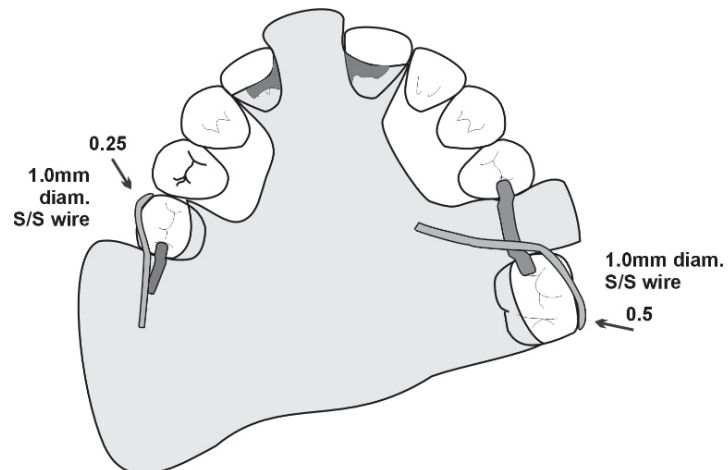


Figure 13. The drawing, and the denture in the mouth for a metal-based denture. Once again, cross-arch reciprocation of the clasps is an added benefit. No indirect retention was considered necessary.

KENNEDY CLASS III

The design for these dentures should be comparatively easy and can be kept simple, though they are often overly complicated. Depending on the number of edentulous spaces, and the size and length of the guide planes, many Class III dentures can rely on guide plane retention without the need for clasps.

Mandibular

As with all acrylic-based dentures, covering many gingival margins is unavoidable. Posterior spaces are often difficult because a lone standing distal molar is often left, and tends to tip mesially (because of the space) and often lingually (under the influence of the masseter). Therefore, there is usually no buccal undercut region and so these teeth can seldom be clasped; but they must of course receive a rest and will require slightly more modification than usual to create a guide plane.

Design examples

Figure 14 shows a typical design for an acrylic-based denture and Figure 15 illustrates that with enough guide planes, clasps may not be necessary. Figure 16 shows a typical framework-based design.

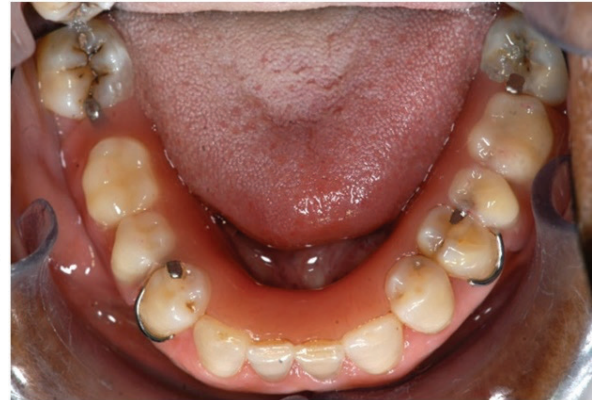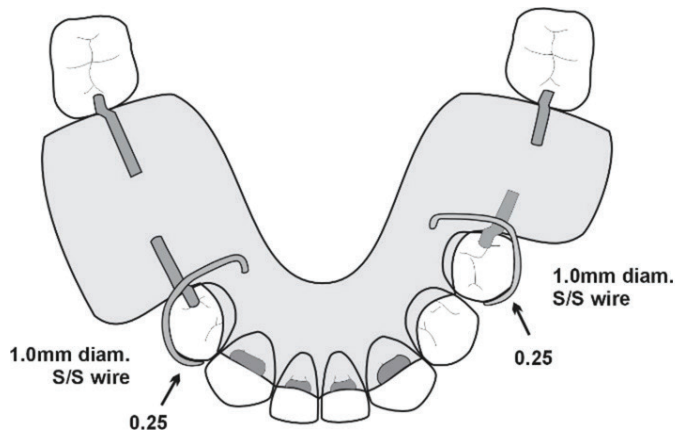


Figure 14. The drawing, and the denture in the mouth for an acrylic-based denture. The molars are not clasped because they are tilted and have no buccal undercuts.

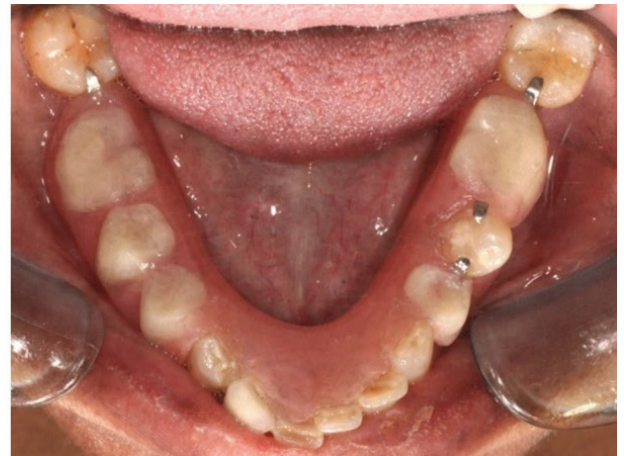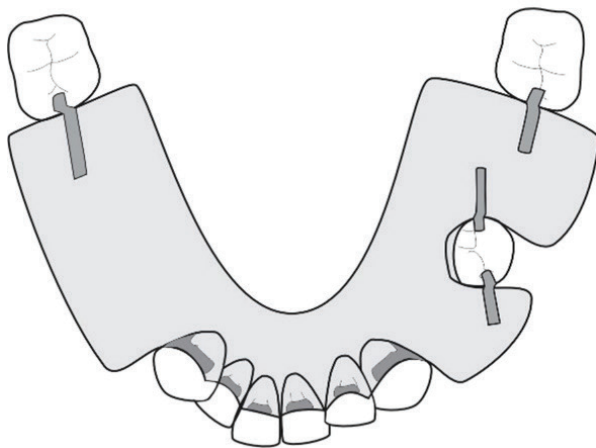


Figure 15. The drawing, and the denture in the mouth for an acrylic-based denture that was deemed to have sufficient number and size of guide planes as to obviate the need for clasps. The lone standing premolar must always receive both mesial and distal rests.

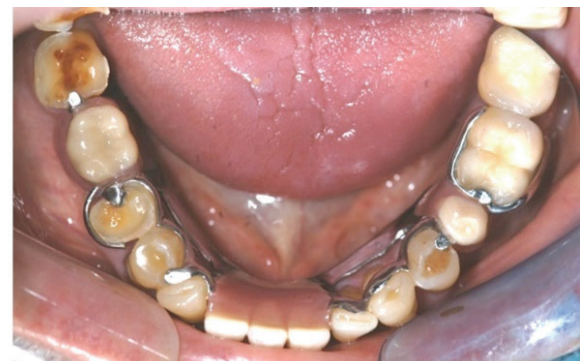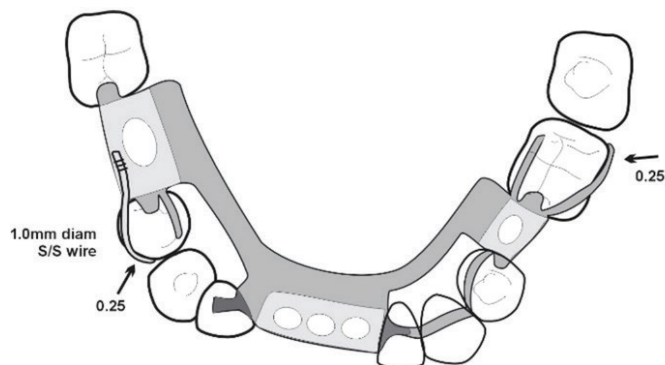


Figure 16. The drawing, and the denture in the mouth for a metal-based denture. This is a somewhat complicated design, but was necessary to avoid using lingual plates. The result is that no gingival margins are covered.

Maxillary

As with the mandibular designs, the maxillary Class III denture designs will depend entirely on the form and number of edentulous spaces. The more spaces there are, the more obvious the design will be because of the design principles such as the need for support on either side, the need for guide planes etc.

Design examples

Single edentulous space examples have been chosen here because they illustrate the need to consider where support should be placed, and the need for active retention (Figures 17-19).

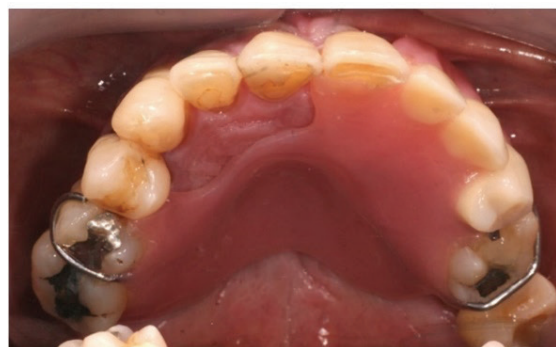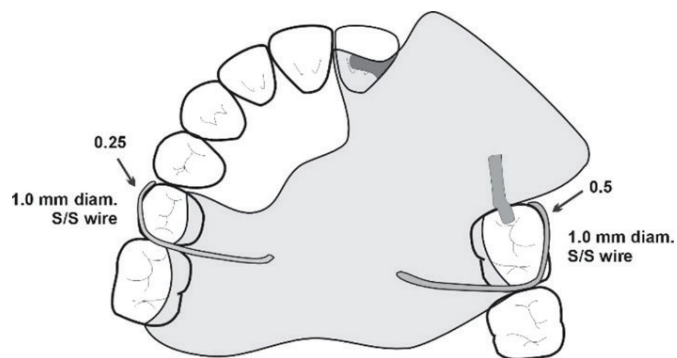


Figure 17. The drawing, and the denture in the mouth for an acrylic-based denture. The saddle is mostly anteriorly placed, and so its rotation must be considered, hence the use of mesial undercuts for the clasps, which also act as rests as they pass over the embrasures.

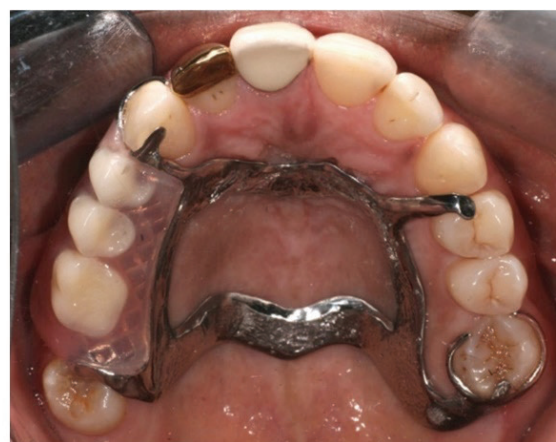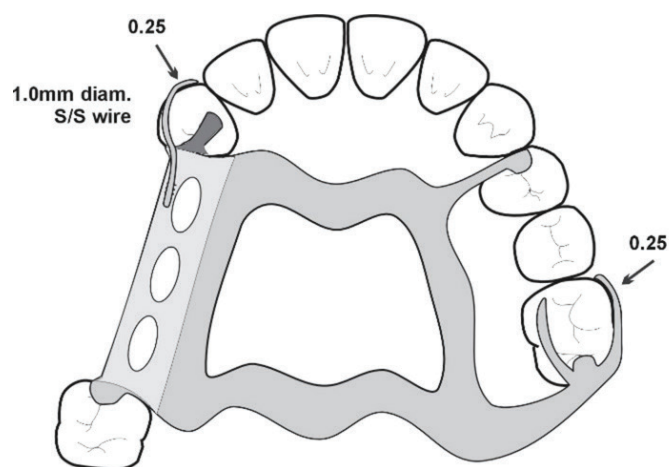


Figure 18. The drawing, and the denture in the mouth for a metal-based denture. The rest on the 24 is necessary for stability. Even though the rests on the right side and on the 26 form a tripod, it should be clear that it will not be as stable as including a rest on the 14.

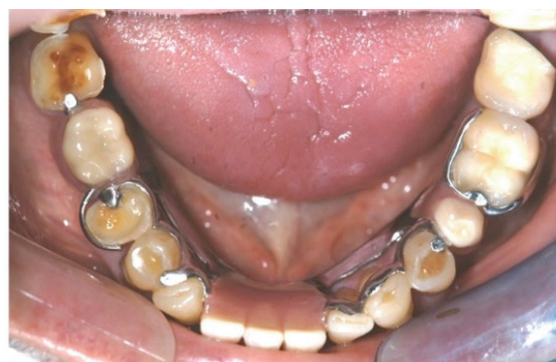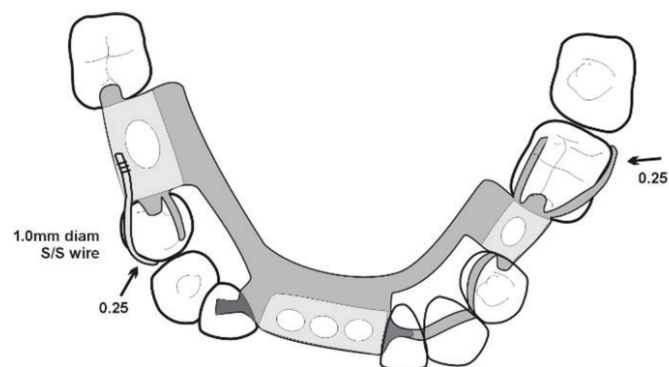


Figure 19. The drawing, and the denture in the mouth for a metal-based denture without clasps.

KENNEDY CLASS IV Mandibular

As discussed in Part 3² the design of these dentures depends entirely on whether the clinician believes that the predominant displacing action is a rotation of the anterior part downwards and forwards from incising or upwards from chewing sticky foods. Once again there is only anecdotal and experiential evidence, and that advice is that these dentures tend to tip up posteriorly, not anteriorly, and hence the use of distal undercuts for the clasps. The designs are therefore straightforward, and once again the difference between an acrylic base and a framework base is the gingival coverage.

Design examples Mandibular

Figures 20 and 21 show typical designs for acrylic-based and framework-based dentures.

Maxillary

The rotation of these dentures is always considered as downwards from the anterior generally because of the poor guide planes anteriorly. But when the guiding surfaces on the denture are developed in the mouth, the retention of the anterior segment greatly improves. The retention is also improved by using the mesial undercuts of the distal most appropriate tooth (Figures 22-23).

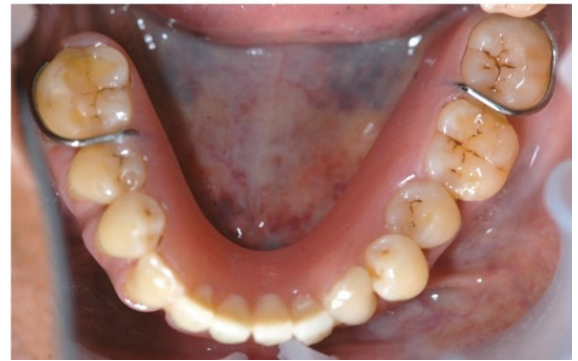
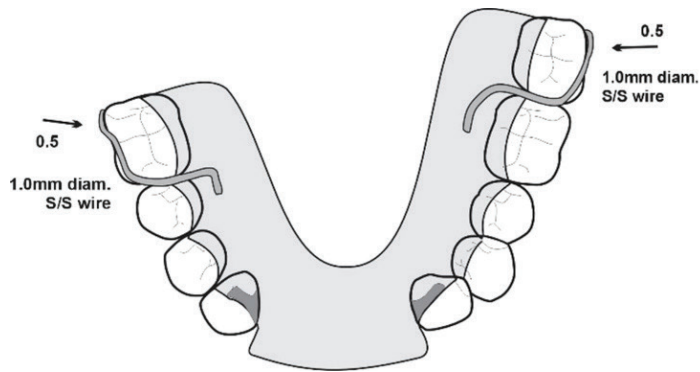


Figure 20. The drawing, and the denture in the mouth for an acrylic-based denture.

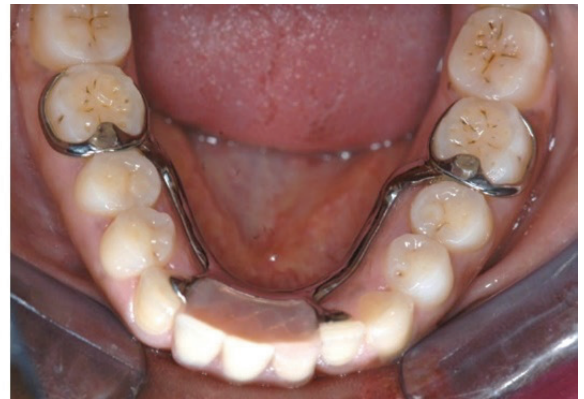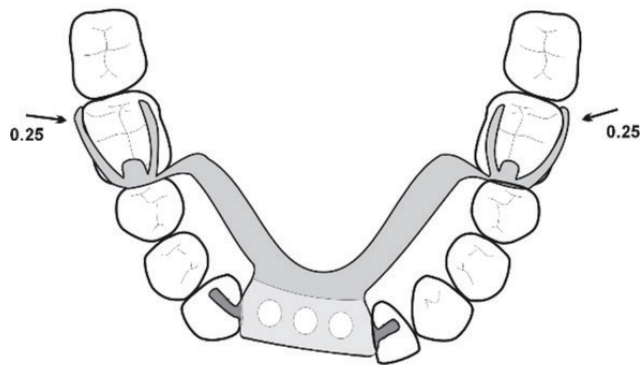


Figure 21. The drawing, and the denture in the mouth for a metal-based denture.

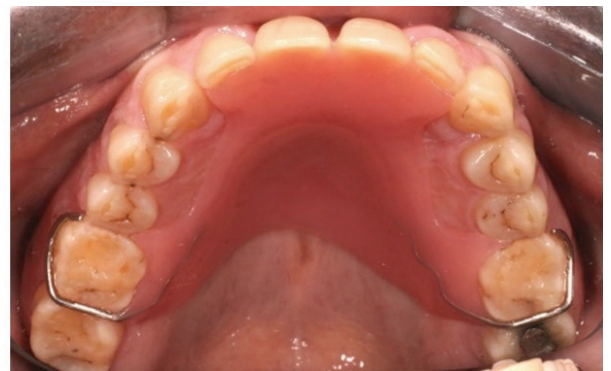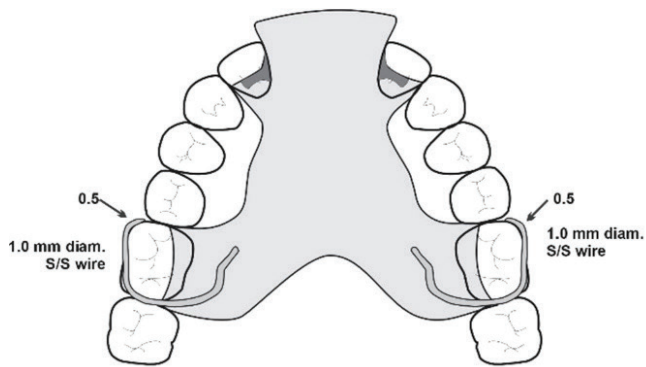


Figure 22. The drawing, and the denture in the mouth for an acrylic-based denture. Note that it is not necessary to festoon the acrylic around all the teeth, but only the teeth with cingulum rests (the lateral incisors in this case) and the teeth being clasped, to provide reciprocation. The clasps also act as rests as they sit in the embrasure.

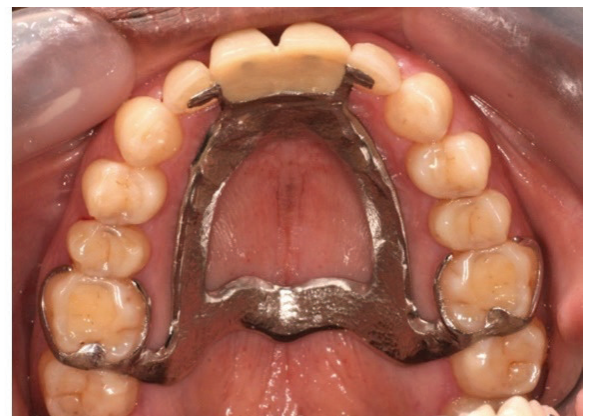
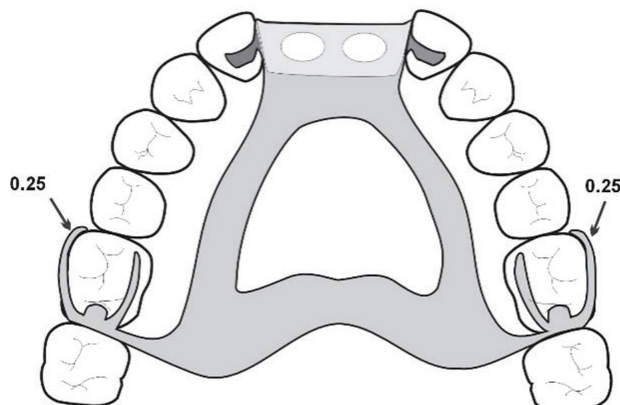


Figure 23. The drawing, and the denture in the mouth for a metal-based denture for a similar case as Figure 22, with two missing central incisors.

DISCUSSION AND CONCLUSION TO THE SERIES

There are, of course, many more aspects to the design and use and making of removable partial dentures, but these papers were intended to try to simplify many of the somewhat confusing aspects of partial denture design to be found in the literature, and deliberately concentrated on the basic forms of acrylic-based and framework-based dentures, with no other support such as from implants. These are the partial dentures that are available to most patients worldwide. There is a paucity of evidence for any specific design features, and in fact there is evidence to the contrary for some long-held beliefs such as that torquing forces and clasp assemblies result in the loss of teeth.

There are many factors that contribute to the increased rate of tooth loss among partial denture wearers, but if simple and hygienic designs are used, the denture itself is unlikely to contribute. Although it has been shown that the amount of bone support prior to receiving an RPD was not a risk factor,⁸ this has been contradicted by other studies investigating the crown-root ratio of abutment teeth;^{9,10} all such studies, though, point to what are really multiple biological factors such as occlusal support, root canal treatment and alveolar bone density. There is little doubt, though, that the greatest single contributor to tooth loss in RPD wearers is insufficient plaque control, and it should be a *sine qua non* that no prosthesis should be placed in a patient who cannot control biofilm through their own oral hygiene measures as well as with professional help.

There is also little doubt that RPDs contribute to patients' quality of life, especially when they fulfill the needs for aesthetics and improved chewing, and even in the presence of periodontal disease.¹¹ As discussed in Part I¹² there may be some association between chewing and cognition and a recent study suggested that the use of dental prostheses might be a protective factor for cognitive decline.¹³ It has even been suggested that the use of RPDs may have

long-term benefits in reducing mortality, although it was acknowledged that further research is necessary.¹⁴

The majority of partially edentate people in the world will not be able to afford a fixed or implant-supported prosthesis merely because the majority of people in the current world order are poor. The removable partial denture will continue to have a place in the therapeutic regimen and it is hoped that this series of papers will encourage better designed, non-iatrogenic prostheses for everyone who needs them.

REFERENCES

1. Owen CP. 2020. Fundamentals of removable partial dentures, 5th Edition. Electronic book available at www.appropriatech.com
2. Owen CP. A simplified approach to removable partial dentures. Part 3. The biomechanical basis of retention. SADJ. 202?
3. Yoshimoto T, Hasegawa Y, Maria MTS, Marito P, Salazar S, Hori K, et al. Effect of mandibular bilateral distal extension denture design on masticatory performance. J Prosthodont Res. 2023 4. doi: 10.2186/jpr.JPR_D_22_00135. Epub ahead of print
4. Chandler JA, Brudivik JS. Clinical evaluation of patients eight to nine years after placement of removable partial dentures. J Prosthet Dent. 1984;51(6):736-43. doi: 10.1016/0022-3913(84)90366-4
5. Yoshino K, Ito K, Kuroda M, Sugihara N. Survival Rate of Removable Partial Dentures with Mandibular Bilateral Free End Saddle: A Retrospective Study. Bull Tokyo Dent Coll. 2021;62(4):205-14. doi: 10.2209/tdcpublication.2020-0061
6. Frank RP, Brudivik JS, Leroux B, Milgrom P, Hawkins N. Relationship between the standards of removable partial denture construction, clinical acceptability, and patient satisfaction. J Prosthet Dent. 2000;83(5):521-7. doi: 10.1016/s0022-3913(00)70008-4
7. Lee JH, Chen JH, Lee HE, Chang HP, Chen HS, Yang YH, Chou TM. Improved denture retention in patients with retracted tongues. J Am Dent Assoc. 2009;140(8):987-91. doi: 10.14219/jada.archive.2009.0308
8. Nisser J, Kisch J, Chrcanovic BR. Risk Factor Assessment for Survival of Removable Partial Dentures and Their Abutment Teeth: A Retrospective Analysis. Int J Prosthodont. 2022;35(5):598-608. doi: 10.11607/ijp.7457
9. Tada S, Ikebe K, Matsuda K, Maeda Y. Multifactorial risk assessment for survival of abutments of removable partial dentures based on practice-based longitudinal study. J Dent. 2013;41(12):1175-80. doi: 10.1016/j.jdent.2013.07.018
10. Watanabe C, Wada J, Mizutani K, Nagayama T, Uchida H, Shibata Y, Wakabayashi N. Radiographic predictive factors for 10-year survival of removable partial denture abutment teeth: Alveolar bone level and density. J Prosthodont Res. 2023;67(3):437-43. doi: 10.2186/jpr.JPR_D_22_00034
11. Gotfredsen K, Rimborg S, Stavropoulos A. Efficacy and risks of removable partial prosthesis in periodontitis patients: A systematic review. J Clin Periodontol. 2022;49 Suppl 24:167-81. doi: 10.1111/jcpe.13519
12. Owen CP. A simplified approach to removable partial dentures. Part 1. Evidence-informed design principles. SADJ. 202?
13. Bof de Andrade F, de Oliveira C, de Oliveira Duarte YA, Sabbah W, Bernabé E. Tooth loss, dental prostheses use and cognitive performance in older Brazilian adults: The SABE cohort study. Geriatr Gerontol Int. 2021;21(12):1093-98. doi: 10.1111/ggi.14290
14. Bashir NZ, Bernabé E. Removable partial dentures and mortality among partially edentulous adults. J Dent. 2022;126:104304. doi: 10.1016/j.jdent.2022.

CPD questionnaire on page 120

The Continuing Professional Development (CPD) section provides for twenty general questions and five ethics questions. The section provides members with a valuable source of CPD points whilst also achieving the objective of CPD, to assure continuing education. The importance of continuing professional development should not be underestimated, it is a career-long obligation for practicing professionals.



Oral health in children and adolescents with special healthcare needs in South Africa: A narrative review

SADJ March 2024, Vol. 79 No.2 p102-108

N Njoroge¹, A Magan², P Hlongwa³

INTRODUCTION

Children and adolescents with special healthcare needs (CWSHCN) may experience disproportionately poorer general and oral health than healthy children.¹⁻³ They are more at risk of common conditions such as dental caries and gingivitis resulting from poor oral health.⁴ They comprise of children and youth “with or at risk of chronic physical, developmental, behavioural or emotional conditions”,⁵ including, inter alia, intellectual disability (ID), cerebral palsy (CP), learning disability (LD), autism spectrum disorder (ASD), hearing impairment (HI), Down Syndrome (DS), physical disabilities (PD), visual impairments (VI) and epilepsy (EP). Globally, the prevalence of disabilities is increasing, even in developing countries such as South Africa (SA), resulting in a greater burden on healthcare systems.⁶

The 2011 World Health Organisation (WHO) report estimated that 15% of the global population had a disability. There was a slightly higher prevalence of individuals with disabilities in developing countries than in developed countries.⁷ Among children aged 0-14 years and those above 15 years, 5.1% or 93 million and 19.4% or 892 million had a moderate or severe disability, respectively. Due to the lack of current epidemiological data, there are no accurate figures of children with disabilities in SA. However, the 2011 census in SA found that about 609,671 children aged between 5-14 years had a disability.⁸

Individuals with developmental disabilities such as ASD are more likely to develop oral diseases compared to typically developing children.⁹ Poor dietary choices and between meal consumption of sugars increase the risk for dental caries,¹⁰ while inadequate oral hygiene additionally increases the susceptibility for gingivitis. Children with ID may lack the cognitive and/or manual dexterity to perform oral hygiene independently, while uncooperative behaviour

makes routine oral hygiene practices difficult for the parent/caregiver. Furthermore, medication such as phenytoin, an anticonvulsant drug used in children with epilepsy, may predispose to gingival hypertrophy¹¹ and impede proper plaque control. Caries risk also increases in the presence of developmental defects of enamel and enamel hypoplasia that may be present in young patients with CP.¹²

Poor oral health can negatively impact general health, especially in children with disabilities.¹³ When left untreated, dental caries leads to chronic pain, infection, sleep disruption, premature tooth loss and poor weight gain as the child cannot feed properly, which may impact growth and development.¹⁴ Dental infections resulting from poor oral health also pose a risk for bacteraemia and potential life-threatening septicaemia, especially in immunocompromised children.¹⁵ Mostly, the oral health management of CWSHCN is performed under general anaesthetic. The time and cost associated with treatment under general anaesthesia puts additional strain on the healthcare system, especially in developing countries.¹⁶ Furthermore, there is an associated economic burden on families related to the cost of treating oral diseases,¹⁷ more so for CWSHCN with additional healthcare needs.

Despite the adverse consequences of poor oral health, globally CWSHCN are likely to encounter barriers to dental care services.¹⁸ In addition, factors related to the severity of the child's disability and the family's socioeconomic level may limit access to non-preventative dental care.¹⁹ In SA, the lower socioeconomic groups suffer from a greater burden of ill-health and disability and are less likely to use health services.²⁰

Understanding the characteristics and status of oral health among CWSHCN helps to reveal their needs more specifically and address any barriers to dental care. In the area of oral health for individuals with disabilities, only a few studies have been conducted in SA, a country which has significant health inequalities.²¹ Thus, the aim of this review was to describe the characteristics and status of oral health among CWSHCN in SA. The study forms part of a PhD programme for the principal investigator (NN).

MATERIALS AND METHODS

Search strategy

A literature review was conducted based on the PRISMA 2020 statement for systematic reviews.²² An internet-based search was performed for the articles published between January 1 2002 and August 31 2023. This period was chosen as the last SA National Children's Oral Health survey (NCOHS) was conducted two decades ago (1999-2002).²³ Notably, CWSHCN were not included in the survey. The keywords used were: oral health, dental caries, children/adolescents and South Africa. The following electronic

Authors' information

1. Dr Nancy Njoroge, BDS, MDS (Paed Dent), Department of Orthodontics, School of Oral Health Sciences, Faculty of Health Sciences, University of the Witwatersrand, Johannesburg, South Africa
ORCID: 0009-0000-3693-9405
2. Dr Ansuyah Magan, BSc (Hons), BDS, MSc (Dent), PhD (Paed), SAMRC/Wits Developmental Pathways for Health Research Unit, Department of Paediatrics, School of Clinical Medicine, Faculty of Health Sciences, University of the Witwatersrand, Johannesburg, South Africa
ORCID: 0000-0001-9183-6476
3. Prof Phumzile Hlongwa, BOH, BDS, MDent (Ortho), FCD (Orthod), PhD, Department of Orthodontics, School of Dentistry, Faculty of Health Sciences, University of Pretoria, South Africa
ORCID: 0000-0002-8052-9275

Corresponding author

Name: Dr N Njoroge
Email: Nancy.Njoroge@wits.ac.za

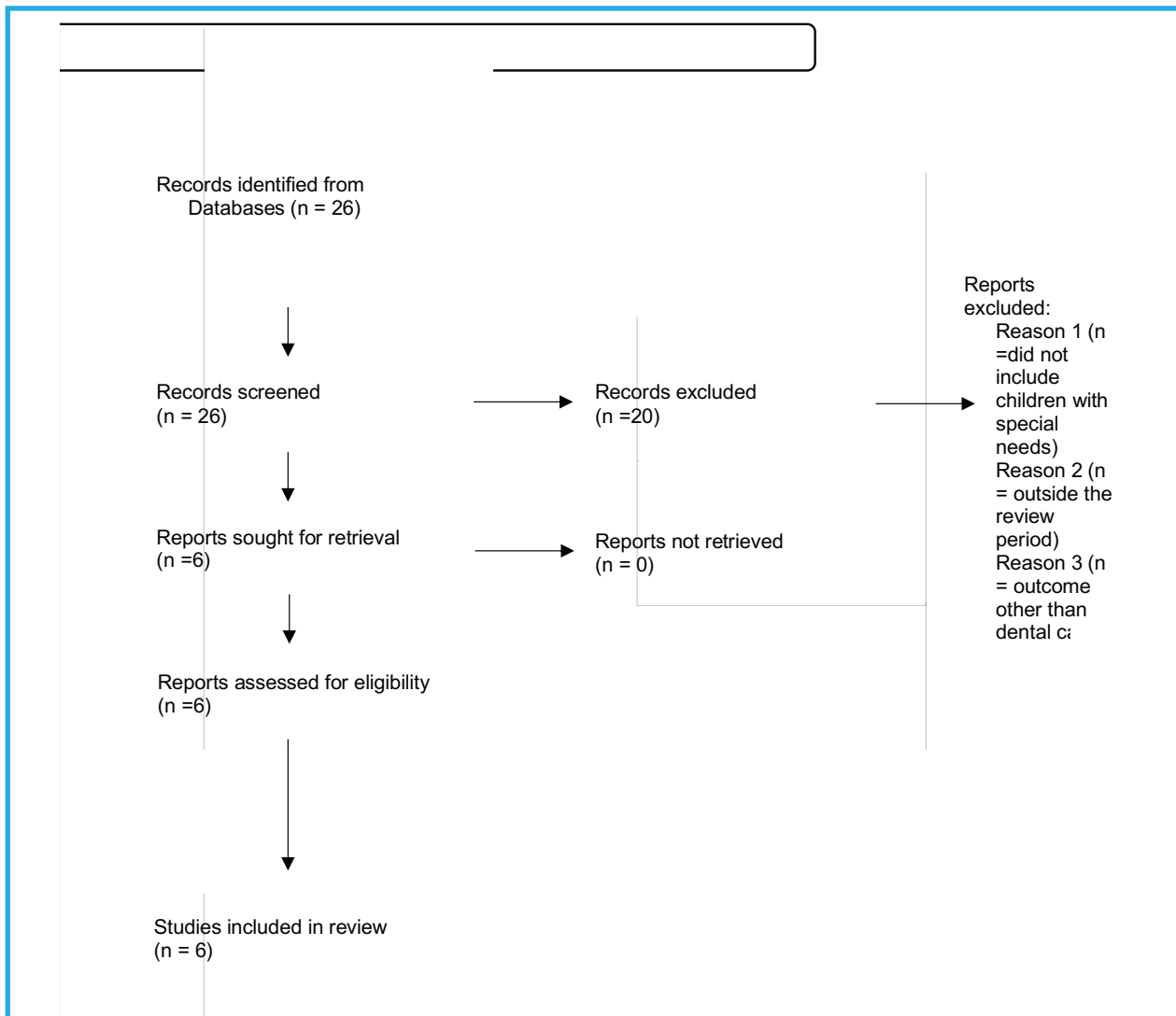


Figure 1. PRISMA 2020 statement flow diagram for selection of studies.

databases were searched for studies that met the eligibility criteria for this review: MEDLINE, PubMed, SCOPUS.

Eligibility criteria

The eligibility of potential studies was determined by reading the title and abstracts of each article identified by the search engine. All articles that appeared to meet the inclusion criteria based on their abstracts were selected and collected. Full-text articles were obtained for manuscripts with missing abstracts or those in which insufficient relevant information was found in the published abstract. Reference lists of the included studies were also screened for potentially relevant research. The final selection was independently carried out by the principal investigator (NN) and the co-authors after reading the complete articles and the results were compared for agreement. Studies were eligible for inclusion if they met the following criteria: (a) performed in SA, (b) children and/or adolescents with special health needs/disability, (c) assessed oral health by quantitative measurement or qualitatively as reported by a parent or caregiver, (d) the decayed, missing and filled teeth index (dmft for primary and DMFT for secondary teeth) was used to assess caries severity. Only articles published in English were included. Unpublished manuscripts and grey literature were excluded. The results of the search, selection process and the number of studies included and excluded at each stage are shown in Figure 1.

Table I: Data extraction tool

Author(s)	
Year of study	
Study objective	
Study setting	
Study design	
Study population and sample size	
Type of SHCN/disability	
Key findings	
Critique	

Ethical considerations

Approval to conduct the study was obtained from the University of Witwatersrand Human Research Ethics Committee (Clearance number M220266).

STUDY FINDINGS

Characteristics of the identified studies

A total of 26 articles were retrieved, 20 of which did not meet the eligibility criteria. The reasons for excluding these articles were (i) participants were not CWSHCN, (ii) the study was conducted outside the review period or (iii) outcome other than dental caries. The six studies that were included in this review were cross-sectional in design and most participants

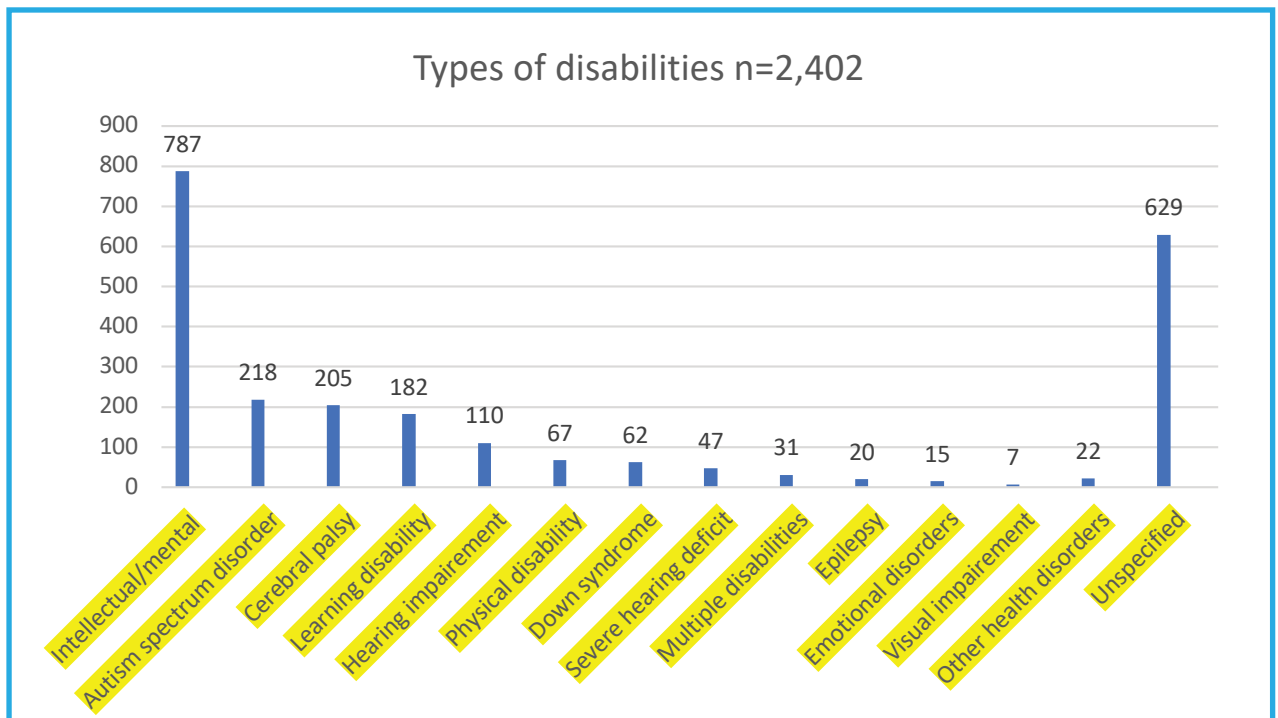


Figure 2. Types of disabilities among CWSHCN.

were from public special needs schools. The studies were conducted in urban and peri-urban settings except for one in a rural setting, thereby representing different socioeconomic backgrounds of the study participants in SA.²⁵

Characteristics of the study participants

A total of 2,402 individuals with special healthcare needs were included in the review, 59.7% (n=1,433) of whom were male and 40.3% (n=969) were female. The age of the children ranged between 0 and 20 years. One study used caregivers of CWSHCN as a proxy of their child's oral health status.²⁶

Types of disabilities

The types of disabilities varied across the studies. Among the disabilities included, inter alia, ID/MD n=787, CP n=205, LD n=182, ASD n=218, HI n=110, PD n=67, DS n=62, severe HI=47, EP n=20, "complex/multiple disabilities" n=31, VI n=7, ED n=15 and other health disorders n=22 as shown in Figure 2. The type of disability among the 629 children with special needs in one rural setting was not recorded. A descriptive summary of the articles is presented in Table 2.

Oral health status of CWSHCN

Poor oral health among CWSHCN was observed in all studies presenting as caries and/or gingivitis. The prevalence of caries among CWSHCN ranged from 22.5% to 85.2%.^{27, 28} The mean dmft/DMFT scores ranged from 0.95 (SD 2.36) to 5.51 (SD 2.1)^{25, 27} and 0.67 to 10.24 (SD 2.97)^{25, 29} for the primary and permanent dentition, respectively. The studies reported high UTNs and mostly constituted untreated caries among the study participants of between 68%³⁰ and 100%,²⁶ attributed to low restorative care.

One study found that over half of the parents (56.7%) of CWSHCN rated their child's oral health status as average,²⁶ despite the high UTNs among the study sample. Furthermore, most caregivers (61%) of CWSHCN did not perceive the oral problems in their child as having an impact on overall health.

Two studies included a gingival health assessment and reported between 46% and 69% presence of gingival inflammation among children with ASD and ID, respectively.^{28,30} One study reported plaque index as visible plaque in 43.6% of children with ASD.²⁸

Other notable oral findings included mild loss of enamel (47%) and soft tissue trauma (lip biting) (25%) among children with ASD.²⁸ Orthodontic need for the correction of malocclusion were reported in 29% of children with ID.³⁰ However, the study did not elaborate on the types of occlusal disharmony in the study sample.

DISCUSSION

The characteristics and status of oral health among CWSHCN in SA between 2002 and 2023 were reviewed. Only six studies among CWSHCN were relevant, highlighting the paucity of data in SA. However, our review shows that the status of oral health for approximately 2,402 CWSHCN, aged between 0 and 20 years, were evaluated in the past two decades. Of the total sample in the six studies reviewed, 59.7% were male and 40.3% were female. According to the 2011 census, the prevalence of disability in SA was 7.5%³¹ and more than 600,000 children aged between 5-14 years had a disability. Notably, due to the lack of current epidemiological data, the number of children with disabilities in SA is largely unknown. The NCOHS conducted between 1999-2002²³ reported that 39.7% of the 6-year-old age group were caries-free; however, this survey did not include CWSHCN. Furthermore, the figure was below the 50% goal set by the SA Department of Health (DoH) for the year 2000.³²

Our study findings showed that the types of disabilities included, inter alia, intellectual disabilities (ID), Down Syndrome (DS), autism spectrum disorder (ASD), cerebral palsy (CP), epilepsy (EP), learning disabilities (LD), hearing impaired (HI), physical disabilities (PD), visual impairment (VI), emotional disorders (ED) and "complex/multiple disabilities". This list, however, did not include all CWSHCN defined as "...living with or at risk of chronic physical, developmental

Table II: Descriptive summary of the studies reviewed

Author	Year	Objective	Design	Sample (n)	Type of SHCN/ disability	Study setting	Results
Yengopal <i>et al</i>	2012	To determine the caries prevalence and UTN of children with special needs and compare with data from NCOHS	Cross-sectional analytic study	882 children (3-18 years) (65% male) mean age 10.5 years	Cerebral palsy (CP) (18.5%) hearing impaired (HI) (11.2%), learning disabilities (LD) (19.4%) and mental disability (MD) (51%)	Five special needs schools in Johannesburg (urban)	<ul style="list-style-type: none"> Prevalence of caries: primary dentition – 27.55%, permanent dentition – 33.56% More than 80% UTNs dmft score 1.35 (LD) – 3.4 (CP) DMFT score 0.67 (HI) – 1.27 (MD)
Nemutandani <i>et al</i>	2013	To determine the prevalence of dental caries among disabled individuals attending special schools in Vhembe districts.	Cross-sectional descriptive study	629 individuals with special needs (46% males) 0-6, 7-10, 11-18 and 19+ years	Disability not specified	Four special schools in Vhembe district, Limpopo (rural)	<ul style="list-style-type: none"> Prevalence of caries – more than 80% in all age groups. dmft score under 6 years – 5.51 (SD 2.1) DMFTs of the 11-18 years – 7.38 (SD 3.22) and above 19 years –10.24 (SD 2.97). High UTNs, < 1% restorative care
Roberts <i>et al</i>	2016	To assess the dental needs of a group of children with intellectual disability (ID) attending six special educational facilities in Cape Town, SA	Cross-sectional study	157 children with ID (67% males) mean age 10.1 years	Intellectual disability (ID)	Six special educational facilities in Cape Town (urban)	<ul style="list-style-type: none"> Prevalence of dental needs: Gingival disease (69%) Untreated dental caries (68%) Malocclusion requiring orthodontic correction (29%)
Naidoo and Singh	2018	To investigate the oral health status of children with ASD aged between 7-14 years in KwaZulu-Natal, SA	Investigative cross-sectional quantitative study	149 children with ASD (71.1% males), 7-8, 9-10, 10-11 and 12-14 years	Autism spectrum disorder (ASD)	Special needs schools in KwaZulu-Natal (78% peri-urban)	<ul style="list-style-type: none"> Overall caries prevalence – 85.2%. DMFT score – 3.42 Molars – 50% of score UTNs – 68.5% Soft tissue trauma with lip biting –25%. Mild gingival inflammation – 46.3%
Nqobco <i>et al</i>	2019	To assess how caregivers of CWSHCNs perceived the contribution of OHRQoL to the quality of life of these children	Survey of caregiver OHRQoL and child's oral health status	Convenient sample of 150 caregivers (mean age 39.5) and child pairs (mean age 8.7 years) (59.3% males)	Down syndrome (DS) (41%), CP (28%), ASD (10%), epilepsy (EP) (10%), complex disabilities (10%) and unknown (1%)	Down Syndrome Association (DSA) outreach sites in Johannesburg (urban)	<ul style="list-style-type: none"> Overall caries prevalence – 42% 56.7% of caregivers rated child's oral health as average Untreated caries (93-100%) regardless of disability type
Gumede <i>et al</i>	2023	To determine the prevalence of dental caries among learners with disabilities attending special schools education in the eThekweni district	Cross-sectional descriptive study design	435 children with disabilities (62.3% male) mean age 13 years	ID (41.8%), physical disability (PD) (15%), ASD (12.4%), severe HI (10.8%), HI (2.5%), multiple disabilities (3.7%), LD 2.5%, visual impairments (VI) 1.6%, emotional disturbances (ED) 3.4%, other health impairments 6.2%	22 special schools in eThekweni (60% peri-urban and 27.1% urban)	<ul style="list-style-type: none"> Prevalence of caries: Primary dentition – 22.5%, permanent dentition – 53.6%, DMFT –1.97 (SD 2.36) D-88%, F-4%, M-9% dmft-0.95 (SD 2.36) Decay component – 99% Highest caries prevalence in ID –46.4% dmft/DMFT increase with age (p=0.01)

CWSHCN: children with special health care needs OHRQoL: oral health related quality of life UTN: unmet treatment needs dmft/DMFT: decayed, missing, filled teeth for deciduous and permanent teeth respectively

and behavioural conditions...".⁵ Our study did, however, reflect the categories of disabilities provided in the 2011 SA census where the International Classification of Functioning Disability and Health³³ was used to categorise disability according to six functional domains: sight, hearing, communication, remembering/concentrating, walking and self-care. Using census data may have some limitations, for example parents are used as proxies to report on children with disabilities,³⁴ leading to possible underreporting. In addition, the use of functional domains may have resulted in the exclusion of children living with milder disabilities or chronic medical conditions who also form part of the diverse group of CWSHCN.

Our review found that caries prevalence among CWSHCN ranged between 22.5% and 85.2%. In addition, the caries severity reported by the dmft/DMFT scores varied across the disability groups and age categories. Caries severity appeared to increase with the age of the child in keeping with the impact of increased exposure to fermentable carbohydrates on dental caries development over time, and inadequate oral hygiene. Maintenance of oral hygiene is challenging for CWSHCN. For example, children with ASD display behavioural problems during routine tooth brushing while children with severe ID may lack the cognitive and manual dexterity to perform tooth brushing and rely on the parent/caregiver for assistance. Caregivers may be overburdened by the demands of caring for such children especially with poor support which is common in low resource settings.³⁵ Although the severity of the disabilities was not recorded in the studies reviewed, it is likely that SA children with more severe cognitive or behavioural problems may have had higher dmft/DMFT scores in keeping with the results of a study in India where children with severe ID had higher DMFT scores.³⁶ Identifying CWSHCNs who are at greater risk of dental caries and instituting early preventative measures may prevent the cumulative burden of dental caries over time.

Dental caries in children largely remains untreated. In 2010, untreated caries in the deciduous dentition was the 10th most prevalent condition affecting 9% of the global population.³⁷ Furthermore, the condition is even more prevalent in many low- and middle-income countries (LMICs).¹⁷ In SA, more than 80% of caries in children in the last NCOHS was not treated.²³ More than two decades later, our review has shown significant UTNs among CWSHCN as reflected by the high "decay" component of the dmft/DMFT scores. Similarly, high UTNs have been reported among CWSHCN in other LMICs such as Brazil, India, Nigeria and Rwanda.³⁸⁻⁴¹ Some of the reasons for high UTNs were low utilisation of oral healthcare services,⁴⁰ transportation difficulties,⁴² financial constraints of parents, reluctant dental providers and behavioural challenges of CWSHCN in the dental setting.⁴³ In a systematic review of the determinants of dental caries among children residing in North Africa and the Middle East, the interplay of child characteristics, family background, diet and oral hygiene habits influenced oral health in children.⁴⁴ Thus, barriers related to the child's special need/disability, family socioeconomic status and the environment may hinder access to preventative and restorative treatment for CWSHCN, especially in LMICs. These barriers suggest that a multifaceted approach is required to address the oral health inequalities and improve access to dental care. All stakeholders involved in children's health need

to prioritise oral health for CWSHCN, especially for those from disadvantaged backgrounds. Policy guidelines need to address contextual issues related to poor oral health for this population group in both developing and developed countries. To this end, the South African government has shown a commitment to provide universal health coverage through the National Health Insurance (NHI) Bill, and improve access to quality healthcare to previously disadvantaged groups.⁴⁵

Two studies in SA reported poor oral hygiene among children with ID and ASD.^{28,30} Similar findings were reported in Nigeria among 5- to 19-year-old children where significantly poorer oral hygiene was found in children with special needs compared to healthy children.⁴⁰ Globally, poor oral hygiene has been reported among children with ID,² resulting in gingivitis.⁴⁶ Gingivitis can resolve with improved oral hygiene; however, when left untreated it may progress to periodontitis, a chronic inflammatory disease of the dental supporting structures. Periodontitis, in turn, increases the risk for the development of noncommunicable diseases such as diabetes and cardiovascular diseases.⁴⁷ Thus, it is vitally important to maintain good oral health in CWSHCN for both oral and general health.

In this review, other reported oral health problems among CWSHCN in SA included malocclusion (29%)³⁰ and soft tissue trauma (25%)²⁸. A 1994 SA study found that 74.5% of the 381 children with disabilities needed orthodontic treatment.⁴⁸ Similarly, a high prevalence of malocclusion was found among children and adolescents with mental disabilities in India.⁴⁹ Occlusal disharmony may be more prevalent among certain groups of CWSHCN such as spastic CP, in whom an imbalance of the orofacial muscles may result in constriction of the dental arches, a posterior cross bite and an anterior open bite.¹¹ Furthermore, patients with malocclusion characterised by protrusion of maxillary permanent incisors are more prone to traumatic dental and soft tissue injuries.⁵⁰ Among the risk factors associated with malocclusion in children with CP include mouth breathing and lip incompetence.⁵¹ Thus, there is a need to incorporate orthodontic treatment in children with milder forms of disabilities to improve their quality of life.

The oral health status of CWSHCN may affect their overall quality of life.⁵² Untreated dental caries may affect the ability to eat, drink and sleep without discomfort or pain.⁵³ Developmental delay may affect speech and cognition making it difficult for the children to express discomfort or the feeling of pain.⁵⁴ However, despite evidence pointing to the negative impact of poor oral health such as severe dental caries on the quality of life among CWSHCN,⁵⁵ one study in SA reported contradictory findings where 61% of caregivers of CWSHCN did not consider the oral condition in their child to impact overall health.²⁶ The chronic medical condition of the child or disability may be more of a priority due to its impact on morbidity. Dental caries in the absence of pain, discomfort or sleep disruption may not be perceived as negatively affecting the child and needing attention. Caregivers' perceptions may be related to their socioeconomic status (SES) as children from families with high SES and parental education had better oral health-related quality of life.⁵⁶ Hence, contextual factors, especially in resource constrained settings, may influence the extent to which untreated dental caries among CWSHCN is perceived to impact overall quality of life.

Access to healthcare is a key global goal on the development agenda. The United Nations Millennium Development Goals (MDGs) in 2000 and later the Sustainable Development Goals (SDGs) and, more specifically, SDG3, committed to “ensure healthy lives and promote wellbeing for all at all ages”.⁵⁷ Among the goals of the National Oral Health Policy in SA is the promotion of oral health and increased access to services. However, the policy is outdated and in need of review based on current epidemiological data.⁵⁸ The inclusion of CWSHCN, who may be more at risk for dental diseases, would be important to provide specific strategies for the prevention and treatment of oral diseases and increase access to services in line with the NHI Bill. In addition, an integrated maternal and child oral health policy aimed at increasing access to oral health services for mothers and children could reduce the oral disease burden among children and those with special needs.⁵⁹ SA has been successful in creating an enabling environment for policy development work in the field of disability.⁶⁰ However, policy implementation has faced challenges of capacity constraints, low resource allocation and lack of government commitment. In a review of the National Oral Health Policy in SA, Mukhari-Baloyi et al⁵⁸ noted that the policy goals were clear but strategies for implementation were not well understood. Hence, more needs to be done to translate policies on people with disabilities to accessible and comprehensive healthcare that includes oral health, in developing countries such as SA, to promote equity and reduce inequalities.

Despite significant socioeconomic reforms in SA in the past two decades,⁶¹ inequalities in health, including oral health, for people with disabilities persist.⁶¹ Factors related to poverty such as unemployment, low literacy and inadequate access to healthcare have a greater negative impact on South African individuals living with disabilities.⁶² In SA, children with disabilities, particularly from low-resource settings, may face challenges accessing basic services such as health and education. For example, in a group of 156 children with disabilities from a small town near Soweto in SA, few were able to access basic education, assistive devices and social grants.⁶³ The situation appears not to have improved significantly in post-apartheid SA. In one qualitative study, caregivers of children with ID from a small town in SA reported financial difficulties, poor care networks and community stigma as barriers to utilisation of specialised hospital services.⁶⁴ Apart from individual caregiver and community barriers, system level barriers have been cited. For instance, a scoping review found that among children with disabilities living in LMICs in sub-Saharan Africa, poor policy implementation, lack of physical access and inadequately trained health professionals were barriers to healthcare access.⁶⁵ These factors may affect the quality of life of not only the children with disabilities but also their families. Therefore, addressing the wider social and economic disparities affecting health and healthcare access may lead to better oral and general health for children with disabilities in SA.

STRENGTHS AND LIMITATIONS OF THE STUDY

Our review focused on the status of oral health among CWSHCN in SA over the past two decades. Among the limitations were, first, the availability of only a few studies. The exclusion of unpublished studies may have resulted in publication bias. Second, the exclusion of studies that did

not report dental caries as an outcome may have led to selective outcome reporting bias. Among the strengths of the review was the use of a standard literature review method and DET, thereby decreasing the risk of bias. In addition, the review included participants with various special healthcare needs and not individual categories of disabilities, thereby increasing the sample. Finally, the studies were conducted in different geographical and socioeconomic settings in SA, possibly providing different contextual factors related to the oral health of CWSHCN and enhancing generalisability of the results within SA.

Despite the limitations, the review offers useful insights into the lack of data related to the status of oral health among CWSHCN in SA. In addition, the review has consolidated data on the characteristics and status of oral health among CWSHCN in SA over the past two decades. The data are important in understanding the oral health needs of this vulnerable group and to plan strategies to improve oral health, oral health outcomes and reduce inequalities in line with the SDGs call to “leave no one behind”.⁵⁷

CONCLUSION

Poor oral health and high UTNs were prevalent among CWSHCN in SA, with little evidence of preventative and restorative care. There was insufficient published data on the status of oral health among CWSHCN in SA.

RECOMMENDATIONS

There is a need for a nationwide survey to determine the oral health status of CWSHCN in SA, to enable proper planning of preventative and comprehensive oral healthcare. Future research should focus on identifying the barriers to accessing early preventative and restorative care. Increasing awareness of the importance of good oral health for CWSHCN among all stakeholders involved with children could facilitate early referrals for preventative and restorative care.

REFERENCES

1. Ningrum V, Bakar A, Shieh T, Shih Y. The Oral Health Inequities between Special Needs Children and Normal Children in Asia: A Systematic Review and Meta-Analysis. *Healthcare (Basel)*. 2021;9(4).
2. Zhou N, Wong H, Wen Y, McGrath C. Oral health status of children and adolescents with intellectual disabilities: a systematic review and meta-analysis. *Dev Med Child Neurol*. 2017;59(10):1019-26.
3. Hennequin M, Moysan V, Jourdan D, Dorin M, Nicolas E. Inequalities in oral health for children with disabilities: a French national survey in special schools. *PLoS One*. 2008;3(6):e2564.
4. Wilson N, Lin Z, Villarosa A, George A. Oral health status and reported oral health problems in people with intellectual disability: A literature review. *J Intellect Dev Dis*. 2019;44(3):292-304.
5. McPherson M, Arango P, Fox H, Lauver C, McManus M, Newacheck P, et al. A new definition of children with special health care needs. *Pediatrics*. 1998;102(1):137-9.
6. Epping-Jordan J, Pruitt S, Bengoa R, Wagner E. Improving the quality of health care for chronic conditions. *BMJ Qual Saf*. 2004;13(4):299-305.
7. WHO. World Report on Disability Geneva: WHO; 2011 [cited 2021 23/03]. Available from: https://www.who.int/disabilities/world_report/2011/report.pdf.
8. Statistics SA. Census 2011 Pretoria: Statistics SA; 2011 [cited 2020 24/11]. Available from: [Available from: www.statsa.gov.za].
9. Lam PP, Du R, Peng S, McGrath CP, Yiu CK. Oral health status of children and adolescents with autism spectrum disorder: A systematic review of case-control studies and meta-analysis. *Autism*. 2020;24(5):1047-66.
10. Kotha S, AlFaraj NSM, Ramdan TH, Alsalam MA, Al Meeer MJ, Almuzin Z. Associations between diet, dietary and oral hygiene habits with caries occurrence and severity in children with autism at Dammam City, Saudi Arabia. *Open Access Maced J Med Sci*. 2018;6(6):1104.
11. Dharmani CKK. Management of children with special health care needs (SHCN) in the dental office. *J Med Soc* 2018;32(1):1.
12. Lin X, Wu W, Zhang C, Lo EC, Chu CH, Dissanayaka WL. Prevalence and distribution of developmental enamel defects in children with cerebral palsy in Beijing, China. *Int J Paediatr Dent*. 2011;21(1):23-8.
13. Fisher K. Is there anything to smile about? A review of oral care for individuals with intellectual and developmental disabilities. *Nurs Res and Pract*. 2012;2012.
14. Sheiham A. Dental caries affects body weight, growth and quality of life in pre-school children. *Br Dent J*. 2006;201(10):625-6.
15. Foster H, Fitzgerald J. Dental disease in children with chronic illness. *Arch Dis Child*. 2005;90(7):703-8.
16. Rashewsky S, Parameswaran A, Sloane C, Ferguson F, Epstein R. Time and cost

- analysis: pediatric dental rehabilitation with general anesthesia in the office and the hospital settings. *Anesth Prog.* 2012;59(4):147-53.
17. Peres M, Macpherson L, Weyant R, Daly B, Venturelli R, Mathur M, et al. Oral diseases: a global public health challenge. *The Lancet.* 2019;394(10194):249-60.
 18. Bastani P, Mohammadpour M, Ghanbarzadegan A, Rossi-Fedele G, Peres M. Provision of dental services for vulnerable groups: a scoping review on children with special health care needs. *BMC Health Serv Res.* 2021;21(1):1-12.
 19. Charlotte WL. Dental Care and Children with Special Health Care Needs: A Population-Based Perspective. *Acad Pediatr.* 2009;9(6):420-6.
 20. Ataguba J, Akazili J, McIntyre D. Socioeconomic-related health inequality in South Africa: evidence from General Household Surveys. *Int J Equity Health.* 2011;10:1-10.
 21. Ataguba JE-O, Day C, McIntyre D. Explaining the role of the social determinants of health on health inequality in South Africa. *Global Health Action.* 2015;8(1):28865.
 22. Page M, McKenzie J, Bossuyt P, Boutron I, Hoffmann T, Mulrow C, et al. The PRISMA 2020 statement: an updated guideline for reporting systematic reviews. *International journal of surgery.* 2021;88:105906.
 23. Van Wyk P, Louw A, Du Plessis J. Caries status and treatment needs in South Africa: report of the 1999-2002 National Children's Oral Health Survey. *SADJ.* 2004;59(6):240-2.
 24. Bethel AC, Rogers M, Abbott R. Use of a search summary table to improve systematic review search methods, results, and efficiency. *Journal of the Medical Library Association: JMLA.* 2021;109(1):97.
 25. Nemutandani M, Adedjoja D, Nevuhluwi D. Dental caries among disabled individuals attending special schools in Vhembe district, South Africa. *SADJ.* 2013;68(10):458-61.
 26. Nqobco C, Kolisa YM, Ralephenya T, Esan T, Yengopal V. Caregivers' perceptions of the oral-health-related quality of life of children with special needs in Johannesburg, South Africa. *Health SA* 2019;24(1):1-7.
 27. Gumed S, Singh S, Radebe M. Prevalence of dental caries among learners with disabilities attending special education schools in the eThekweni District, KwaZulu-Natal. *SADJ.* 2023;Vol. 78:292-8.
 28. Naidoo M, Singh S. The Oral health status of children with autism Spectrum disorder in KwaZulu-Natal, South Africa. *BMC Oral Health.* 2018;18(1):165.
 29. Yengopal V, Nqobco C, Thekiso M, Rudolph M, Joosab Z. Dental caries prevalence in children attending special needs schools in Johannesburg, Gauteng Province, South Africa. *SADJ.* 2012;67(7):308-13.
 30. Roberts T, Chetty M, Kimmie-Dhansay F, Stephen L, Fieggen K. Dental needs of intellectually disabled children attending six special educational facilities in Cape Town: The new millennium. *S Afr Med J.* 2016;106(sup-1):94-7.
 31. SA S. Stats SA profiles persons with disabilities Statistics South Africa RSA; [cited 2023 17/07]. Available from: <http://www.statssa.gov.za/?p=3180>.
 32. van Wyk P, van Wyk C. Oral health in South Africa. *Int Dent J.* 2004;54(S6):373-7.
 33. WHO. International Classification of Functioning, Disability and Health (ICF): WHO; [cited 2023 01/09]. Available from: <https://www.who.int/standards/classifications/international-classification-of-functioning-disability-and-health>.
 34. Loeb M, Mont D, Cappa C, De Palma E, Madans J, Cialesi R. The development and testing of a module on child functioning for identifying children with disabilities on surveys. I: Background. *Disabil Health J.* 2018;11(4):495-501.
 35. Mkabile S, Garrun K, Shelton M, Swartz L. African families' and caregivers' experiences of raising a child with intellectual disability: A narrative synthesis of qualitative studies. *Afr J Disabil* 2021;10:1-10.
 36. Makkar A, Indushekar K, Saraf B, Sardana D, Sheoran N. A cross sectional study to evaluate the oral health status of children with intellectual disabilities in the National Capital Region of India (Delhi-NCR). *J Intellect Disabil Res.* 2019;63(1):31-9.
 37. Kassebaum N, Bernabé E, Dahiya M, Bhandari B, Murray C, Marcenes W. Global burden of untreated caries: a systematic review and metaregression. *J Dent Res.* 2015;94(5):650-8.
 38. Cardoso A, Gomes LN, Silva CD, de SC Soares R, De Abreu MHN, Padilha WW, et al. Dental caries and periodontal disease in Brazilian children and adolescents with cerebral palsy. *Int J Environ Res Public Health.* 2015;12(1):335-53.
 39. Mehta A, Gupta R, Mansoor S, Mansoor S. Assessment of oral health status of children with special needs in Delhi, India. *RSBO Revista Sul-Brasileira de Odontologia.* 2015;12(3):239-46.
 40. Oredugba FA. Use of oral health care services and oral findings in children with special needs in Lagos, Nigeria. *Spec Care Dentist.* 2006;26(2):59-65.
 41. Uwayezu D, Gatarayih A, Nzayirambaho M. Prevalence of dental caries and associated risk factors in children living with disabilities in Rwanda: a cross-sectional study. *Pan Afr Med J.* 2020;36(1).
 42. Silva E, Góes P, Vasconcelos M, Jamelli S, Eickmann S, Melo M, et al. Oral health care for children and adolescents with cerebral palsy: perceptions of parents and caregivers. *Cien Saude Colet.* 2020;25:3773-84.
 43. Krishnan L, Iyer K, Kumar P. Barriers in dental care delivery for children with special needs in Chennai, India: A mixed method research. *Disability, CBR & Inclusive Development.* 2019;29:68-82.
 44. Elamin A, Garemo M, Mulder A. Determinants of dental caries in children in the Middle East and North Africa region: a systematic review based on literature published from 2000 to 2019. *BMC Oral Health.* 2021;21(1):1-30.
 45. Department of Health. National Health Insurance in SA. Policy Paper Pretoria: DoH; [cited 2020 26/11]. Available from: <https://www.gov.za/sites/default/files/nationalhealthinsurance.pdf>.
 46. de Castilho LS, Abre MHNG, de Souza DH, e Silva MES, Resende VLS. Factors associated with gingivitis in children with developmental disabilities. *Pesqui Bras Odontopediatria Clin Integr.* 2016;16(1).
 47. Dörfer C, Benz C, Aida J, Campard G. The relationship of oral health with general health and NCDs: a brief review. *Int Dent J.* 2017;67:14-8.
 48. Ackerman A, Wiltshire W. The occlusal status of disabled children. *The Journal of the Dental Association of South Africa= Die Tydskrif van die Tandheelkundige Vereniging van Suid-afrika.* 1994;49(9):447-51.
 49. Vellappally S, Gardens S, Al Kheraif A, Krishna M, Babu S, Hashem M, et al. The prevalence of malocclusion and its association with dental caries among 12-18-year-old disabled adolescents. *BMC Oral Health.* 2014;14(1):1-7.
 50. Glendor U. Aetiology and risk factors related to traumatic dental injuries—a review of the literature. *Dent Traumatol.* 2009;25(1):19-31.
 51. Miamoto CB, Ramos-Jorge ML, Pereira LJ, Paiva SM, Pordeus IA, Marques LS. Severity of malocclusion in patients with cerebral palsy: determinant factors. *Am J Orthod Dentofac.* 2010;138(4):394. e1 - e5.
 52. Barbosa T, Gavião M. Oral health-related quality of life in children: part II. Effects of clinical oral health status. A systematic review. *Int J Dent Hyg.* 2008;6(2):100-7.
 53. Mathur VP, Dhilon JK. Dental caries: a disease which needs attention. *Indian J Pediatr.* 2018;85:202-6.
 54. Lotan M, Icht M. Diagnosing Pain in Individuals with Intellectual and Developmental Disabilities: Current State and Novel Technological Solutions. *Diagnostics (Basel).* 2023;13(3):401.
 55. Faker K, Tostes M, Paula V. Impact of untreated dental caries on oral health-related quality of life of children with special health care needs. *Braz Oral Res.* 2019;32.
 56. Kumar S, Kroon J, Laloo R. A systematic review of the impact of parental socioeconomic status and home environment characteristics on children's oral health related quality of life. *Health Qual Life Outcomes.* 2014;12(1):41.
 57. Organization WH. Health in 2015: from MDGs, millennium development goals to SDGs, sustainable development goals. 2015. Report No.: 924156511X.
 58. Mukhari-Baloyi N, Bhayat A, Madiba T, Nkambule N. A review of the South African national oral health policy. *SADJ.* 2021;76(9):551-7.
 59. Ramphoma K, Rampersad N, Singh N, Mukhari-Baloyi N, Naidoo S. The proposed need for integrated maternal and child oral health policy: A case of South Africa. *Front Oral Health.* 2022;3:1023268.
 60. Dube A. The role and effectiveness of disability legislation in South Africa. 2005.
 61. Omotoso K, Koch S. Assessing changes in social determinants of health inequalities in South Africa: A decomposition analysis. *Int J Equity Health.* 2018;17(1):1-13.
 62. Emmett T. Disability, poverty, gender and race. *Disability and social change: A South African agenda.* 2006;17(4):207-33.
 63. Saloojee G, Phohole M, Saloojee H, IJsselmuiden C. Unmet health, welfare and educational needs of disabled children in an impoverished South African peri-urban township. *Child Care Health Dev.* 2007;33(3):230-5.
 64. Mkabile S, Swartz L. 'I waited for it until forever': Community barriers to accessing intellectual disability services for children and their families in Cape Town, South Africa. *Int J Environ Res Public Health.* 2020;17(22):8504.
 65. Aduagna M, Nabbouh F, Shehata S, Ghahari S. Barriers and facilitators to healthcare access for children with disabilities in low and middle income sub-Saharan African countries: a scoping review. *BMC Health Serv Res.* 2020;20:1-11.

CPD questionnaire on page 120

The Continuing Professional Development (CPD) section provides for twenty general questions and five ethics questions. The section provides members with a valuable source of CPD points whilst also achieving the objective of CPD, to assure continuing education. The importance of continuing professional development should not be underestimated, it is a career-long obligation for practicing professionals.



What's new for the clinician – summaries of recently published papers (March 2024)

SADJ March 2024, Vol. 79 No.2 p109-112

Edited and compiled by Prof V Yengopal, Faculty of Dentistry, University of the Western Cape

1. INVESTIGATING THE POTENTIAL CLINICAL IMPACT OF PERIODONTITIS ON THE PROGRESSION OF ALZHEIMER'S DISEASE: A PROSPECTIVE COHORT STUDY

Alzheimer's disease (AD), which is characterised by insidious onset and progressive deterioration in behavioural and cognitive functions, is a neurodegenerative disease that commonly affects the central nervous system (CNS).¹ The prevalence of AD increases with advancing age and, after the age of 65, the risk of AD doubles every five years. It is more common in women than men.¹ It is thought that chronic inflammatory diseases and conditions in peripheral organs such as cardiovascular disease, diabetes and periodontitis can affect the inflammatory state in the CNS and exacerbate the molecular pathology of AD.¹

The current literature shows that periodontal disease can affect AD via multiple ways. It is thought that understanding the causal relationship between periodontal disease and AD may be effective in preventing the incurable AD or in reducing cognitive decline¹. Karaduran and colleagues (2023)¹ reported on a study that sought to investigate the relationship between the current periodontal and occlusal relationship status and the rate of AD progression in individuals with AD. Their hypothesis was that periodontitis may accelerate the rate of AD progression.

METHODOLOGY

This study was designed according to the STROBE (STrengthening the Reporting of OBservational studies in Epidemiology) statement.

Systemic anamnesis of the participants were taken at their initial appointment in a neurology department. Their diagnosis and medical records were reviewed, and dental anamnesis was obtained to ensure all participants met the inclusion criteria. Ninety participants who met the National Institute of Neurological and Communicative Disorders and Stroke-Alzheimer's Disease and Related Disorders Association (NINCDS-ADRDA) and DSM-V diagnostic criteria for probable Alzheimer's disease were divided into 3 groups as Stage I (mild), Stage II (moderate) and Stage III (severe) according to the Clinical Dementia Rating Scale.

Those who have been diagnosed with probable AD in the age range of 50-89 years, not having dementia other than Alzheimer's-type dementia, not having psychiatric disorders affecting cognitive status, not using regular anti-inflammatory, corticosteroids and drugs that affect cognitive status, and non-smokers were included in the study. Patients who received any dental treatment in the

past year, had systemic disease not under control other than AD (diabetes and cardiovascular disease) and had less than 10 with the edentulousness was not prosthetically rehabilitated were excluded from the study.

All participants were found eligible for cognitive status assessment, and cognitive status was assessed using Standardised Mini-Mental Test (SMMT) scores. With SMMT, it is possible to understand the process of AD in the individual. In this test, which lasts for 10 minutes in total, 30 questions are asked to evaluate the individual's time, recording memory, attention and calculation, recall and language. The score obtained by the individual with SMMT varies between 0 and 30. The SMMT score was determined at the participants' first appointments in the neurology department and at the six-month follow-up appointments. The change in the SMMT score (Δ SMMT) between the follow-up periods was calculated.

Participants were referred to the periodontology department at the six-month follow-up appointment in the neurology department. Dental anamnesis of the patients was taken and intraoral examinations were performed in the periodontology department. Periodontal examination of all existing teeth of all participants with at least one remaining tooth (excluding third molars) with a Williams-marked periodontal probe and all molars and maxillary first premolars with Nabers probe was performed. Percentage of dental plaque (P%) and percentage of bleeding on probing (BOP%), clinical attachment level (CAL) and probing pocket depth (PPD) were recorded. PPD and CAL were measured at six sites/teeth (excluding third molars). The current occlusal relationship status of all patients was evaluated using the Eichner Index and classified as Type 1 (A1-A2-A3-B1), Type 2 (B2-B3) and Type 3 (B4-C1-C2-C3). Also, the current C-Reactive Protein (CRP) value of Alzheimer's patients, measured within the six months before the date of participation, was retrospectively determined and recorded.

RESULTS

When comparing the ages of Alzheimer's patients according to the stages, there was no significant difference between Stage I and Stage II groups, although Stage III patients had a significantly higher mean age than Stage I and Stage II patients ($p < 0.05$). There was no significant difference between the groups in terms of gender and the presence or absence of systemic disease that is under control ($p > 0.05$).

The initial (T0), the sixth month (T1) and the Δ SMMT scores were analysed based on the current toothed/edentulousness status of the patients. Δ SMMT was significantly higher in Stage III than in Stage I ($p = 0.000$) and

Stage II ($p=0.001$) Alzheimer groups. Furthermore, it was determined that the SMMT0 and SMMT1 scores of the Stage III edentulous Alzheimer's patients were significantly lower than those of the Stage I Alzheimer's patients ($p<0.05$), and there was no difference between the Stage I and Stage II Alzheimer's patients ($p>0.05$). In addition, it was determined that there was no significant difference between the groups in the Δ SMMT ($p>0.05$).

Ninety Alzheimer's patients consisted of 25 edentulous individuals without periodontal disease and 65 toothed individuals diagnosed with periodontitis. Accordingly, initial SMMT, six-month SMMT and Δ SMMT of the study population were also analysed according to the presence of current periodontal disease. When the initial and six-month SMMT score values were evaluated according to the presence of periodontal disease, T0 and T1 SMMT scores did not differ between the groups ($p>0.05$); however, Δ SMMT scores in patients having periodontitis were higher than those not having current periodontitis ($p<0.05$).

Although P% and number of teeth were not statistically different between groups ($p>0.05$), BOP% was significantly higher in the Stage III Alzheimer's group than in the other groups ($p<0.05$). In addition, CAL and PPD values were found to be significantly higher in Stage III than in Stage I Alzheimer's patients ($p<0.05$).

All participants included in the study were also evaluated based on their occlusal relationship and classified as Type 1, Type 2 and Type 3. The scores of initial (T0) and six-month (T1) SMMT and the change in evaluated time periods (Δ SMMT) were not statistically different between types which was determined according to the occlusal relationship ($p>0.05$). According to the occlusal relationship type, periodontal parameters were not statistically significant in patients with toothed Alzheimer's ($p>0.05$); on the other hand, as expected there was a significant difference in the number of teeth ($p<0.05$).

The serum CRP level was found to be significantly higher in the Stage III Alzheimer's group (4.46 ± 3.68) than in the Stage I Alzheimer's group (2.22 ± 2.53) ($p<0.05$). When the individuals were assessed according to their toothed/edentation status, serum CRP levels were found to be significantly higher in toothed Stage III Alzheimer's patients (5.36 ± 3.65) than in toothed Stage I Alzheimer's patients (1.78 ± 1.84) ($p<0.05$). Serum CRP levels did not differ between the Alzheimer's stages in edentulous patients.

Correlation analysis was performed between the clinical and biochemical parameters of the study population. Age was positively correlated with BOP% and CAL and negatively correlated with SMMT0, SMMT1 and number of teeth ($p<0.05$). Furthermore, Δ SMMT scores were positively correlated with BOP% ($r=0.308$, $p=0.013$) and PPD ($r=0.275$, $p=0.027$) and the number of teeth ($r=0.291$, $p=0.005$) negatively correlated with SMMT0 and SMMT1 scores ($p<0.05$). Serum CRP levels were positively correlated with BOP% and negatively correlated with SMMT0 and SMMT1 scores ($p<0.05$).

Linear regression models showed that the individuals in the Stage II and Stage III Alzheimer's group, the age and presence of periodontitis variable had a statistically significant effect on Δ SMMT ($p<0.05$). Consequently,

being in the Stage II group increased Δ SMMT by 0.249 units and being in the Stage III group by 0.673 units. It was determined that an increase in age by 1 unit decreased Δ SMMT by -0.040 units in Alzheimer's patients. In addition, presence of periodontitis was found to increase Δ SMMT by 0.425 units. The effects of female gender, presence of systemic disease under control and CRP level on Δ SMMT were not statistically significant ($p>0.05$).

CONCLUSION

The researchers found that the presence of periodontitis may accelerate the progression of AD. The occlusal relationship has no significant clinical effect on AD progression when the partial/total edentulism was prosthetically rehabilitated.

IMPLICATIONS FOR PRACTICE

These results once again highlight the link between systemic disease and oral health and also show the importance of good oral hygiene in slowing the progression of AD.

REFERENCE

1. Karaduran K, Aydogdu A, Gelisin O, Gunpinar S. Investigating the potential clinical impact of periodontitis on the progression of Alzheimer's disease: a prospective cohort study. *Clinical Oral Investigations*. 2023 Dec 30;28(1):67

2. IS CONE-BEAM COMPUTED TOMOGRAPHY (CBCT) AN ALTERNATIVE TO PLAIN RADIOGRAPHY IN ASSESSMENTS OF DENTAL DISEASE IN MEDICALLY COMPROMISED PATIENTS?

Patients who are about to undergo treatment due to head and neck malignancies, generalised tumour spread, organ transplant or severe infection are generally more thoroughly examined both clinically and radiographically to diagnose oral disease.¹ In Sweden, for example, health programmes have been designed to make, for example, cancer treatment nationally standardised – ie equal and efficient. Therefore, these patients may be excluded from a more individualised approach as regards the extent of the radiographic examination, ie the principles of ALARA (As Low As Reasonably Achievable) or ALADAIP (As Low As Diagnostically Acceptable being Indication-oriented and Patient-specific).

Due to their medical condition, these patients are more vulnerable than a healthy population. They may suffer from generalised fatigue due to reduced lung capacity, medication and the stress of their situation. Some of the patients with intraoral tumours suffer from intraoral pain, and others may have difficulties opening their mouth. All these conditions may influence their capability to cooperate in an intraoral radiographic examination (IO), thus impairing the image quality and the possibility of performing a correct diagnosis.

A dental radiographic examination is a crucial component to the clinical examination to diagnose dental diseases, monitor illness over time and choose the most appropriate treatment available and its effect in a long-term perspective. Still, a radiographic examination using intraorally placed detectors is the recommended radiographic technique in diagnosing the most common dental diseases. It may, however, require at least 18-20 images to fully cover the

dentate areas and adjacent bone in an individual with a complete dentition (32 teeth). This procedure is time-consuming and not always pleasant for the patient. Sometimes a panoramic radiograph (PX) is needed to complement the IO, for example when the intraoral technique is not feasible due to anatomical variants, reduced capacity to open the mouth, or pain secondary to intraoral tumours. When correctly performed, PX provides valuable information.

Since its introduction in the late 1990s, cone-beam computed tomography (CBCT) has gradually changed the concept of dental radiographic imaging with its availability and excellent tomographic images of the dentomaxillofacial region at a relatively low radiation dose compared to medical computed tomography (CT). These new CBCT devices perform, besides CBCT acquisition, panoramic and cephalometric imaging. This expanded range of applications has made them more accessible in general dentistry and may be an alternative radiographic method for patients who cannot tolerate intraorally placed detectors.

Lindfors and colleagues (2024)¹ from Sweden reported on a study that sought to compare the diagnostic agreement (unit of measure of agreement used was a Kappa score) of three radiographic modalities – IO, PX and CBCT – for diagnosis of dental disease in medically compromised patients.

METHODS

Three hundred medically compromised patients who were referred for a dental radiographic examination were invited to participate in the study. To be included, the patient had to be dentated or rehabilitated with dental implants, be able to sit in a chair without the support of a high neck rest, comprehend the patient information either by themselves or through an interpreter, and accept to participate.

All patients were referred to the Department of Maxillofacial Radiology to undergo radiographic examination. All patients were examined with IO and PX radiographs, according to the local standard protocol for this patient population. All patients who fulfilled the criteria for inclusion were then thoroughly informed of the study: the purpose, the increased radiation dose, how data would be stored and results presented. An additional CBCT scan was performed on those patients who accepted participation by signed confirmation.

The intraoral radiographic examinations (IO) were performed applying a parallel technique using a Focus, Instrumentarium radiographic equipment together with Sirona Schick 33 sensors (Sirona Dental). Exposure parameters used were 60kV, 7mA and exposure time varying between 0.16 and 0.25 seconds depending on dental region and patient size. The PX were obtained with an Orthophos XG 5 (Sirona Dental Systems). Scan time was 14.1 seconds and exposure settings varied between 8-15mA and 62-73kV depending on patient size. The CBCT examinations were performed using Veraviewepocs® 3D R 100 with a field-of-view (FOV) of 100mm×80mm enclosing the complete dentition. The exposure settings were 85kV and 5mA and the scan time of 9.4 seconds was optimised for the diagnostic yield. The voxel size was 0.160mm. Quality assessment of radiographic examinations was continuously performed

by an oral radiologist according to clinical procedures for the different imaging modalities, ie image area, projection geometry as regards intraoral imaging and panoramic radiographs, as well as FOV, and eventual presence of motion artifacts in CBCT-examinations. Retakes were made when necessary.

The observers were four senior board-certified specialists in dentomaxillofacial radiology in Sweden. The patients were divided among the observers as follows: observer 1 was allotted the first 60 consecutive patients, observer 2 the next consecutive 60 patients, and so on. Observer 4 (principal investigator) evaluated the 120 remaining consecutive patients.

The radiographic images were digitised and the images were displayed on two 21.3-inch colour LCD monitors. The CBCT examinations were viewed using software i-Dixel-3DX and the observers were able to use the software program to align the image planes to obtain the best visualisation for each diagnostic task and tooth/root.

No clinical data was available for the observers. Initially and prior to the evaluation, the observers were calibrated. For each observer, the images on all the allotted patients were evaluated separately, ie first the intraoral radiographs on all patients, then the panoramic and, finally, the CBCT images on all patients. The assessment of the different imaging modalities was separated in time by at least 1 month.

To facilitate the recording of findings, a template was made using Microsoft Access Office 2010. Each observer had three different Access files – one for the basic number of patients (60 or 120 individuals) and two additional for calculating inter- and intra-observer agreement. Each Access file consisted of templates with all 32 teeth positions available with a corresponding square below for scoring. In every Access file, there were nine different templates, one for each modality and for the three different diagnostic tasks (periapical radiolucency, marginal bone level and caries lesions). For each patient, an overall assessment of the image quality for each radiographic method and all diagnoses was made. In total, 63,310 (63,198 teeth + 112 implants) scores were set in the main study and 432 to calculate inter- and intra-observer agreement.

The following variables were evaluated:

Periapical lesions: The unit was the tooth regardless of the number of roots. Impacted teeth were excluded and scored missing: 1, no disease (including widened periodontal ligament); 2, disease (periapical lesion irrespective of size and/or location); 3, not possible to evaluate due to artifact; 4, not possible to evaluate due to not depicted; 5, missing tooth.

Marginal bone level (Tooth): The unit was the tooth: 1, no disease (marginal bone level ≤ 5mm from the cemento-enamel junction (CEJ)); 2, disease (marginal bone level > 5mm from CEJ); 3-5 see periapical evaluation.

Marginal bone level (Dental implant): The unit was the implant: 6, no disease (marginal bone level ≤ 3mm apical to the reference point); 7, disease (marginal bone level > 3mm apical to the reference point); 8, not possible to evaluate due to artifact; 9, not possible to evaluate due to not depicted.

Caries lesions: The unit was the tooth: 1, no disease (no

caries lesion including the enamel); 2, disease (caries in the dentin and/or root surface and secondary caries); 3-5 see periapical evaluation.

For each patient and modality, regardless of diagnostic task, all observers evaluated the image quality according to a score: excellent (1), good (2), acceptable (3) and poor (4).

RESULTS

The highest agreement represented by the Kappa value was found diagnosing periapical radiolucency, comparing IO and CBCT (0.76). This sample group was also the largest with 6,856 assessments which means that 97.7% of all 7,020 teeth were assessable for diagnosis in this group. Diagnosing marginal bone level, the Kappa value varied between 0.58 and 0.60 comparing the different modalities. This group consisted of 6,534 assessable teeth (93.1%). When assessing marginal bone level at dental implants, the Kappa values when comparing CBCT and PX and IO and CBCT were low, 0.18 and 0.29, respectively, representing “none to slight agreement” and 0.43 comparing PX to IO representing “moderate agreement”. In diagnosing caries, only 44.4% of all teeth were assessable in CBCT when compared to IO (Kappa value 0.68). The Kappa value for PX and IO and CBCT and PX in diagnosing caries was 0.54 and 0.57, respectively.

The intra-observer agreement, for all modalities and diagnoses, was for one of the observers an “almost perfect agreement” (Kappa values between 0.87 and 0.93). For the other observers, the agreement was considered “moderate” or “substantial” (Kappa values between 0.5 and 0.73).

Overall inter-observer agreement for each modality and diagnosis showed a variety from “moderate” to “almost perfect agreement” (Kappa value between 0.51 and 0.87).

CONCLUSION

The researchers concluded that intraoral radiography was the first-hand choice for diagnosing dental disease. For some rare cases where intraoral imaging is not possible, a dedicated panoramic image and/or CBCT examination is an alternative.

IMPLICATIONS FOR PRACTICE

IO radiography is available at almost all practices and should be the primary source of radiographic investigation for the presence of dental disease.

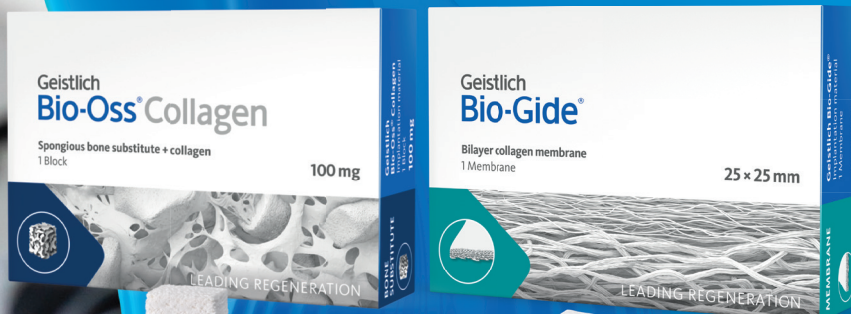REFERENCE

1. Lindfors N, Ekestubbe A, Frisk F, Lund H. Is cone-beam computed tomography (CBCT) an alternative to plain radiography in assessments of dental disease? A study of method agreement in a medically compromised patient population. *Clinical Oral Investigations*. 2024 Jan 30;28(2):12



Geistlich

Passion for regeneration



swiss made

New Distributor!

More Details about our products:
geistlich-dental.com

Geistlich is a specialist in the regeneration of bone, cartilage and tissue. With our products, we have set ourselves the goal of improving the quality of life of our patients.

Now available through Straumann Group South Africa. Tel: +27 21 850 0823

leading regeneration

Terminating dentist-patient relationships: balancing ethics and practical considerations

SADJ March 2024, Vol. 79 No.2 p113-116

Mr Punkaj Govan – South African Dental Association * This paper is not peer-reviewed

INTRODUCTION

In South Africa, the right to healthcare is not explicitly guaranteed in the Constitution. However, the Constitution does protect the right to life, which has been interpreted by the Constitutional Court to include a right to access healthcare services.

A dentist's duty to a patient is to provide complete and competent dental care. Practitioners often wonder whether they are required to accept everyone who presents themselves to their office for treatment as a patient. No, you're not!

Dentists are not "innkeepers" and need not open their doors to all who seek their services. Dentists also have the autonomy to decide which persons to accept as patients or to terminate an existing dentist-patient relationship subject to what is stated below.

Practitioners are, however, prohibited from discriminating against and refusing services to any person solely based on discriminatory grounds such as their race, religion, gender, sexual orientation, national origin, handicap, disability etc.

In emergencies the principles of beneficence and nonmaleficence apply, regardless of the patient's ability to pay – the dentist must stabilise the patient before referral, as the Constitution states that nobody may be refused emergency medical treatment. In non-emergency cases, the dentist is still required to do good for the patient, and avoid harm, for example by referral to the public sector or, if the doctor charges private fees and does not submit claims to patients' medical schemes, refer the patient to a colleague who would accept the patient's medical scheme coverage.

The National Health Act 2003 provides that health establishments must implement measures that minimise injury or damage to the person or property of healthcare workers. This means that practitioner employers are under a general duty to provide a safe and healthy workplace free from hazards and that their employees are protected from physical harm, their working environment made safe and free from any hazardous incidents.

In the case of a patient who is known to be or has a history of violent and abusive behaviour, the management and treatment of that patient may be characterised as a workplace hazard. An employer who fails to take steps to control the risk posed by such a patient may have breached their obligation to protect the health and safety of their employees.

In addition, it may not only be employees who may be at risk from violent or abusive behaviour, but other patients in the practice could also be injured by another patient, or even suffer an adverse health outcome as a result of witnessing the behaviour of another patient.

FINANCIAL STRAIN

Financial issues are a routine challenge in dental practices. The financial limitations of patients or reduced benefits provided by their schemes are often the main barriers to accessing the required treatment and negatively affect health outcomes.

Patients also often have unrealistic expectations that require the practitioner to know the extent of benefits, limitations or exclusions of the patients' medical scheme plan. Practitioners are also often required by their patients to obtain pre-authorisations for procedures from patients' medical schemes.

Some practitioners are uncomfortable about discussing financial issues with their patients for various reasons, such as the patient will consult with another practitioner if fees are considered unaffordable or the practitioner cannot estimate costs as external contractors or materials need to be sought.

Many of the treatment plans are rejected simply because the patient cannot afford to pay either at the time or even over the duration of treatment.

Some practitioners also believe if they began to accept requests for a fee reduction, it would gradually raise other patients' expectations, which may result in unfavourable consequences. Others are of the view that rejecting patients' requests to make a reduction would damage their reputation and would be harmful to the dental profession in the long term.

DISMISSING A PATIENT

Just like in any relationship, nearly all dentists will need to dismiss a patient at some point in their careers. Dismissals can be upsetting for patients and stressful for dentists.

Although the list is not exhaustive, the dismissal of a patient can be for many reasons, such as:

- **Treatment nonadherence:** The patient does not or will not follow the treatment plan or the follow-up instructions or discontinues medication or therapy regimens prior to completion.

- **Follow-up noncompliance:** The patient repeatedly cancels follow-up visits or fails to keep scheduled appointments with the practitioner or consultants.
- **Verbal abuse or violence:** The patient, a family member or a third-party caregiver is rude, uses disparaging or demeaning language, or sexually harasses office personnel or other patients, visitors or vendors; exhibits violent or irrational behaviour; makes threats of physical harm; or uses anger to jeopardise the safety and wellbeing of anyone present in the office.
- **Display of firearms or weapons:** The patient, a family member or a third-party caregiver wields a firearm or weapon on the premises.
- **Inappropriate or criminal conduct:** The patient exhibits inappropriate sexual behaviour toward providers or staff or participates in drug diversion, theft or other criminal conduct involving the practice.
- **Nonpayment:** The patient owes a backlog of bills and has declined to work with the office to establish a payment plan or has discontinued making payments that had been agreed on previously.

The termination of a dentist-patient relationship is justified when:

- Both parties agree to end it (such as when the patient's medical scheme changes and the dentist is not a member of the plan or when the patient moves out of town).
- When a course of treatment is completed and the patient is made aware that the treatment has been completed.
- When the patient decides to terminate the relationship unilaterally, typically over either unhappiness with the results of the treatment or over administrative, management or personality conflicts.

Exceptions and special circumstances

A number of situations may require additional steps or a delay before ending the patient relationship. Examples include the following situations:

- If the patient is in an acute phase of treatment, delay ending the relationship until the acute phase has passed. For example, if the patient is in the immediate postoperative stage, it is not advisable to terminate the relationship.
- If the provider is the only source of dental care within a reasonable driving distance, care may need to continue until other arrangements can be made.
- When the provider is the only source of specialised medical dental care, treatment may need to continue until the patient can be safely transferred to another provider who is able to provide appropriate care and follow-up.

Patients should be given some indication of the financial requirements when they make an appointment for treatment to prevent them from delaying making other arrangements for care while waiting for an appointment at which they will receive no treatment. While it has not been clearly established that making an appointment creates a dentist-patient relationship, it would be difficult to explain why someone in urgent need of care or pain was turned away after having waited for an appointment.

Abandonment of patients

One of the biggest areas of concern when a dentist decides to terminate a patient relationship is abandonment.

A patient is abandoned when a doctor ceases treatment before the patient has recovered or has terminated his or her contract with the doctor, and the doctor does not refer the patient to another practitioner or institution that can continue such treatment.

A doctor who abandons a patient without referral to another doctor or arranging for their further treatment will be liable for damages. Therefore, if a doctor undertakes treatment for a patient, such treatment may not be abandoned if it would harm the patient – unless the patient makes it impossible for the doctor to treat him or her. For example, an inability to pay may make it impossible for a doctor to prescribe a treatment regimen. The treatment may be terminated, but the patient should then be referred to a public health facility or another practitioner for treatment.

Doctors who deal with patients' medical schemes and refuse to treat patients who cannot afford to pay for treatment in advance will escape liability for abandonment if they refer such patients to a public health facility or a colleague prepared to treat them at medical scheme rates.

Abandonment may occur when a dentist refuses to complete a patient's treatment for no justified reason or when a dentist refuses to see a patient for a follow-up visit.

If the patient chooses not to return to the office for the remainder of their treatment, be sure to inform the patient of any currently diagnosed oral condition, as well as any treatment recommendations and risks of not seeking further care.

How to terminate the relationship

Any dentist contemplating the termination of a dentist-patient relationship should notify the patient of the dentist's intention to terminate the relationship.

The dentist should provide a specific timeframe, often defined by state law, during which the patient should seek a new dentist, such as 30 days.

This timeframe may vary depending on whether the dentist is a generalist or specialist, as well as on the availability of other practitioners in the area. During this timeframe, the dentist should be available for emergency care.

A dentist is not required to make a specific recommendation to a subsequent treatment provider. The dentist is only responsible for helping the patient find a subsequent provider if the patient requests it. The dentist should inform the patient that copies of his or her records are available to them or will be forwarded to a subsequent treatment practitioner.

Document any concerns that may suggest a breakdown in the dentist-patient relationship, as well as any efforts made to save this relationship in the patient's records. As with all recordkeeping, documentation should be timely and accurate.

Review outstanding balances. You can discuss any financial balances the patient may still owe, or you may waive the patient's outstanding fees as a gesture of goodwill. Each situation is unique, and your decision will depend on a number of factors such as the success of the treatment provided, the financial situation of the patient, the underlying reason for dismissal and the patient's history with the practice.

Elements of the written notice

Include the following information in the written notice:

Reason: Although stating a specific reason for ending the relationship is not required, it is acceptable to use the catchall phrase "inability to achieve or maintain rapport", state that "the therapeutic provider-patient relationship no longer exists" or assert

that “the trust necessary to support the relationship no longer exists”. If the reason for ending the relationship is patient noncompliance/nonadherence, that may be stated as well, along with your attempts to obtain patient compliance.

Effective date: The effective date for ending the relationship should provide the patient with a reasonable amount of time to establish a relationship with another practitioner. Although 30 days from the date of the written notice is usually considered adequate, review each case.

The relationship may be ended immediately under the following circumstances:

- The patient has ended the relationship. (Acknowledge this in writing with a letter from the practice.)
- The patient or a family member has threatened the provider or staff with violence or has exhibited threatening behaviour. Practitioners are legally obliged to provide a safe working environment for their employees.
- The patient participates in drug diversion, theft or other criminal activity involving the practice.
- The patient exhibits inappropriate behaviour or sexual misconduct toward the provider or staff.

Interim care provisions: Offer interim emergency care prior to the effective date.

Continued care provisions: Offer referral suggestions for continued care.

Patient records: Offer to provide a copy of the office record to the new practitioner or the patient.

Transition of care: Indicate willingness to speak with the patient’s new provider if requested to help ensure a smooth transition.

Patient responsibility: Specify that the patient is personally responsible for all follow-up and for continued dental care.

Medication refills: Explain that medications will be provided or prescribed only up to the effective date that the relationship ends.

Draft patient termination letters

Dear Patient,

While it has been a pleasure treating you over the past few months/years, it has come to my attention that your account with our practice is in arrears. The current balance on your account is R_____. We have previously notified you of the outstanding amount but without resolution.*

Unfortunately, we must terminate our dentist-patient relationship with you due to the lack of compliance with our practice’s stated financial protocols. Of the items on your original treatment plan, we have completed the following _____.

You still require _____.

Failure to promptly seek examination and care from your next dentist could result in _____.

Sincerely,
Dentist’s Signature

Date
Patient Name
Street Address
City, Code

Dear (insert patient’s first name),

We have contacted you on several occasions with monthly statements, telephone messages and a personal letter concerning your outstanding balance with our practice.

We have determined that due to your noncompliance with our practice’s financial policy we must terminate our dentist-patient relationship.

In order to allow you adequate time to find another dentist, we will be available for the next 30 days for emergency treatment only. If you need assistance in finding another dentist, you may contact _____ at: _____ or utilise other resources (eg the internet).

We will forward a copy of your dental records to you or your new dentist upon receiving a signed written authorisation request. Please clearly indicate whom you wish to receive a copy and where you wish us to send the records. Please allow five business days from receipt of your request for duplication and mailing.

Sincerely,
Dentist’s Signature

[Date]
[Insert Patient Name]
[Insert Patient Address]
[Insert Patient City, Province, Code]

Dear (Patient):

Thank you for selecting (dental group) as your dental care provider. It has become apparent because of a breakdown in our doctor-patient relationship, which is necessary for optimal care, your dental needs would be better met elsewhere.

This letter is to inform you that as of the date of this letter, I (we) will no longer be able to provide you with your dental care and treatment. Should an emergency arise within the next 30 days, I(we) will be available to you during our regular office hours.

Dental conditions tend to worsen with time if they are not addressed. Therefore, I recommend you seek another dental care provider as soon as possible.

My office will be happy to forward your records to you or your new dental care provider upon receipt of a written release. Your new provider can help you with this release. I appreciate the opportunity to have been of service to you as your dental care provider and wish you the best of luck moving forward.

Sincerely,
[Doctor’s Signature]

Dear Patient

It has become apparent to me that our professional relationship has deteriorated over the past several {weeks/months}. A healthy dentist-patient association is based on mutual trust, respect and understanding, which are lacking between us. Without assessing blame to you, my team or me, it seems now is the appropriate time to end our relationship.

You should know several things about your oral condition. There presently is no dental work pending. If you have an emergency situation within the next 30 days, please contact us and we will do our best to accommodate you. Thereafter, we ask that you seek all dental treatment elsewhere.

You also should select a new dentist soon. If you or your new dentist require copies of your dental records, please send us a written release and we will be happy to forward them to the appropriate person.

My team and I regret that this situation had to occur. We wish you good health in the future.

*Very truly yours,
{Dentist Name}*

After patient termination

Avoid any further contact. The office staff of a dental practice should be fully aware that a particular dentist-patient relationship has been terminated. Office staff must be aware that an appointment should not be scheduled for a particular patient after the specified termination date.

Where patients have exhibited or threatened violence, office personnel should develop protocols to manage unexpected patient visits, especially if there is a potential safety risk. Once the timeline for emergency care has ended, and the patient is fully dismissed from the office, the dentist is under no obligation to accept the patient back into the office for future care.

In addition, if a potential subsequent treatment dentist contacts a dental office in order to ascertain the reason behind the patient seeking a new dentist, office staff must be trained how to properly handle the discussion.

No member of the dental staff should malign the patient; a member of the office staff, preferably the office manager or the treating dentist, should merely state that there were administrative differences on which the treating dentist and the patient could not agree.

Once a patient has been dismissed from a practice, the patient should not be accepted back to the practice.

It is important to appreciate that when you are attempting to terminate the doctor/patient relationship, it may not be prudent to place a financial stumbling block such as a records duplication fee in the patient's way. This is particularly prudent when the doctor is attempting to unilaterally terminate the relationship. Also, while the patient may reticently accept being dismissed from your practice because of his/her actions or inactions, attempting to collect a fee for record duplication may be sufficient impetus for him/her to consider retaliatory litigation for any perceived wrong that, up to this point, was not that important.

This brings us to a tangential factor relating to what should and should not be done when a potential subsequent treating practitioner contacts your office to find out the reason(s) behind the patient seeking a new doctor. Neither you nor your staff should bad-mouth the patient regarding such matters as his/her financial status with your office, his/her behaviour while a patient, his/her level of cooperation, etc. In other words, you don't want to say negative things about the patient, even if truthful, because these facts might, in and of themselves, interfere with the formation of a new substitute doctor/patient relationship. Prudent risk management dictates that you merely state that there were administrative differences to which you and the patient could not agree on, sans the details.

Unfortunately, not all dismissals go as smoothly as we hope. Should there be a complaint with the regulator or legal proceedings, seek advice from your professional indemnity provider.

CONCLUSION

Dentists have an ethical obligation to care for patients, but are permitted to terminate the difficult dentist-patient relationship, provided an alternative is available. There is no duty incumbent on dentists to treat people who are not their patients, except in medical emergencies.

CPD questionnaire on page 120

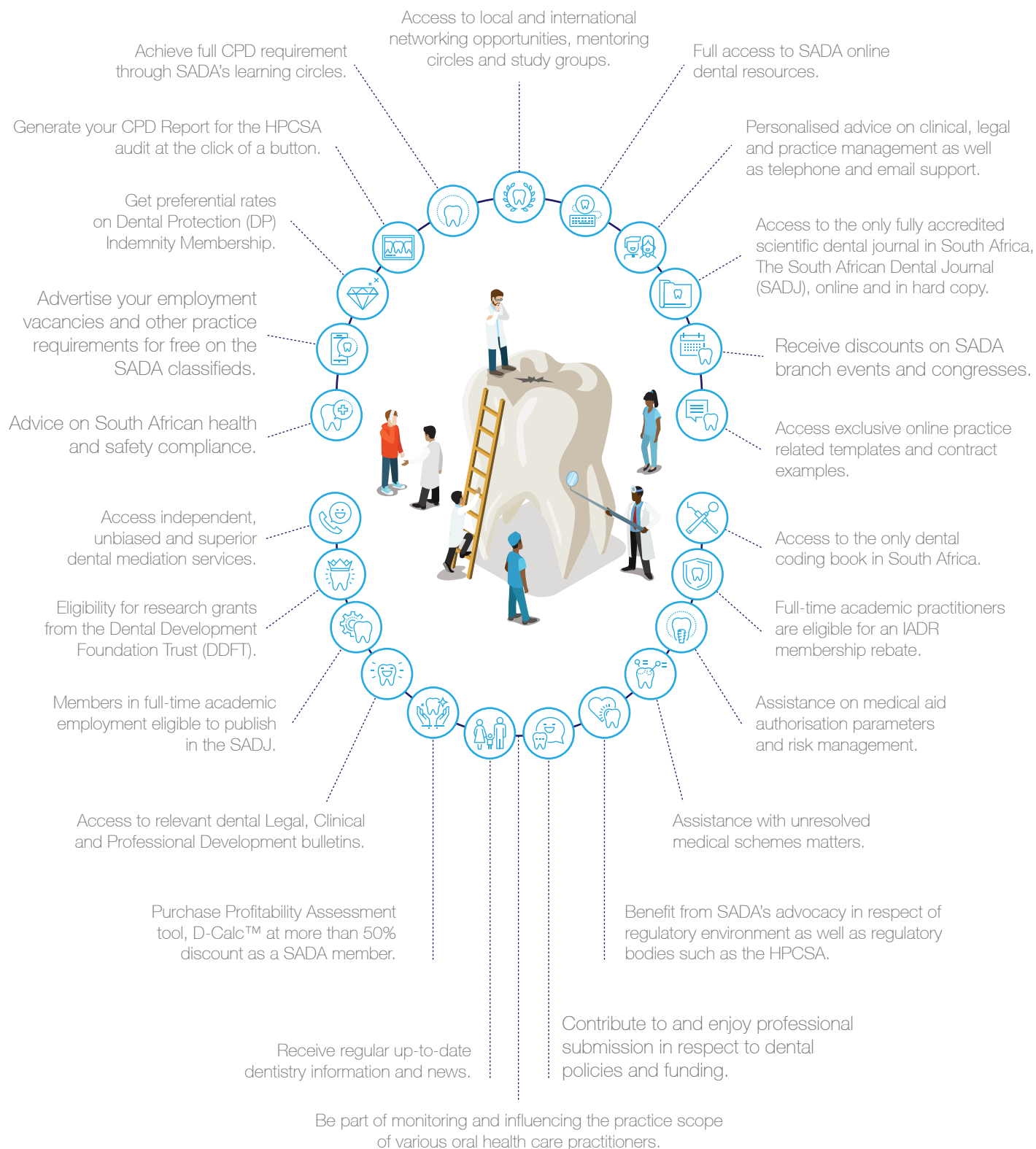
The Continuing Professional Development (CPD) section provides for twenty general questions and five ethics questions. The section provides members with a valuable source of CPD points whilst also achieving the objective of CPD, to assure continuing education. The importance of continuing professional development should not be underestimated, it is a career-long obligation for practicing professionals.



BENEFITS OF JOINING SADA

SADA supports its members throughout their time in the profession - from young students in the field, through their professional careers, and into retirement.

Our members benefit from the below advantages, amongst others:



MAXILLOFACIAL RADIOLOGY

Double type III dens invaginatus

SADJ March 2024, Vol. 79 No.1 p118-119

J Simpson¹, L Janse van Rensburg²

CASE

A 75-year-old female presented for a follow-up appointment for the construction of an implant-retained prosthetic nose. During the appointment, a prosthetic pin unintentionally dislodged into her nasopharynx. The following serial radiographs (Fig 1-3) were taken to determine the location of the pin, with a main concern of dislodgement into the patient's lungs.

In Fig 3, the pin (black arrow) can be seen in the colon. This is an indication that the pin was not aspirated but ingested, implying that no further medical intervention was necessary.

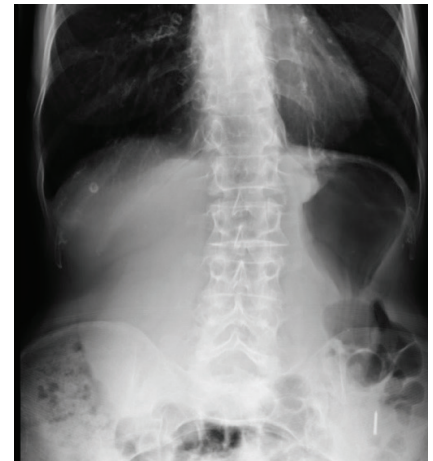
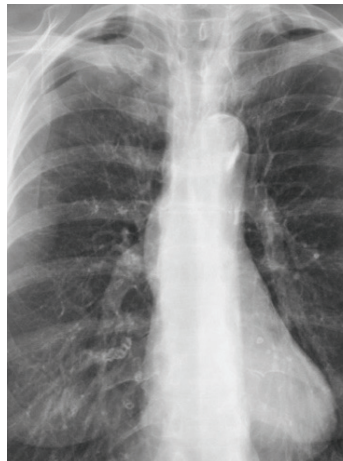
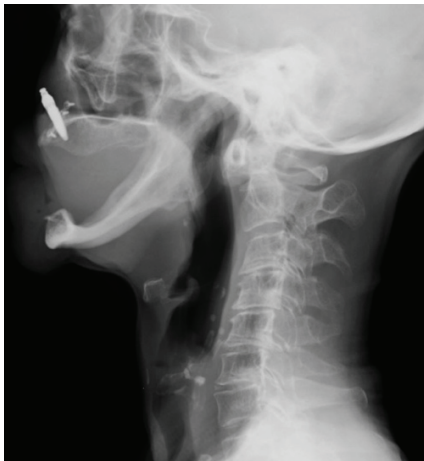
Figure 1: Lateral C-spine radiograph

Figure 2: Posteroanterior chest radiograph

Figure 3: Posteroanterior abdominal radiograph

INTERPRETATION

Foreign body ingestion is often seen in children, the elderly, alcoholic individuals, or the mentally impaired, and may intentionally occur in psychiatric patients and prisoners.¹ Dentures and small orthodontic appliances are the most common objects to be accidentally ingested in adults.¹

In the gastrointestinal tract (GIT), many ingested objects will pass within a few days to a month without any intervention, with a small amount requiring non-surgical or surgical intervention.² In general, objects less than 60mm in length and 25mm in diameter have a 90% chance of passing through the pylorus and the ileocecal valve.³ Sharper objects are unlikely to pass through the curvatures of the intestine and may often result in intestinal puncture,

oesophageal perforation, or haemorrhage, all of which can be fatal.⁴

Dental practitioners must be able to recognise the signs and symptoms of air and gastric obstruction if a dental object was ingested. The need for proper patient communication if this problem were to occur is crucial. If the patient isn't showing any signs of gagging, coughing, choking, dysphagia, abdominal pain, wheezing, stridor or chest pain, the oral cavity must be thoroughly examined for the foreign object.⁵ Once it is clear the object has passed the oropharynx, a radiographic examination should be performed to determine if the object has entered the GIT or respiratory tract. Posteroanterior and lateral chest radiographs, as well as abdominal radiographs, are recommended for the detection of a foreign object.^{2,4} For radiolucent objects, additional diagnostic aids such as computed tomography (CT), magnetic resonance imaging (MRI), endoscopy and diagnostic bronchoscopy may aid in detecting their anatomic location.²

As soon as a patient starts showing signs of a compromised airway and cannot dislodge the object by forcibly coughing, the Heimlich manoeuvre should be performed to dislodge the laryngeal obstruction.⁵ If abdominal thrusts are ineffective in dislodging the object, basic emergency life support should be carried out until proper medical intervention is attained.³

Authors' information

1. J. Simpson: *BDS, PgDip* (Oral and Maxillofacial Radiology). Department of Craniofacial Biology, Pathology & Radiology, Faculty of Dentistry, University of The Western Cape. ORCID: 0009-0009-6757-6577.
2. L. Janse van Rensburg: *MBBCh, MMed(RadD) EDiNR, DSc(Odontology)*. Department of Medical Imaging and Clinical Oncology, Faculty of Medicine and Health Sciences, Stellenbosch University. ORCID: 0000-0003-1549-6785. Author contribution: 30%

Author contributions

- | | |
|--------------------------|-----|
| 1. J. Simpson | 70% |
| 2. L. Janse van Rensburg | 30% |

Objects lodged in the oesophagus usually require surgical intervention and are often removed endoscopically.⁴ However, if there are signs of impaction, perforation, or sepsis, a laparotomy or open surgery may be indicated.¹ If patients ingested blunt objects less than 60mm in length and 25mm in diameter, conservative management is advised. Weekly radiographs are recommended to observe the object passes safely. Failure of the object to pass will result in endoscopic removal or laparoscopy.⁴

Inhalation of a foreign body can be much worse and is regarded as a medical emergency.² Aspiration of foreign bodies tend to be more often trapped in the right bronchial tree; this is due to the right bronchus being more vertical.² Perforation and pneumothorax can occur if the foreign body is sharp or pointed. Signs of pulmonary aspiration could include acute dyspnoea, asphyxia, laryngeal oedema, and cardiac arrest. Recommended treatment is the immediate retrieval of the foreign body by laryngoscopy.

To prevent the inhalation or ingestion of dental objects, dentists should ensure the use of rubberdam during endodontic and restorative procedures. Attachment of dental floss to files is recommended in case they are dropped. Additional preventative measures that could be considered are high vacuum suction, gauze throat packs, customized impression trays, high-viscosity impression material, and placing the patient in a more upright position in the dental chair.³

AUTHORS DECLARATION

Funding

This research did not receive any specific grant from funding agencies in the public, commercial, or not-for-profit sectors.

Conflict of Interest

The authors declare that they have no conflict of interest.

Ethics approval: The University of The Western Cape Ethics Committee has stated that ethics clearance was not required for case reports.

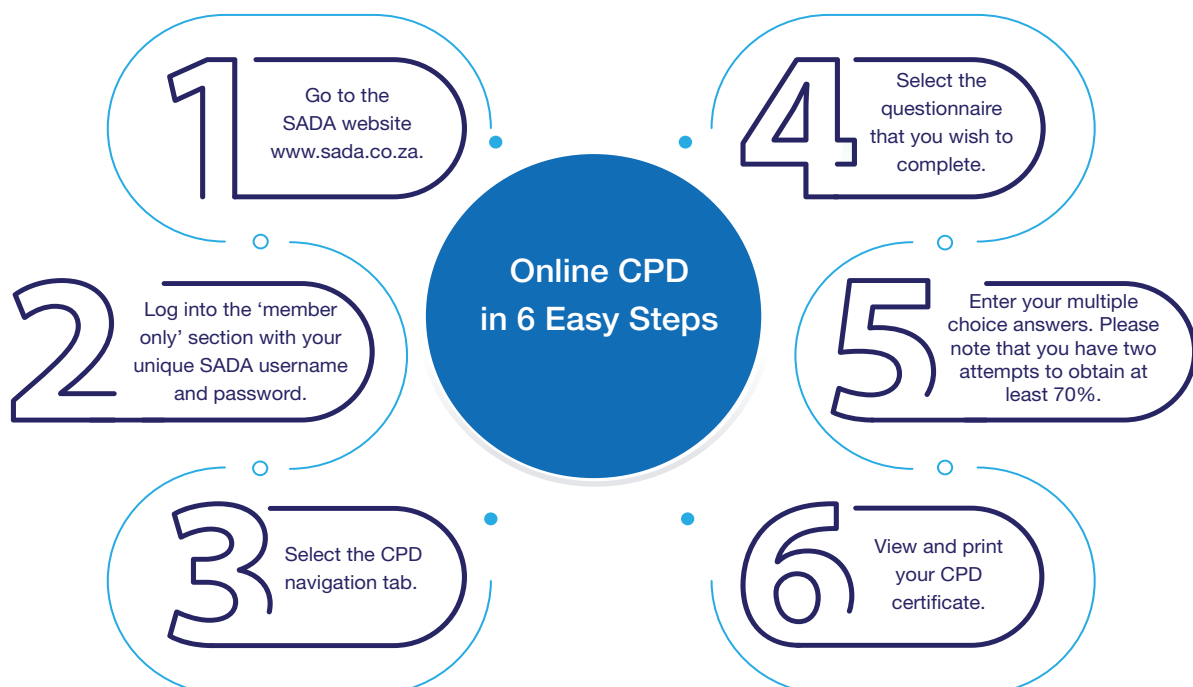REFERENCES

1. Venkataraghavan, K., Anantharaj, A., Praveen, P., Rani, S.P. and Krishnan, B.M. Accidental Ingestion of a Foreign Object: Systematic Review, Recommendations and Report of a Case. *The Saudi Dental Journal* 2011; 23(4):177–81.
2. Saraf, H.P., Nikhade, P.P. and Chandak, M.G. Accidental Ingestion of Endodontic File: A Case Report. *Case Reports in Dentistry*, 2012. <https://doi.org/10.1155/2012/278134>
3. Naderian, A., Baghaie, H. and Satchithanandha, V. Accidental Ingestion of An Endodontic File: A Case Report. *Journal of Medical Case Reports* 2022; 16(1): 1–5. <https://doi.org/10.1186/s13256-022-03363-1>
4. Guefiguat, M., Kaplinskiy, V., Reddy, S. H., and DiPoce, J. Clinical Guidelines for Imaging and Reporting Ingested Foreign Bodies. *American Journal of Roentgenology* 2014; 203(1): 37–53. <https://doi.org/10.2214/AJR.13.12185>
5. Zitzmann, N.U., Elsasser, S., Fried, R. and Marinello, C.P. Foreign Body Ingestion and Aspiration. *Oral Surgery, Oral Medicine, Oral Pathology, Oral Radiology, and Endodontology* 1999; 88(6):657–60.

Online CPD in 6 Easy Steps



The Continuing Professional Development (CPD) section provides for twenty general questions and five ethics questions. The section provides members with a valuable source of CPD points whilst also achieving the objective of CPD, to assure continuing education. The importance of continuing professional development should not be underestimated, it is a career-long obligation for practicing professionals.



CPD questionnaire



Root and canal morphology of the maxillary first molar: a micro-computed tomography-focused observation of literature with illustrative cases: Part 2: Internal root morphology.

1. **Select the CORRECT answer. The discovery of the MB2 canal can be challenging due to:**
 - A. Unclear radiographs
 - B. Close proximity to other canals
 - C. Dentine ledges
 - D. Lack of specialised endodontic instrumentation
2. **Select the CORRECT option. Which of the following has been suggested as the most suitable method to identify and describe fine root canal anatomy:**
 - A. Radiographs
 - B. The clearing and staining technique
 - C. CBCT
 - D. Micro-CT
3. **Which answer is CORRECT. The global incidence of the MB3 canal has been determined as:**
 - A. 3%
 - B. 0.5%
 - C. 5%
 - D. 4%

Dental patients' knowledge, attitudes, and experiences related to Voluntary Counselling and Testing for HIV in the dental setting in eThekweni district, KwaZulu-Natal.

4. **Choose the CORRECT statement from the information found in this paper:**
 - A. Less than half of the participants reported to have heard of the rapid HIV testing method
 - B. The majority of the participants indicated to have heard of the rapid HIV testing method
 - C. Almost all participants were unsure regarding their knowledge on the rapid HIV testing method
 - D. All participants reported to have heard of the rapid HIV testing method
5. **Based on this paper, choose the CORRECT statement:**
 - A. The majority of participants reported not to want to test for HIV in the dental workplace because of fear and rejection by the dentist following a positive result.
 - B. The majority of participants reported not to want to test for HIV in the dental workplace because of fear and stigmatization following a positive result.
 - C. The majority of participants indicated to not to want to test for HIV in the dental workplace because they did not trust the oral healthcare worker to keep the results of the HIV test confidential.
 - D. The majority of the participants reported to want to test for HIV in the dental workplace because it was convenient and meant that they could seek medical attention sooner.
6. **Which of the following statements is CORRECT based on the text in the article:**
 - A. The majority of participants visited the dental workplace less than twice a year
 - B. The majority of the participants visited the dentist more than 5 times a year
 - C. Almost all participants reported to visit the dentist twice a year
 - D. Very few participants indicated to visit the dentist once a year

A simplified and evidence-informed approach to designing removable partial dentures. Part 5. Design examples for Kennedy classifications.

7. **Select the CORRECT answer. When communicating with the dental technician it best to:**
 - A. Phone through a design
 - B. Send a prescription as written or drawn or both
 - C. Inform the technician of the material only
 - D. Ask the technician to design the denture
 8. **Select the CORRECT option. What is the main design feature that a Kennedy Class I denture would have that would not be necessary in a Kennedy Class III design?**
 - A. Rest seats on either side of the saddle
 - B. More than one clasp on each side
 - C. Indirect retention
 - D. None of the above
 9. **Which answer is CORRECT. How far from the gingival margins must a lingual bar be?**
 - A. 4 mm
 - B. 6 mm
 - C. At least 2 mm
 - D. Depends on the sulcus
 10. **Choose the CORRECT answer. What is the minimum distance from the lingual functional sulcus to the gingival margins to be able to prescribe a lingual bar?**
 - A. 4 mm
 - B. 5 mm
 - C. 6 mm
 - D. 8 mm
 11. **Select the CORRECT statement. A maxillary Class IV denture should have clasp that that engage:**
 - A. The distal undercuts of the last molars on each side
 - B. The mesial undercuts of the last molar that can also receive a rest
 - C. It does not matter as long as there is a clasp on each side
 - D. None of the above
- Oral health in children and adolescents with special healthcare needs in South Africa: A narrative review**
12. **Select the CORRECT option. Children with special health care needs (CWSHCN) comprise of children and youth with or at risk of**
 - A. Physical
 - B. Developmental
 - C. Behavioural
 - D. Emotional
 - E.. All the above
 13. **Choose the CORRECT answer. The most common type of disability reported in South African children**
 - A. Intellectual disability
 - B. Cerebral palsy
 - C. Autism spectrum disorder
 - D. Hearing impairment

14. Which of the following is CORRECT. Risk factors that may contribute to poor oral health in CWSHCN include A.
Poor dietary choices and between meal consumption of sugars
B. Inadequate oral hygiene
C. Enamel hypoplasia
D. Chronic medications
E. All the above
15. Select the CORRECT statement. Access to dental care for CWSHCN may be related to
A. Child's special need/disability
B. Family socio-economic status
C. Environmental factors
D. All the above

Radiology corner

16. Which option is CORRECT. What are the important signs and symptoms of air and gastric obstruction if a dental object were to get lost in the oropharynx?
A. Blurred vision, fatigue, hunger, and tingling in the feet
B. Abdominal pain, headaches, blurred vision, and chest pain
C. Wheezing, nausea, vomiting, a skin rash, and nasal congestion
D. Gagging, coughing, choking, dysphagia, abdominal pain, wheezing, stridor, or chest pain
17. Select the CORRECT answer. Which radiographs are recommended for the detection of a radiopaque foreign object?
A. Posteroanterior and lateral chest radiographs, as well as abdominal radiographs
B. Abdominal radiographs, CT, and MRI
C. Posteroanterior and lateral chest radiographs and lateral C-spine radiographs
D. Posteroanterior chest radiograph and lateral C-spine radiograph
18. Choose the CORRECT answer. In the Karaduran et al study on AD, which of the following statements best describes the finding when comparing the ages of Alzheimer's patients according to the stages:
A. There was a significant difference between Stage I and Stage II groups
B. There was no significant difference between Stage I and Stage II groups,
C. There was a significant difference between Stage I and Stage III groups
D. There was no significant difference between Stage I and Stage III groups
19. Which option is CORRECT. In the Karaduran et al study on AD, Correlation analysis showed that:
A. Age was positively correlated with BOP% only
B. Age was positively correlated with CAL only
C. Age was positively correlated with BOP% and CAL
D. Age was positively correlated with SMMT0, SMMT1, and number of teeth
20. Choose the CORRECT option. In the Lindfors et al study, the Kappa value found diagnosing periapical radiolucency, comparing IO and CBCT was:
A. 0.21
B. 0.51
C. 0.76
D. 97.7 %
- Ethics. Terminating dentist-patient relationships: balancing ethics and practical considerations**
21. Dentists Autonomy. Select the CORRECT statement. According to the article, what is the dentist's autonomy in deciding whether to accept or terminate a dentist-patient relationship?
A. Dentists must accept every patient who seeks their services.
B. Dentists have the autonomy to reject patients but based on good grounds permitted by law.
C. Dentists are required to terminate relationships based on financial constraints.
D. Dentists can terminate relationships only in emergency cases.
22. Workplace Safety. Which of the following is CORRECT. What obligation does the National Health Act, 2003 impose on practitioner employers concerning the treatment of patients with a history of violent and abusive behaviours?
A. Employers are obligated to immediately terminate the dentist-patient relationship.
B. Employers must refer such patients to colleagues within the practice.
C. Employers are required to take steps to control the risk posed by such patients.
D. Employers are not responsible for the actions of patients within the practice.
23. Discussing Financial issues with patients. Select the CORRECT option. According to the article, why do some practitioners express discomfort discussing financial issues with patients?
A. Fear of damaging their professional reputation
B. Inability to accurately estimate treatment costs
C. Concerns about patients' unrealistic expectations
D. Resistance to accepting fee reduction requests
24. Written Notice. Which option is NOT CORRECT. According to the article, what is NOT required in the written notice when terminating the dentist-patient relationship?
A. Specific reason for termination
B. Effective date of termination
C. Recommendation to a subsequent provider
D. Interim care provisions
25. Reasons for Patient Dismissal. Select the CORRECT answer. According to the article, what is a justifiable reason for terminating the dentist-patient relationship?
A. Patient dissatisfaction with treatment results
B. Patient's inability to afford immediate payment
C. Patient's refusal to follow treatment plan
D. Patient's disagreement with administrative decisions

What's new for the clinician – summaries of recently published papers

Instructions to authors



Thank you for considering the submission of your work to the Journal for possible publication. We welcome papers which may be Original Research, Clinical Review, Case Reports, Clinical Communications, Letters or Notes.

The South African Dental Journal (SADJ) is a peer reviewed, Open Access Journal, published by the South African Dental Association (SADA). The Journal primarily carries research articles which reflect oral and general health issues in Africa but also publishes papers covering the widest consideration of all health sciences. In addition, items of specific relevance to members of the Association find dissemination through the Journal. The Journal is published ten times each year in electronic format. Hard copy is available by arrangement.

We shall be obliged if your submission is prepared respecting all the details listed in these Instructions. This facilitates our process and ensures more rapid responses to you. Please use and submit the Checklist for Authors supplied on page 645 for confirmation. Thank you.

Submission Enquiries

The Editorial Assistant Mr Dumisani Ngoepe
Email addresses: sadj@sada.co.za/editor@sada.co.za
For submission instructions kindly refer to the "Submission instructions" page.

Language

All articles must be submitted in English. Spelling should be in accord with the Shorter Oxford English Dictionary. All articles must be submitted in English. Spelling should be in accord with the Shorter Oxford English Dictionary.

Clinical Research

Articles should adhere to the protocols of the Helsinki Declaration: (<https://www.wma.net/policies-post/wma-declaration-of-helsinki-ethical-principles-for-medical-research-involving-human-subjects/>).

Clinical Trials

Clinical trials should conform to the Consort Statement (Consolidated Statements of Reporting Trials) and Reviews to the PRISMA checklist (Preferred Reporting Items for Systematic Reviews and Meta Analyses) (<http://www.equator-network.org>).

Authors

Authors should meet the criteria for authorship as in the documents of the International Committee of Medical Journal Editors (ICMJE):

1. Substantial contributions to the conception or design of the work or the acquisition, analysis or interpretation of data for the work, AND
2. Drafting the work or revising it critically for important intellectual content, AND
3. Final approval of the version to be published, AND
4. Agreement to be accountable for all aspects of the work in ensuring that questions related to the accuracy or integrity of any part of the work are appropriately investigated and resolved (www.icmje.org).
5. The front page of the manuscript should list the title of the article, the author's(s) name(s), and their qualification(s),

affiliations and positions held, telephone and fax numbers and address(es), including Email address(es), if available. It is especially important that details of the Corresponding Author should be clearly stated.

6. Please submit on the front page a list of up to eight Keywords.
7. In the case of multiple authors, the role played and the respective contribution made by each should be recorded. For example: "Principal Researcher- 40%, Writing Article- 30%, Tissue Analysis- 20%, Microscopic Examination- 10%", etc.
8. A recent requirement is that authors should be registered with ORCID. This is a number registering you as an Open Researcher and Contributor. Go to the ORCID website home page at <https://orcid.org/> and follow the Three Easy Steps indicated in green. Please submit the ORCID number with your author details.

Title

To be kept as brief, clear and unambiguous as possible.

Abstract

The abstract shall consist of not more than 200 words. For research articles, the summary should be structured under the following headings: Introduction, Aims and Objectives, Design, Methods, Results and Conclusions. Do not include references in the Abstract.

Text

- Articles should be clear and concise.
- Text should be typed in Times New Roman font, size 11; double-spaced with a 3 cm. margin on the sides, top and bottom. Each page must be clearly numbered.
- Please include electronic numbering of lines throughout the document.
- Tables should be clearly identified, using Roman numerals ie. Table I, Table II etc.
- Authors are requested to note and adhere to the current style of the Journal particularly with respect to paragraph settings and headings.

Length of the article

In general, papers should be between 4000 and 5000 words, although this is flexible. The Editor reserves the right to edit the length of an article in conjunction with the author(s) and SADJ reserves the right to charge for excess/additional pages. The first four pages of original research papers published in the SADJ will be free of charge after which a charge of R500 per page or part thereof will be levied.

Illustrations/graphics/photographs

- Illustrations/graphics/photographs must be appropriate to the content of the manuscript.
- Digital images with a DPI of at least 300 should be supplied. Photocopies and pdf. files of photographs are not acceptable.
- **Please note:** Figures should be included in the text and sent separately in jpg. format.
- The Figure numbers must be in Arabic numerals and clearly identified for each illustration, graphic or photograph. Please remember to record Figure numbers in the text.
- **Permission:** Where any text, tables or illustrations are used

from previously published work, permission must first be obtained from the holder of copyright and a copy of the agreement must be submitted with the article. Suitable acknowledgement must be recorded in the article.

Continuing Professional Development

Please supply 4-5 Multiple-choice Questions (MCQ's) with 4 or 5 options per question related to your article. Questions must have only one correct answer, and indicate this correct answer clearly.

References

- References should be set out in the Vancouver style and only approved abbreviations of journal titles should be used (consult the List of Journals Indexed in Index Medicus for these details at: <http://www.nlm.nih.gov/tsd/serials/lji.html>).
- References should be inserted seriatim in the text using superscript numbers and should be listed at the end of the article in numerical order.
- A reference in the text should appear as indicated: "...as the results of a previous study showed.²³"
- Where there are several papers referenced, the superscript numbers would appear as: "...previous studies have shown.^{3,5,7,9-12,14}"
- Do not list the references alphabetically.
- It is the author's responsibility to verify each reference from its original source. Please note that an article may be rejected if the referencing is inaccurate.
- Names and initials of all authors should be given unless there are more than six, in which case the first three names should be given, followed by *et al.*. First and last page numbers should be given. Where it is applicable the page numbers should be abbreviated by omitting redundant numbers eg. pages 456 to 478 is recorded as 456-78, and 456 to 459 as 456-9, but 398 to 401 is recorded as 398-401.
- Notice that volume numbers are not given in bold, authors are not linked by 'and' or '&', and the year of publication appears after the name of the journal. No item should appear in italics except for foreign terms, eg *in vivo*.

Journal references should appear thus:

Smith NC, Haines A. The role of the dentist in public health promotion. *Br Dent J.* 1983; 298: 249-51.

Book references should be set out as follows:

Terblanche N. Principles of Periodontology, 4th ed. London: Butterworth, 1985: 96-101.

Weinstein L, Swartz MN. Pathogenic properties of invading microorganisms. In: Sodeman WA, Smith RT, eds. *Pathologic Physiology: Mechanisms of Disease*. Philadelphia: WB Saunders, 1974: 457-72.

Manuscripts accepted but not yet published may be included as references followed by the words 'in press'.

'Unpublished observations' and 'personal communications' may be cited in the text but not in the reference list.

Declaration

All sources of funding, possible financial interest/s or incentives in products or services mentioned in the article must be disclosed. Authors are kindly requested to read and sign the attached declaration on page 450.



No articles that have been published previously, or that are currently being considered for publication elsewhere, will be accepted. Authors are kindly requested to verify that their article complies with this condition.

Ethics

Where relevant, authors should indicate whether their research has been approved by the Ethics Committee of their Institution or by other research ethics committees.

Conflict of interest

Authors must disclose their involvement with any company either owned by them or from which they have received a grant or remuneration or with which they have an association, and must declare any other personal interest they may have which would constitute a Conflict of Interest. These may include personal relationships, academic competition, or intellectual beliefs. Should there be no applicable Conflicts of Interest this should also be so stated. The statement will be included at the end of the text.

Copyright

The South African Dental Journal is a peer reviewed, Open Access Journal, adhering to the Budapest Open Access Initiative: "By 'open access' to this literature, we mean its free availability on the public internet, permitting any users to read, download, copy, distribute, print, search, or link to the full texts of these articles, crawl them for indexing, pass them as data to software, or use them for any other lawful purpose, without financial, legal, or technical barriers other than those inseparable from gaining access to the internet itself. The only constraint on reproduction and distribution, and the only role for copyright in this domain, should be to give authors control over the integrity of their work and the right to be properly acknowledged and cited."

<https://access.okfn.org/definition/index.html>

The Managing Editor reserves the right to decline articles, photographs or illustrations where products or services are mentioned that are not appropriate.

Submission

The paper should be submitted in one file including all Tables and Figures and their accompanying Legends. Figures should also be submitted separately file in JPEG. format.

Please submit the paper in electronic format in Word along with separate Figures in JPEG. format to: sadj@sada.co.za and to neil.wood@smu.co.za, accompanied by a covering letter and the Declaration on page 450 signed by the author(s).

Galley proofs

No galley proofs will be provided please ensure that all submissions are correct after the review revision submission.

Editorial Policy

Authors may also wish to refer to the Editorial Policy of the SADJ available on the SADA website.

Mr Dumi Ngoepe, Editorial Assistant, at SADA headquarters
on: Tel: +27 (0)11 484 5288
Email: sadj@sada.co.za

Submission Instructions



To submit a new paper to SADJ, do as follows:

1 If this is your first time using this platform, please Register by completing the online form (once off):

Link:

<https://journals.assaf.org.za/index.php/sadj/user/register>

2 Once registered, make sure you are still logged in (Login every time you want to submit a new paper):

Link:

<https://journals.assaf.org.za/index.php/sadj/login>

3 Click on Make a new submission. on the righthand side of the page. Please ensure that the article is anonymized/No names on the submitted article

Make a Submission

4 Familiarize yourself with the Author Guidelines. Then click on **Make a new submission.**

Make a new Submission or view your pending submissions.

5 Follow the 5 steps as part of the wizard, until the last screen. You will receive a confirmation email once successfully submitted, and the Journal Manager/Editor will be notified.

Submit an Article

1. Start

2. Upload Submission

3. Enter Metadata

4. Confirmation

5. Next Steps

If you are struggling on how to load/submit kindly email Dumi Ngoepe at SADA on sadj@sada.co.za for assistance.

NOTE: Incomplete submissions will be returned to the authors and will not be considered for peer-review until complete

Declaration by Author/s

THE SOUTH AFRICAN DENTAL JOURNAL

SADJ



TITLE

.....

AUTHOR/S

.....

I/We, the undersigned confirm and declare that:

- 1** This manuscript is my/our original work and I am/we are the owner/s of this manuscript and possess rights of copyright.
- 2** I/we confirm that this manuscript has not been published previously and it is not currently considered for publication elsewhere. Has this article been submitted to any other journal and if so, has it been rejected?
 YES NO
- 3** For no consideration or royalty, I/we hereby assign, transfer and make over to SADA all the rights of copyright, which have or will come into existence in relation to this manuscript.
- 4** I/we waive in favour of SADA or any successors in title any moral rights which may be vested in me/us.
- 5** The manuscript does not constitute an infringement of any copyright and I/we indemnify SADA against all loss or damage, from any cause arising which SADA may sustain as a result of having been granted copyrights to the manuscript.
- 6** The research has been approved by the Ethics Committee of my/our institution/s or the Ethics Committee/s of other accredited research facilities.
- 7** I/we have disclosed in my/our Acknowledgments all sources of funding, possible financial interest/s or incentives in products or services mentioned in the paper.

..... Initial(s) and Surname Signature Date
..... Initial(s) and Surname Signature Date
..... Initial(s) and Surname Signature Date
..... Initial(s) and Surname Signature Date
..... Initial(s) and Surname Signature Date
..... Initial(s) and Surname Signature Date
..... Initial(s) and Surname Signature Date



Author's Checklist

1

Have you read the Instructions to Authors?
.....

2

Are you submitting electronically?
.....

3

Have you provided all author information including first names, affiliations, qualifications, positions held, Department and Institution, ORCID number, contact details?
.....

4

Is the first author under the age of 35 on submission of the article?
.....

5

Have you provided all details of the Communicating Author?
.....

6

Have you submitted questions for the CPD section? (four or five multiple choice, one correct answer)?
.....

7

Have you submitted details of the contribution of each author... can be percentage or descriptive... or both?
.....

8

Is the first author under the age of 35 on submission of the article?
.....

9

Have you provided all details of the Communicating Author?
.....

10

Have you submitted questions for the CPD section? (four or five multiple choice, one correct answer)?
.....

11

Are the references quoted according to Journal policy, both in the text and in the list of references?
.....

12

Have all authors signed the Letter of Submission?
.....

Recurrent Oral Thrush?

Your patient needs...

VARI MICONAZOLE 2 % m/m ORAL GEL

Indications¹

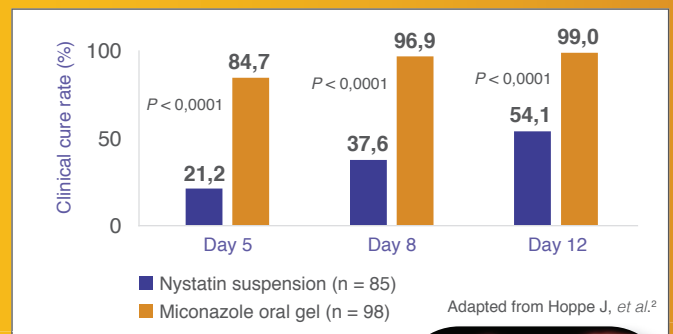
For the treatment of fungal infections of the mouth (oral candidiasis or thrush) and for fungal stomatitis occurring in association with dentures.

Dosage and Directions for Use¹

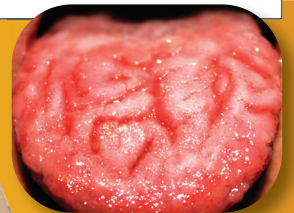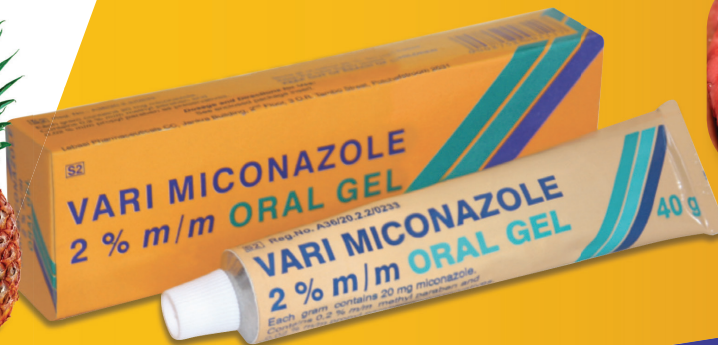- Can be used from the age of 4 months.
- Spread evenly over the affected areas of the oropharyngeal mucosa and tongue.
- Apply four times a day, after meals.
- Continue using for another two days after the infection has cleared.

Proven Efficacy²

Miconazole gel is significantly superior to nystatin suspension with regard to efficacy, rapidity of achieving cure and oropharyngeal yeast eradication.



Pineapple flavour¹



References: 1. VARI MICONAZOLE 2 % m/m ORAL GEL Professional Information (August 2023). 2. Hoppe J, et al. Treatment of oropharyngeal candidiasis in immunocompetent infants: a randomized multicenter study of miconazole gel vs. nystatin suspension. *The Pediatric Infectious Disease Journal* 1997; 16(3):288-293.

REG. No. 36/20.2.2/0233. Each gram contains: 20 mg miconazole.

For full prescribing information refer to the professional information approved by the medicines regulatory authority.

Applicant: Barrs Pharmaceutical Industries (Pty) Ltd, 10 Inyoni Street, Ndabeni 7405.

Marketed and distributed by LeBasi Pharma (Pty) Ltd (Contact number: 087 551 2972), San Domenico Building, Unit G6, 10 Church Street, Durbanville 7551. Company Reg. No. 2020/537601/07.